



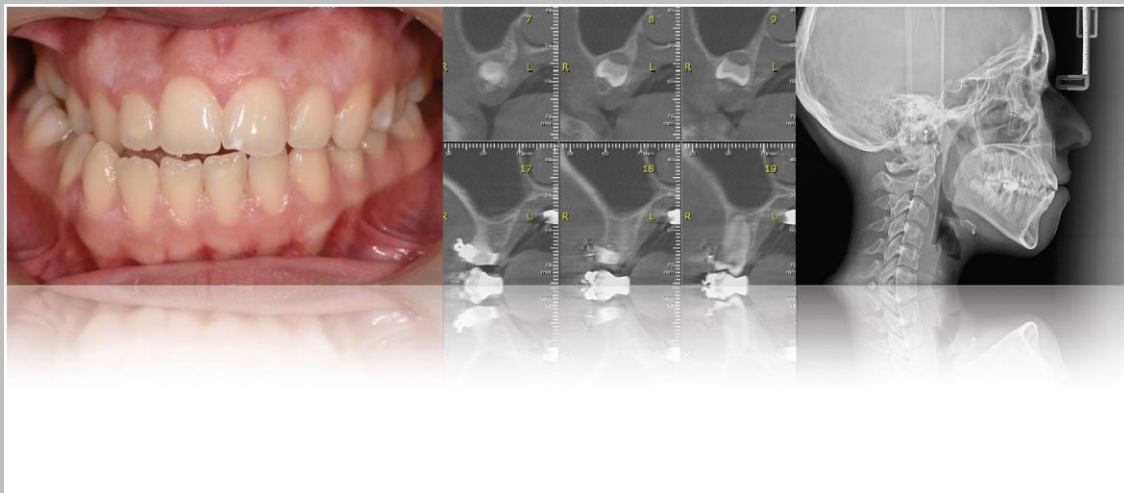
UMFT
Universitatea de
Medicină și Farmacie
„Victor Babeș”
din Timișoara

Camelia Szuhaneck

Eleonora Schiller

Adelina Grigore

Adelina Popa



A GUIDE TO ORTHODONTICS





**LABORATORY GUIDES
COLLECTION**

“VICTOR BABEȘ” UNIVERSITY OF MEDICINE AND PHARMACY TIMIȘOARA
FACULTY OF DENTAL MEDICINE

Camelia Szuhaneck Eleonora Schiller

Adelina Grigore Adelina Popa

A GUIDE TO ORTHODONTICS

**Editura „Victor Babeș”
Timișoara, 2019**



Editura „Victor Babeș”

Piața Eftimie Murgu 2, cam. 316, 300041 Timișoara

Tel./ Fax 0256 495 210

e-mail: evb@umft.ro

www.umft.ro/editura

Director general: Prof. univ. dr. Dan V. Poenaru

Director: Prof. univ. dr. Andrei Motoc

Colecția: GHIDURI ȘI ÎNDRUMĂTOARE DE LABORATOR

Coordonator colecție: Conf. univ. dr. Adrian Vlad

Referent științific: Prof. univ. dr. Elisabeta Bratu

Indicativ CNCSIS: 324

© 2019

Toate drepturile asupra acestei ediții sunt rezervate.

Reproducerea parțială sau integrală a textului, pe orice suport, fără acordul scris al autorilor este interzisă și se va sancționa conform legilor în vigoare.

ISBN 978-606-786-126-6

TABLE OF CONTENTS

PREFACE.....	7
1. PATIENT HISTORY AND THE GENERAL CLINICAL ASSESSMENT.....	8
2. FACIAL AND POSTURAL ASSESSMENTS	11
3. ASSESSMENT OF THE MUSCLES AND OF THE FUNCTIONS OF THE DENTO-MAXILLARY APPARATUS (DMA).....	16
4. EXAMINING THE TEMPOROMANDIBULAR JOINT (TMJ).....	23
5. THE INTRAORAL EXAMINATION.....	24
6. DENTAL IMPRESSION IN ORTHODONTICS	26
7. EXAMINING THE STUDY MODEL	29
Examining the model in the three planes.....	30
Pont's Analysis.....	33
Tanaka and Johnston Analysis	35
Perimetry	36
Bolton Analysis	37
8. CEPHALOMETRIC RADIOGRAPHY	38
9. DIGITAL CEPHALOMETRIC ANALYSIS	64
10. DIAGNOSIS RESULTS.....	69
11. CBCT IMAGING IN ORTHODONTICS.....	71
12. REMOVABLE APPLIANCES	75
13. FUNCTIONAL APPLIANCES.....	85
14. FIXED INTERCEPTION APPLIANCES	96

15. OTHER FIXED APLIANCES USED IN ORTHODONTICS: EXPANSION AND DISTALIZATION APPLIANCES	99
16. EXTRAORAL FUNCTIONAL APPLIANCES.....	101
17. VACUUM-FORMED ORTHODONTIC APPLIANCES.....	102
18. FIXED ORTHODONTIC APPLIANCES	109
19. HANDLING ORTHODONTIC EMERGENCIES IN THE DENTAL OFFICE	114
BIBLIOGRAPHY.....	116
ANNEXES	118

PREFACE

The present guide to orthodontics has been written and thought of as a support for fifth year students at the Faculty of Dental Medicine within Victor Babeş University of Medicine and Pharmacy Timișoara, but it can also be used by the residents in the first year at the Orthodontics and Dentofacial Orthopedics program.

The guide comprises fundamental notions rendered schematically, with the help of data and pictures, which aim at supporting students to easily assimilate the subject studied during medical internship.

The first part of the book discusses notions regarding clinical and paraclinical investigations of the orthodontic patient. Besides standard investigations, notions about digital cephalometric analysis or CBCT investigation are also described.

The second part is devoted to the types of appliances used in intercepting and treating dento-maxillary anomalies. A wider part is devoted to mobile and mobilisable appliances, as well as to the description of the concepts and the way of manufacturing of some types of appliances that are used more frequently in treating dento-maxillary anomalies in children. In what follows, vacuum-formed appliances, as well as fixed dental appliances, together with their components, are briefly described. As the development of fixed orthodontic techniques has been remarkable lately, we believed it was advisable to add some simple manoeuvres that the dentist can carry out in some cases of orthodontic emergency.

We hope that this guide will come in handy for students and young doctors and will help them synthesize the basic principles of orthodontic diagnosis and the main types of appliances used in treating dento-maxillary anomalies.

***The authors
Timișoara, 2019***

1. PATIENT HISTORY AND THE GENERAL CLINICAL ASSESSMENT

Patient history form must contain the following information:

- civil data of the patient
- the environment of origin: urban or rural
- patient's complaint and motivation
- family medical history
- general personal medical history
- dental history

Patient's complaint and motivation can be linked to aesthetic aspects or to functional disorders (breathing, mastication, joint pains).

General medical history

The questions addressed to the mother refer to *personal medical history and to family medical history*:

- if the mother suffers from a chronic disease
- the age she got pregnant at – in elder mothers, the child's tooth eruption is delayed
- if she had pregnancy disorders or other troubles during pregnancy – all the troubles and disorders of the mother during pregnancy affect temporary teeth, as the forming and development of temporary teeth buds takes place during this period
- if the baby was born on time – premature children suffer from delayed tooth eruption and enamel defects
- baby's weight at birth – light weight can be accompanied by delayed tooth eruption and enamel defects
- if nursing was natural or artificial; it is well known that the baby's mandibular moves and tongue position during breastfeeding are beneficial for a harmonious development of the dento-maxillary apparatus
- what disorders the baby suffered since birth until 7 years of age – at this age, the intraosseous formation of permanent teeth is complete, except for the wisdom teeth; all the infectious diseases, vitamin D or iron deficiency, celiac disease (gluten intolerance), endocrine diseases (hypo- or hyperfunctions of the thyroid or of the parathyroids) and other disorders may interfere with the formation and development of permanent teeth (enamel hypoplasia and hypomineralization)
- if family members have suffered from orthodontic problems: crowding /spacing of teeth, skeletal malocclusion

This last question is important, as *heredity* plays a great role. At the level of the stomatognathic system, the following traits are hereditary: tooth and jaw shape and size, tooth structure (enamel), implantation (diastema vera), hypodontia, hyperdontia, maxillary or mandibular prognathism and retrognathism, overbite. Although inherited anomalies represent just 3-10% of the total dento-maxillary anomalies, they must be approached therapeutically as soon as possible, because they affect facial growth and have the greatest potential for relapse after the orthodontic treatment.

We can also talk about *crossed heredity*, when the child inherits the jaws from one parent and the teeth from the other parent, but they are not „compatible” although they have normal shape and size. This leads to dento-maxillary disharmony, usually implying crowding of teeth. [1]

Child's dental history

It is important to find out if the child suffered from delayed eruption or early loss of primary teeth; early loss of primary lateral teeth have the most negative consequences, as it disturbs the permanent teeth eruption pattern [2]

Traumatic injury to the primary dentition can affect the development of permanent teeth, from enamel defects to the impaction or crown / crown and root dilaceration in permanent teeth. The most frequent injuries of primary dentition are intrusion and luxation; they have the most harmful effects over the formation and development of permanent teeth buds.

TMJ (temporomandibular joint) injury in small children can lead to cracks of mandibular collum, which, if not discovered at the right time, will lead to an asymmetric mandibular growth (the mandibular condyle is active until 15 years of age)

Bad oral habits (finger sucking, lower lip sucking or biting skin around fingernails) can have repercussions over dental occlusion.

The mother must be asked if the child has ever had an orthodontic appliance, and if yes, what type and if he used to wear it. If he used to wear it constantly, and went for an activation regularly, what the results were. In the adult patient, we ask if (s)he has ever had a fixed orthodontic appliance, if (s)he used to wear a retainer and for how long.

The general clinical assessment

One must notice the general development of the patient. The weight and height of the child must be correlated with the dental eruption and dental age. *Puberty* is an extremely important period in the development of a child. During this period, a burst of tridimensional growth of the jaws takes place. (the maxillary grows tridimensionally with about 3 mm and the mandible with 8 mm); for some anomalies, such as mandibular retrognathism, this can be beneficial, while for others, such as mandibular prognathism, it can represent a great disadvantage.

Patient's posture is another factor which may indicate a possible orthodontic problem. Multiple studies show that there are some correlations between the posture of one's head and cervical spine and dento-maxillary anomalies [3]; child's posture during sleep can also lead to orthodontic anomalies (hyperextension of the head may lead to mandibular retrognathism, increased flexion due to sleeping on a high-loft pillow may lead to mandibular prognathism).

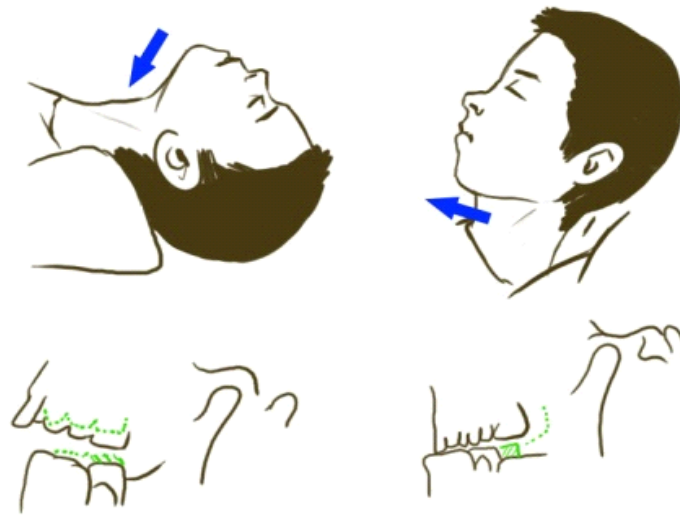


Fig. 1. Patient's posture during sleep can influence the occlusal relationship

Evaluating child's behaviour is another important aspect in orthodontics. Patients' motivation strongly influences the degree of success of the orthodontic treatment.

Patient's approval

Before pursuing extraoral and intraoral examinations, the mother or the patient must sign the agreement for the orthodontic treatment. This is an extremely important forensic document. The patients who show up at the Orthodontics Clinic must sign an agreement to partake of medical training.

2. FACIAL AND POSTURAL ASSESSMENTS

Human face shapes and body types are varied, but not all of them have a pathological significance. It is important to mention that longilin asthenic (dolichocephalic, ectomorph) persons display a tendency for narrow maxillary arch transversally speaking, whose consequences are malocclusion or crowding of teeth.

Constitution types

Sheldon's classification:

- ectomorphic: Tall and thin physique
- mesomorphic: Average physique
- endomorphic: Short and obese physique

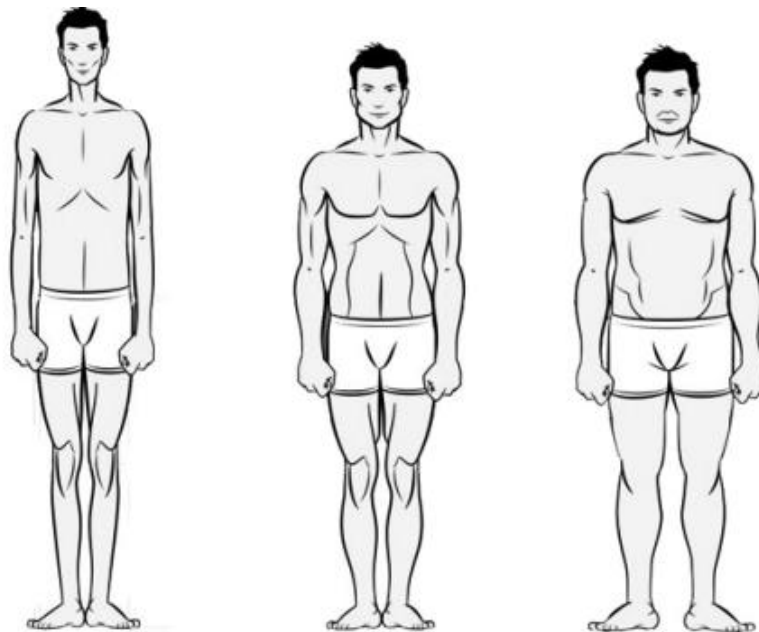


Fig. 1. Constitution types: ectomorphic, mesomorphic, endomorphic (dolichocephalic, mesocephalic, brachycephalic)

Face shapes

Face and skull shapes always match constitution types.

- brachycephalic (brakhys = short) – the development in a transversal manner prevails, the face is of a round shape, the palate is horizontal, the incisors are of a square shape.
- dolichocephalic (long) – the development in a vertical manner prevails, the face is narrow, the arcades are narrow, the palate is deep, they have long crowns and suffer from malocclusion
- mesocephalic – the ratio is maintained

The cephalic index

- is the ratio between the maximum length and the maximum width of the skull
- it can be calculated by using the following formula (fig. 2):

The length of the skull (Gl-Op)x100/the width of the skull (Eu-Eu)

- *Gl - the glabella (the smooth prominence between the eyebrows)
- *Op – the opisthocranium (the posteriormost point in the midsagittal plane of the occiput)
- *Eu – euryon (the point of maximum width of the head at the level of the parietal region)

The value of this ratio indicates the following skull shapes:

- < 75,9 = dolichocephalic
- 76-80,9 = mesocephalic
- >81-85,4 = brachycephalic
- >85,5 = hyperbrachycephalic

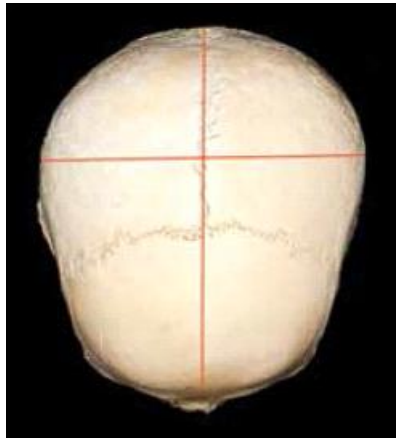

Fig. 2. Calculating the cephalic index

The total facial index

- is calculated by using the following formula:

$$\text{Oph-Gn} \times 100 / \text{Z-Z (the bizygomatic diameter)}$$

- considering the value of this ratio, there are three facial types:
 - >104 leptoprosopic
 - 97-104 mesoprosopic
 - < 97 euryprosopic

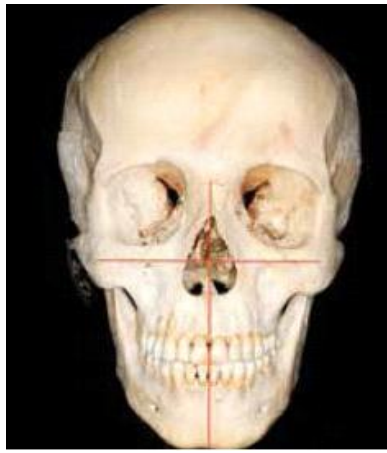


Fig. 3. Calculating the total facial index

Head mobility

The patient is asked to make various head movements (flexion, extension, rotation). These movements allow the evaluation of head and cervical spine mobility. If there are any limitations, the causes must be identified, as neck muscles are highly related to facial muscles.

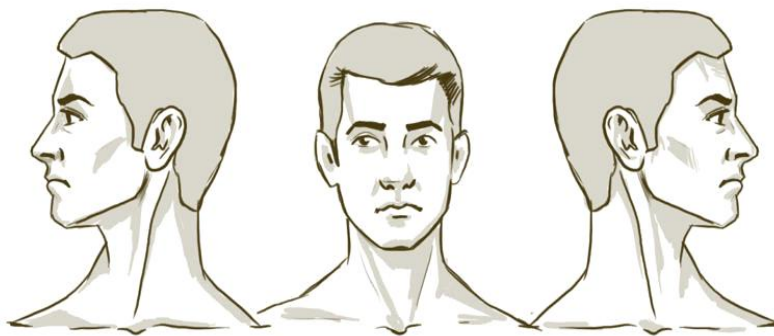


Fig. 4. Assessing head and neck mobility

Facial symmetry

Facial symmetry is assessed by placing the patient in the correct position considering the Frankfort horizontal line and then comparing the left side of the facies with the right side; chin deviation as compared to the median line of the face is the most frequent.

Vertical assessment – the facial thirds

For examination purposes the face is divided into thirds:

- the upper third (Trichion-Ophrion)
- the middle third (Ophrion-Subnasale)
- the lower third (Subnasale-Gnathion)



Fig. 5. Face sections

Assessing the thirds: the middle third is usually 5 to 10 mm smaller than the lower third. If the lower third is increased, this represents an important element in diagnosing vertical dento-maxillary anomalies, an open bite of rachitic origin respectively. If the lower third is decreased, this is a clue for deep overbite [13].

Profile facial view assessment

The profile facial view can offer information about the position of maxillary bone bases in relation to the skull. It can be straight (normal), convex (specific to Class II malocclusion) or concave (specific to Class III malocclusion), thus providing information about dento-maxillary anomalies in the sagittal plane.

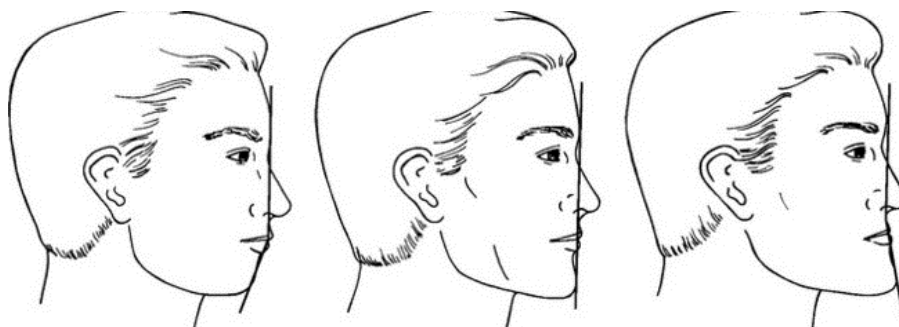


Fig. 6. Types of profile facial view (from left to right): convex, straight and concave

Examining the lips

Thick lips are usually hypotonic, while thin lips are hypertonic; dry and chapped lips are a sign of mouth breathing [13].

The assessment of lips position is made in relation to the profile and it can be:

- retruded (specific to the concave profile)
- normal/straight (specific to the straight profile)
- protruded (specific to the convex profile)

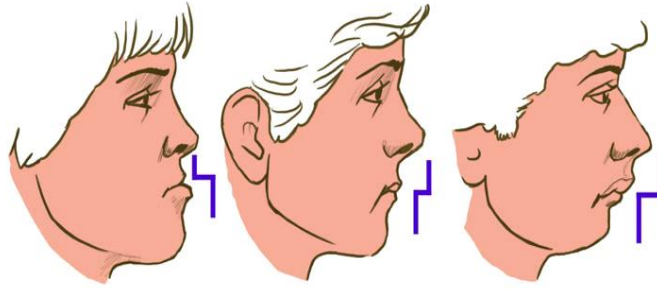


Fig. 7. Assessing lips position

Normally, the lips contact each other during rest position = *lip competence*; if they do not contact each other, it is called *lip incompetency* and it is a sign of mouth breathing.

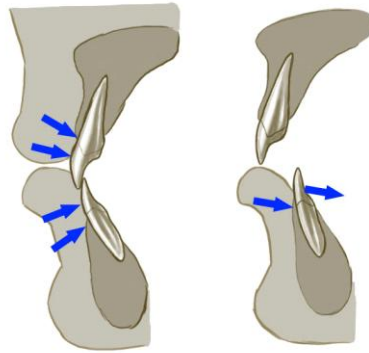


Fig. 8. The influence of lip position over frontal occlusal relationships

3. ASSESSMENT OF THE MUSCLES AND OF THE FUNCTIONS OF THE DENTO-MAXILLARY APPARATUS (DMA)

Assessment of the muscles

Assessing the muscles implies either palpation or testing their tonicity by means of various techniques (hypotonia, normal muscle tone, hypertonia).

Palpation techniques

- pincer palpation - with the help of the index finger and the thumb
- flat palpation – perpendicular to muscle fibers
- palpation by plucking
- triggering palpation – by palpating a muscle, there is the possibility of triggering a local or a radiating pain

Other techniques of assessing muscular tone:

In order to establish the muscle tone, the examiner asks the patient to make a movement which implies the use of the examined muscle. The examiner must oppose to that movement with the help of his/her fingers and (s)he must feel some resistance. This technique is subjective, but it is more accurate than the intraoral palpation of some muscle groups. If the patient offers no resistance, the muscle is considered hypotonic. If the resistance is very high, the muscle is considered hypertonic. All the other situations are considered normal, just as the muscular tone.

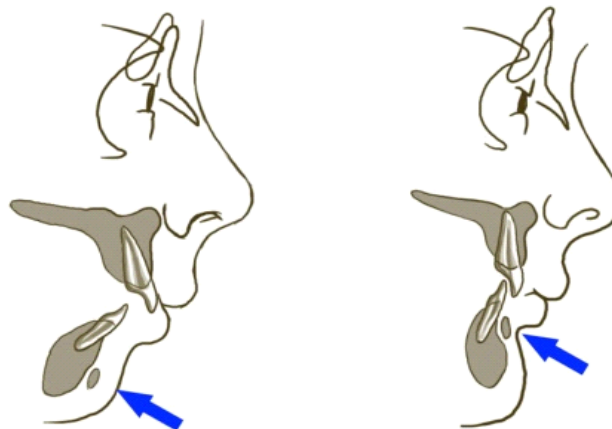


Fig. 1. The importance of the insertion of mentonis muscle in the appearance of some orthodontic anomalies (class II/1 or II/2)

Temporal muscles elevate the mandible and are the most important postural muscles and the most sensitive to occlusal interferences at the same time. They can be palpated externally with both hands at the temple level.

Masseter muscles elevates the mandible and helps mandible propulsion and retropropulsion. External palpation is made from the zygomatic arch and past the goniac angle. Internal palpation is made by inserting one finger in the oral vestibule (M2,M3) in the superior part up to the zygoma. These muscles are sensitive in bruxism.

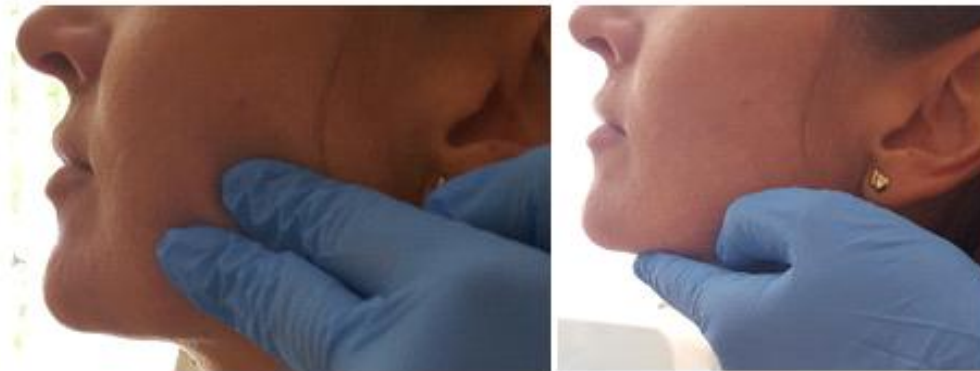

Fig. 2. Extraoral palpation of elevator muscles (flat palpation)

(External) lateral pterygoid muscle

It is the muscle most talked about in specialized literature: some consider it an elevator muscle, some, a depressing muscle or a muscle involved in lateral movements. Palpation is made by inserting one finger in the oral vestibule at the M3 level and by pushing posteriorly and medially behind the tuberosity.

(Internal) medial pterygoid muscle

Together with the masseter, it forms a „strap” for elevating the mandible; it also contributes to laterality and propulsion movements. Extraoral palpation is made anterior to the goniac angle, while intraoral palpation is made posterior to the retromolar trigone (internal part of the mandible).

Tongue muscles, the orbicularis and the buccinator

- tonicity is assessed by opposing the moves which imply these muscles
- the tongue is made up of 17 muscles: 8 paired and 1 single, so its force is considerable. Any disfunctions contribute to a number of malocclusions.
- for the buccinator muscle, the patient is asked to keep the air inside the oral cavity, while the examiner applies some pressure at cheek level (the air must not be let out)
- for the orbicularis muscle, the patient is asked to purse his/her lips, while the examiner pulls both commissures.

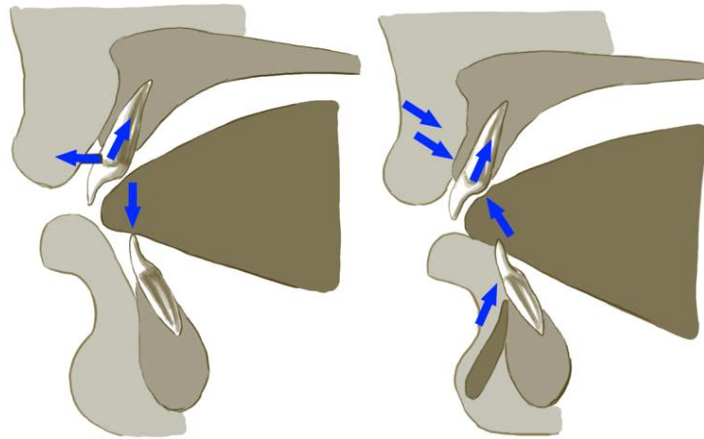


Fig. 3. The influence of lips and tongue muscles on dental occlusion

Alar muscles

- tonicity is assessed during deep inspiration and expiration
- for safety, one can use the mirror test and then evaluate fogged up areas

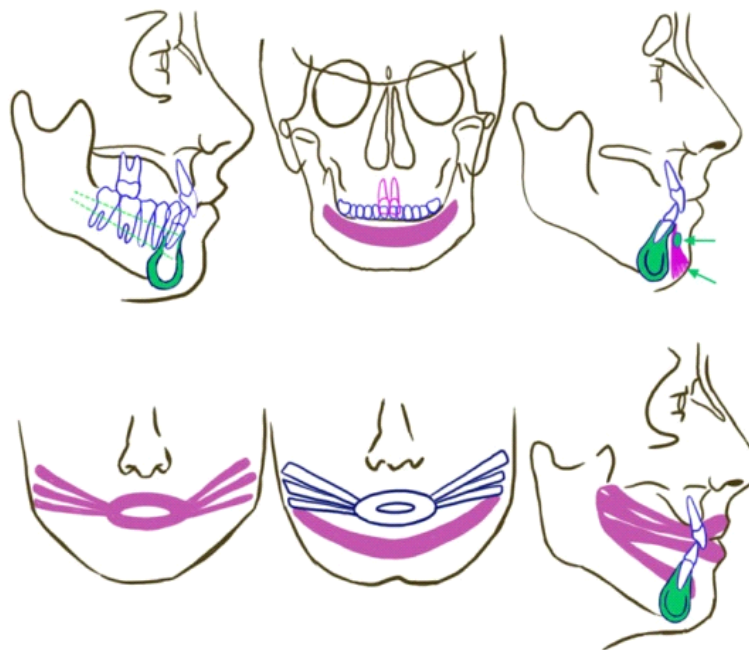


Fig. 4: Orofacial muscles

The functions of dento-maxillary apparatus

Respiratory function

The symmetry and contraction of nasalis muscle are assessed.

By compressing the nostrils and assessing their rapidity of regaining normal shape, one can notice if the patient is a mouth breather; slow shape regain is a sign of mouth breathing.

Certain patients often suffer from asymmetric or flat nostrils, which may be a sign of mouth breathing. In orthodontics, this is called ***mouth breathing syndrome*** and it has the following features: deep palate, upper front teeth protrusion, thin and hypertonic upper lip, mandibular retrognathism, convex profile, that is class II/1 Angle (the American school); in fact, these changes

in the sagittal plane are consequences of the changes in the transverse plane. Reducing nasal breathing leads to sinus and maxillary hypoplasia respectively, and the pressure of face muscles leads to maxillary transverse constriction (narrow maxillary arch – German school). As teeth no longer fit into the arch, they become protruded and the mandible retrudes in order to make stable contact in the posterior part.

- the patient is asked to inhale deeply – if (s)he inhales through the mouth, (s)he is considered a mouth breather
- nostrils compression test – if nostrils regain their shape slowly after compression, the patient is a mouth breather
- mirror test – the patient is asked to exhale through the nose; if the mirror does not fog up (negative test), the patient is a mouth breather
- all patients who suffer from mouth breathing must be redirected to an ENT assessment (in order to remove any rhinopharyngeal obstacles) [4]

Speech

- any speech defects may be a sign of orthodontic anomalies
- the patient is asked to spell dental, labial and sibilant phonemes; the tongue does not normally lean on teeth during pronunciation

Deglutition

Adult's deglutition is produced by placing the tongue in the anterior area of the palate; at birth, deglutition is produced by placing the tongue between the edentulous dental arches. This is considered normal up to 2-3 years of age, and by some authors, up to 7 years of age; if it exceeds 7 years of age, it is considered pathological, it is called *infantile swallowing* and it most often causes open bite.

- a mirror or spatula is placed at the level of the lower lip and the patient is asked to perform swallowing
- patients with infantile swallowing do not display muscular contractions at the level of the temporal muscle; by palpating this muscle during deglutition, one can notice if there is a normal swallowing pattern [2]



Fig. 5. Infantile and adult swallowing patterns (left to right)

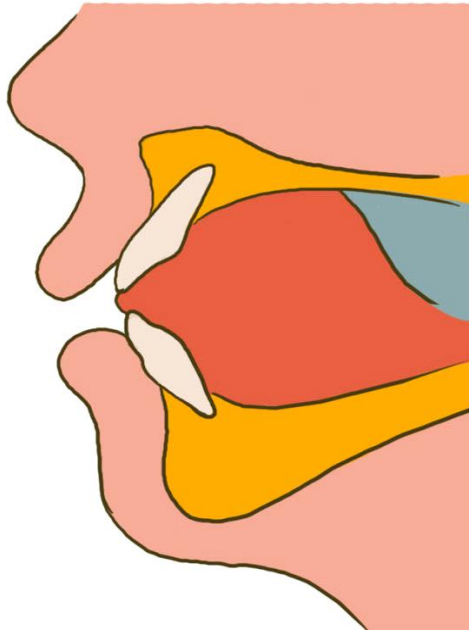


Fig. 6. Infantile swallowing

An infantile swallowing pattern can cause open bite also in the lateral area (lateral open bite).

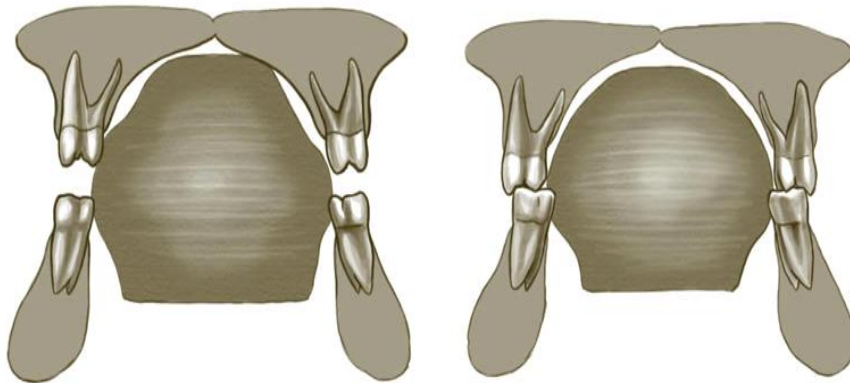


Fig. 7. Tongue interposition in the lateral area

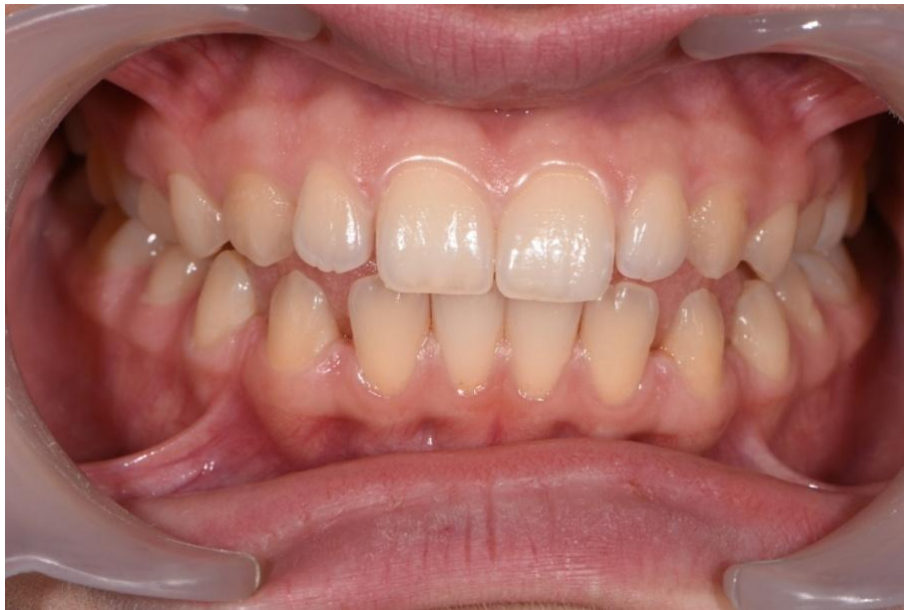

Fig. 8. Open bite (by tongue interposition between dental arches during deglutition)

Mastication

- the patient is asked to chew some gum; the examiner may detect unilateral mastication
- the patients who do not display dental attrition display slower mastication dynamics and prefer soft foods

Facial esthetics

Patients with dento-maxillary anomalies display esthetic changes on both frontal norma and lateral norma: deep occlusion is accompanied by reduced lower third of the face, protruded chin, deep labiomental fold (aged aspect); skeletal open bite is accompanied by increased lower third of the face with a „long face syndrome” aspect; bird-like convex profile (maxillary protrusion or mandibular retrusion), concave profile (mandibular protrusion) with an unaesthetic and aggressive aspect etc.

Notions of occlusiology in orthodontics

The analysis of dental occlusion in its dynamics implies the highlight of premature contacts and of occlusal interferences on the working/non-working side. In order to have a more accurate evidence of the interferences and of the premature contacts, the patient must be guided into centric relation. Recording with the facial arch and mounting the models on the articulator ensure an accurate occlusal analysis and are of a major importance in patients with temporomandibular dysfunction.

Protrusive movement

- from the maximum intercuspation position, the doctor guides the mandible until the incisors get in the edge-to-edge position
- by using articulating paper/occlusion spray, one marks the contacts

- there must be no contact between teeth in the posterior area (if there is the case, one writes down the non-working side interferences in the record) and the guidance must include at least the two upper incisors
- propulsive non-working interferences usually appear on the distal slope of the internal side, at the level of the molars
- propulsive working interferences usually appear at the level of the incisal margin

Lateral movement

- starting from the maximum intercuspation position the doctor guides the mandible into left/right laterality
- one must mention if there is canine guidance or group function (the area involved in the guidance must be mentioned too)
- there must be no contact between teeth at the level of the non-working side (if there is the case, one writes down the non-working side interferences in the record)

The Curve of Spee (in the sagittal plane)

- ideally, the maximum depth of the curve is 3 mm; a deep sagittal curve is a sign of lack of space;
- Von Spee's curve must be convex at the level of the superior dental arch and concave at the level of the mandible

The Curve of Wilson (in the transverse plane)

- it is the curve defined by the inclination of vestibular and lingual cusps at the level of the molars
- this curve allows food to remain at the level of the occlusal table during mastication
- this curve usually has a superior concavity




Fig. 9. Occlusal curves – Von Spee and Wilson (from left to right)

4. EXAMINING THE TEMPOROMANDIBULAR JOINT (TMJ)

One must check the amplitude of mouth opening (it is measured in mm/cm – normal values 40-50 mm).

One palpates the condyles and assesses their symmetry as well as the condyle excursion. The assessment of the condyles is made by inserting the thumb in the external auditory canal and the index finger in the pretragian area; one assesses if the condyle excursion is normal, limited or blocked.

One also assesses if there are deviations at the level of the chin during mouth opening or closing, joint sounds (popping or cracking sounds, crepitus) as well as the moment they can be heard (during mouth opening or closing).

TMJ dysfunctions have multiple causes, but the ones linked to orthodontics are usually distalizations (mandibular retrusion), mezializations (mandibular protrusion) when the condyles are in distal or mezial joint blockage at the level of the glenoid fossa, as well as posterior occlusal interferences.

5. THE INTRAORAL EXAMINATION

Examining the mucous membrane and the periodontium

- examining the frenulum – by mentioning the insertion type (low, medium, high) and its thickness (thin, medium, thick)
 - a thick frenulum with a low insertion may cause diastema
 - a short lingual frenulum causes a low position of the tongue which may lead to mandibular protrusion (due to excessive pressure at the level of the inferior teeth) or speech disorders
- one must mention if there are pathological changes at the level of the oral mucosa (oral manifestations of contagious diseases)
- the colour of the gums: pale pink is the normal colour; if it is pathological, it can be red, which is a sign of plaque induced gingivitis (due to poor hygiene) or of puberty gingivitis, or it can be whitish, which is a sign of anemia
 - the texture of the gums: the normal texture has an orange zest aspect; if it is red and shiny, it is a sign of inflammation
 - the outline of the gums: the normal outline – gum attachment and normal papilla; during inflammation, the outline is uneven and the interdental papilla is detached
 - the degree of hygiene, the presence of dental plaque or of periodontal pockets (in children, these pockets are false, as the gingival proliferation is directed towards the incisor)
 - the presence at gum level of any abscess or fistula (frequent complications in temporary dentition)
- examining the palate – a deep palate is associated with insufficient development of the maxilla in the transverse plane; the presence of a developed torus palatinus denotes a precocious ossification of the medio-palatine suture (the growing center of the maxilla in the transverse plane, which is active up to 21 years of age approximately); in these patients maxillary expansion is difficult to obtain [13].
- examining the tongue by mentioning its dimension (microglossia, normal aspect, macroglossia), its position (low or high), and if the tongue has a candidal aspect or if it is a geographical tongue.

Dental examination

Besides the dental age and early loss of temporary teeth, orthodontics insists on the following aspects:

- number of teeth: hypodontia or hyperdontia
- dental malposition: - twisted teeth (distal or mezial rotations)
- tooth versions (distal version, mesioversion)
- labial, tongue-directed or palatal positioning of teeth
- ectopic eruption
- morphology or size variations – for instance: small lateral incisor, macrodontia of a single tooth, taurodontism, „double teeth” = fusion or gemination

- shape of the arches: in permanent dentition, the ideal is maxillary parable and mandibular ellipse/semiellipse; the pathological shapes are U, V (narrow maxillary), omega-shaped (sign of constriction in the premolar area), trapeze-shaped (upper incisors in straight line), M, W. In temporary dentition, the arches are displayed in a semicircular shape; any divergence from this shape is considered pathological.

Dental aesthetic analysis

Patient's intraoral photos can offer addition information regarding the coincidence of dental midline, the value of the overjet, the height of the gingival zenith, the value of the golden ratio.

Achieving the golden ratio at teeth level is about preserving the 1,68-1-0,68 ratio between the height of the central incisor, the width of the lateral incisor and the mesial half of the canine.

The gingival zenith of the central incisor must be at the same level with the zenith of the canine and 0.5 mm more apical as compared to the zenith of the lateral incisor.

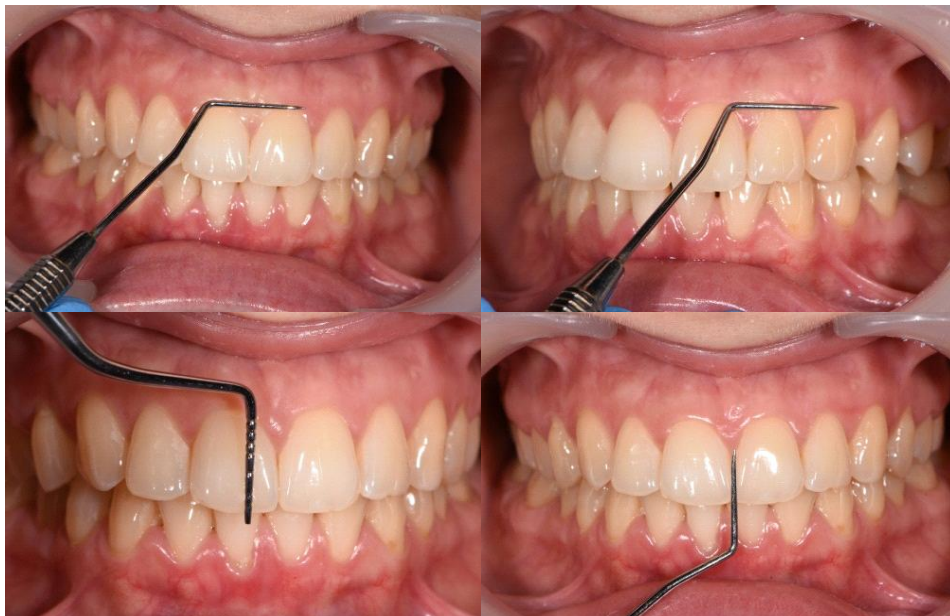


Fig. 1. Dental aesthetic analysis (the height of the gingival zenith, the assessment of the dental midlines)

6. DENTAL IMPRESSION IN ORTHODONTICS

A dental impression allows the execution of the study model and /or of the working model. Based on the study model, one can better examine the palate, any dental malpositions, the occlusion in the three planes, and one can take a number of measurements. These measurements are essential for a correct diagnosis.

Choosing the trays

The trays can either be the stock trays used in dentistry or the special types used in orthodontics (for instance, having the right shape for a protruded narrow maxillary); they must exceed the arch by 0.5 cm buccally and they must be long enough to include the last existing molar on the arch.

The chosen material for the dental impression is *the alginate*. It offers several major advantages:

- it sets quickly (1 minute approximately), which is very useful, mainly when dealing with non-cooperative patients/ children
- new materials are of great fidelity
- it is easy to mix
- there are various types with various flavours available (mint, tropical fruits, etc.)
- it is cheap



Fig. 1. Required materials for a dental impression

Required equipment

- plastic bowl and spatula (plastic/metal)
- water
- alginate and dispenser
- plastic impression trays equipped with retentions

The mixing time is short (45 s - 1 min.) and the setting time may vary depending on water temperature. The water must be warm; if it is too cold (in winter), the material becomes very fluid and it leaks out of the tray; if the water is too hot, the material will set too fast. The errors that may appear are related mainly to the failure in maintaining the proportions between the powder and the water (they must be in an equal amount), to incorrect mixing, to wrong positioning of the impression tray (decentration, extremely posterior or anterior positioning, excessive or insufficient pressure), or to the appearance of air bubbles due to mixing or to saliva [1].

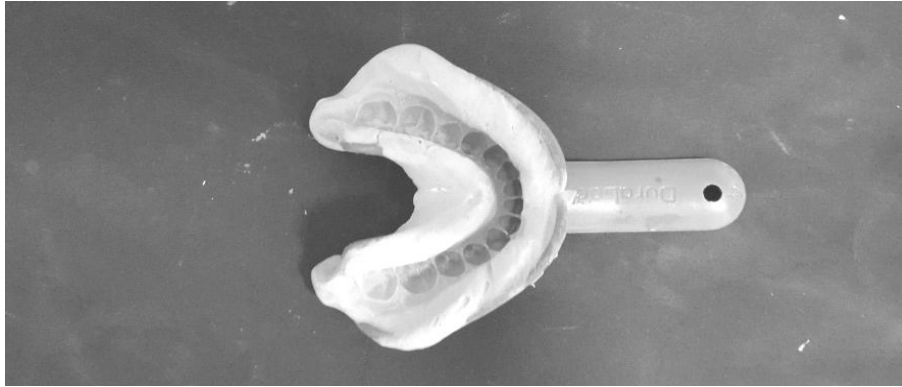


Fig. 2. Alginate dental impression

Patient's and doctor's postures during impression

The patient must be relaxed, having a vertical trunk posture, and (s)he will hold the tray (for the saliva, surplus material, or possible regurgitation - in children).

Before the impression, one must do some exercises using the spoon in the oral cavity, in order to accustom the child to the impression and to breath control.

One must always begin the dental impression with the lower arch so that the patient gets accustomed to it and so as to avoid the appearance of queasiness, as it may be the case for the maxillary. The doctor must stay in front of the patient and must press the tray in the lateral areas of the arches using his index and middle finger. (S)he supports the mandible using the thumbs.

For the upper arch, the doctor must stay in front of the patient and (s)he must insert the material through a commissure (which is pulled using his fingers) using the tray. Then, (s)he exerts some pressure from the posterior part to the anterior one. The patient bends forward a litte bit and the doctor gets behind him, maintaining the tray into place by using his middle finger and his ring finger, and the material that overflows buccaly is put back in the front area of the oral vestibule by using the index fingers.

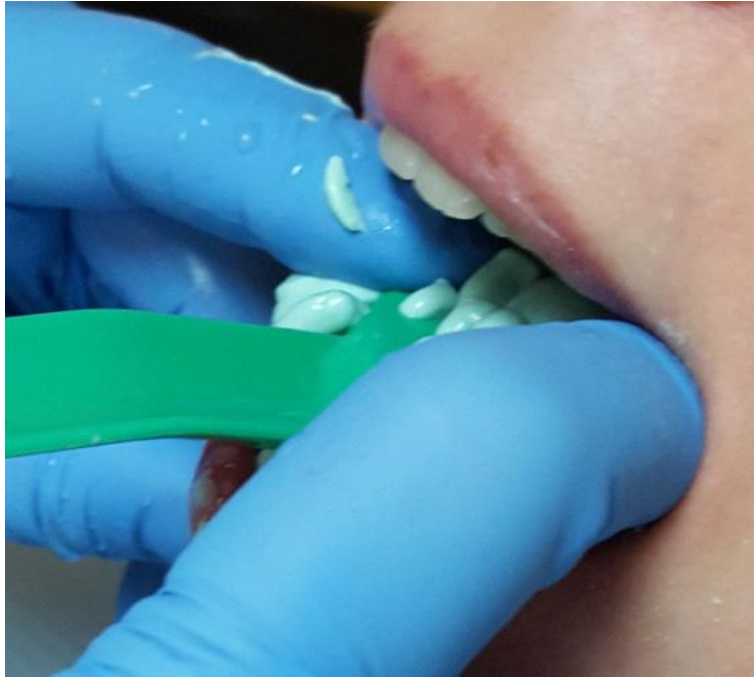

Fig. 3. The impression stage (the mandibular arch)

Requirements for a correct dental impression

A correct impression must render all the important details of the imprinted area [13]:

- whole dental arches
- vestibular depth
- the median raphe and the palatal rugae
- the A-line
- the molar tubercle and the molar trigone
- the lingual frenulum, the labial frenulum and the vestibular flanges

7. EXAMINING THE STUDY MODEL

The study model is made based on the impression. It is made of white, high strength impression plaster (type IV plaster is preferred).



Fig. 4. Pouring/Casting the plaster model

The study model is extremely useful in providing the correct diagnosis. The elements that must be analyzed in order to establish a correct diagnosis are the following:

- the shape of the dental arches
- the shape, the depth and the symmetry of the palate
- the type of the palatal rugae and of the incisive papilla
- the insertion and thickness of the frenulums and of the flanges
- dental malpositions/ hyperdontia/ crowding of teeth/ gaps
- teeth shape (macrodontia/microdontia) – using Bolton analysis
- size of the arches in the transverse plane – using Pont's analysis
- lack of space/ excess of space
- the analysis in the three planes.

The shape of the arches

Ideally, the shape of the maxillary arch is that of a parable and the shape of the mandibular arch is that of an ellipse. In temporary dentition, the shape of the arch is that of a semicircle. In patients with orthodontic anomalies, the shape of the arches no longer follows the normal pattern (figure 3), and they are pathological (U, V, M, trapeze-shaped, omega-shaped, atypical etc.) [6]. If the patient has missing teeth, one must mention that the arch is discontinuous.

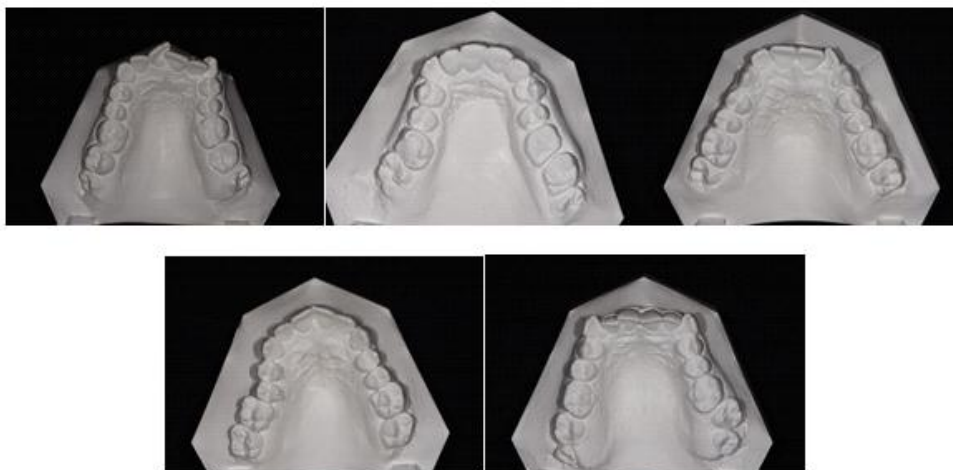


Fig. 5. Pathological shapes of the dental arch: M, omega-shaped, atypical, V, trapeze-shaped.

Examining the model in the three planes

The analysis of the models is made in the three reference planes:

1. *The sagittal plane*

Front area – the value of the space of inoclusion (OJ-overjet)

- normal = 1,5-2 mm
- high > 3 mm = protrusion
- absent = 0 mm = retrusion
- negative = negative overjet




Fig. 6. Increased overjet (OJ)

Cuspid ratio – neutral ratio: the mesial part of the canine coincides with the distal part of the inferior canine; pathological: distalized or mesialized.

Lateral area – the molars – neutral ratio: the mesio-vestibular cusp of the maxillary first molar coincides with the first vestibular groove of the mandibular first molar (fig. 7); pathological: distalized or mesialized.

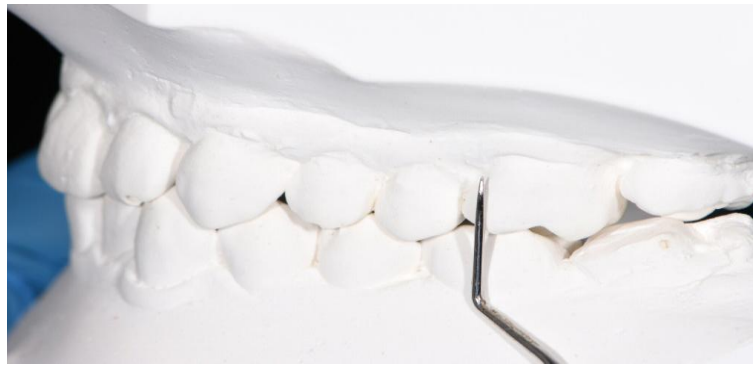

Fig. 7. Neutral ratio at the level of the canine and of the molar

2. The transverse plane

The frontal area

- the dental midlines must coincide with one another and also with the median line of the face
- pathological versions: lateral deviations of the dental midlines may be caused by dental problems (dental malpositions) or by mandibular problems, when they are accompanied by crossbite on the deviant part (functional lateral deviation); when there are anatomical mandibular changes, we talk about laterognathia.

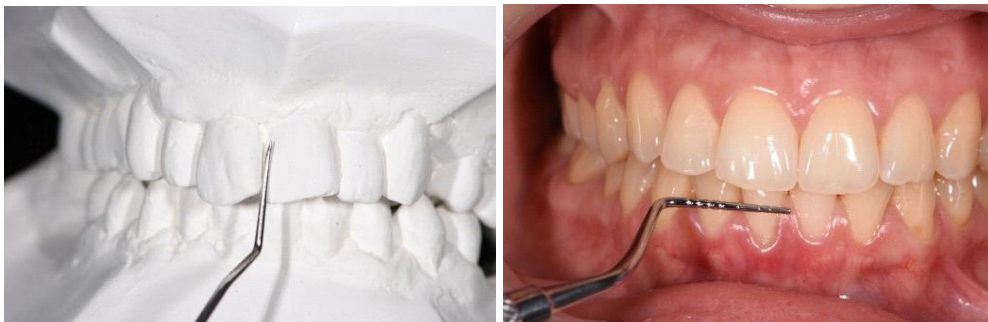


Fig. 8. Lateral deviation of the interincisive line

Lateral area

- the maxillary arch must circumscribe the mandibular arch
- pathological versions:
 - inverted lateral occlusion (crossbite)
 - lingualized occlusion (when the mandibular lateral teeth are in lingual version)

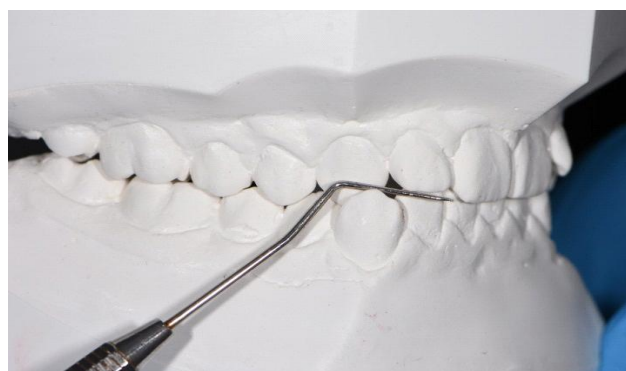

Fig. 9. Crossbite at the level of tooth no. 13 and tooth no. 43

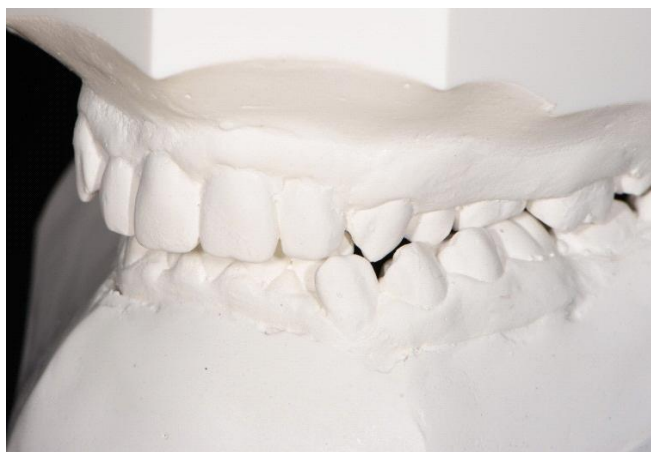

Fig. 10. Crossbite from teeth no. 23 to 26

3. The vertical plane

Frontal area – Overbite (OB)

- the normal value is 1/3
- pathological versions:
 - vertical malocclusion: open bite
 - overlap greater than 1/3 = 2/3 or 1/1 (deep bite)

Lateral area

- each tooth has 2 antagonists, except for the mandibular central incisors and maxillary third molars which only have one antagonist.
- pathological versions: overbite/ open bite

After the analysis of the model in the three planes, one diagnoses the dento-maxillary anomaly. The international classification is the one made by Angle (classification made depending on the changes in the sagittal plane; M1 is the reference point):

Class I – neutroclusion: the occlusion for the M1 is normal, but the other teeth may have problems like: crowding, open bite, proalveoly, etc.

Class II – distocclusion for the M1 and 2 subtypes for the frontal area:

Class II Division 1 - the anterior teeth are protruded

Class II Division 2 – the anterior teeth are retruded

Class III - mesiocclusion for the M1 and anterior negative overjet.

For an accurate diagnosis, after the analysis of the study model in the three planes, one carries out several measurements: Pont's analysis, Bolton analysis, perimetry, Tanaka and Johnston analysis (in the case of mixed dentition), occlusogram etc. These measurements allow the dentist to establish the space deficit and direct us towards possible treatment options. The analysis of the study model must be correlated with the intraoral examination and the cephalometric measurements.

Pont's Analysis

In the orthodontic practice, besides the analysis of the model in the three planes, there are a number of parameters which are used in order to obtain a complete diagnosis and to take the right therapeutical decision. The applicability of Pont's analysis refers to the cases which require transverse expansion. Pont's index indicates the development of the arches in the transverse plane [7].

In order to determine Pont's index, one measures (by using a ruler/ some other device) the distance (width) between the upper and lower molars and the distance (width) between the upper and lower premolars on the study model. These values will be compared to a value that is established with the help of a standard formula. If there are differences between the established values and the values obtained through measurement, it means that there are some anomalies. Depending on the identified anomaly, one chooses the correct therapeutic solution.

The measurement method for the upper arch is the following:

- the interpremolar distance (width) for the upper arch is measured from the center of the occlusal grooves of the maxillary first premolars (fig. 1)




Fig. 1. Measuring the interpremolar width of the upper arch

- the intermolar distance for the upper arch is measured from the center of the occlusal grooves of the maxillary first molars (fig. 2)




Fig. 2. Measuring the intermolar width of the upper arch

The measurement method for the lower arch is the following:

- the premolar diameter of the lower arch is measured at the level of the vestibular contact point of the mandibular premolars (fig. 3)



Fig. 3. Measuring the premolar diameter for the lower arch

- the molar diameter of the lower arch is measured at the level of the tip of the mesiovestibular cusps of the mandibular first molar (fig. 4)

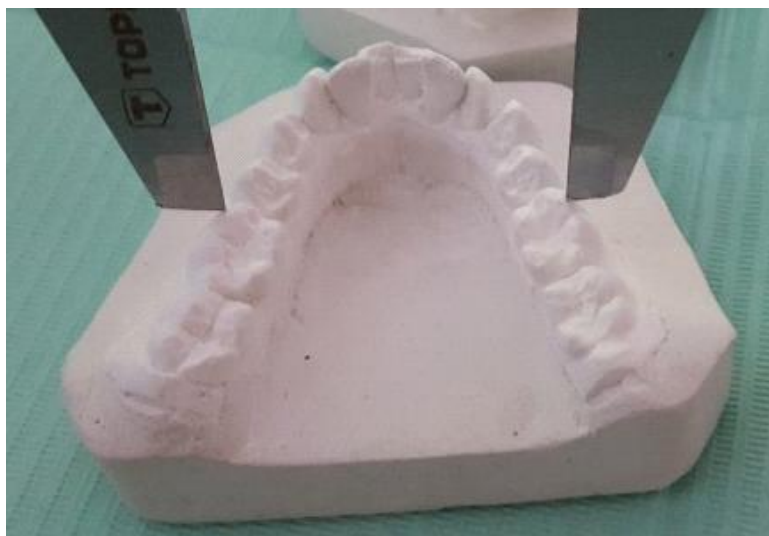

Fig. 4. Measuring the intermolar width of the lower arch

The values obtained through measurement are written down in patient's medical record. These values are compared to the values established with the help of the formulas.

Employed formulas (SI = sum of the incisal widths of incisors):

- for the premolar diameter: $PD = SI \times 100 / 80$
- for the molar diameter: $MD = SI \times 100 / 64$

In the formula, the value employed for both arches is the sum of the upper incisal width of incisors.

SI is the sum of the mesio-distal diameters of the four maxillary incisors. The normal values are between 28-35 mm; any value under 28 mm is absolute microdontia, while any value that is over 35 mm is absolute macrodontia.

If the values established through measurements are lower than the values established through calculation, Pont's index shows a narrowing of the arches (either at premolar level or at molar level, depending on the case). In the opposite situation, the index shows an excessive width of the arches.

Any differences from Pont's index may be assessed as follows:

+/- 2 mm – normal

+/- 2-4 mm – slight deviation

+/- 4-10 mm – significant deviation

+/- 10 mm – major deviation

There are some situations when this index is not applicable:

- when the premolars/molars are missing or they have an incomplete/ ectopic eruption, Pont's index cannot be determined
- when the sum of the incisal widths of incisors does not belong to the standard range (28-35 mm)
- it cannot be applied in the case of mixed dentition

*Pont's index refers to brachycephalic people from southern France, so one should keep in mind that this analysis may not be accurate and it should not be seen as completely reliable.

Tanaka and Johnston Analysis

This analysis is useful in the case of mixed dentition, in order to foresee the space that is needed for further alignment of the canine, first premolar and second premolar in permanent dentition [2].

The formula is applied to one hemiarch. For both arches, the value taken into consideration is the sum of the lower SI (sum of the incisal widths of incisors).

- upper arch – the room needed for the alignment of teeth 3,4,5 = the lower SI/2 + 11 mm

- lower arch – the room needed for the alignment of teeth 3,4,5 = the lower SI/2 + 10.5 mm

The value obtained through calculation is compared to the value obtained through measurements made on the study model, between the distal side of the lateral incisor and the mesial side of the first molar.

If the value obtained through measurement is lower than the one obtained through calculation, the analysis reveals that there is not enough space for permanent tooth eruption (space deficit).

Tanaka & Johnston		
Half of the mesio-distal distance between the four mandibular incisors	+10.5 mm	= C+PM1+PM2 for one quadrant for the mandible
	+ 11 mm	= C+PM1+PM2 for one quadrant for the maxillary

Perimetry

Perimetry is an indicator for space deficit/space excess. This measurement method offers information about the necessary space for permanent teeth alignment.

With the help of a divider/ any other device, one measures the mesio-distal diameter of each tooth (fig. 1) which is situated in a mesial position as compared to the first permanent molar. By making the sum of these diameters, one obtains the dental perimeter of that arch. This value is compared to the alveolar perimeter. The difference between the two may be a sign of space deficit or of space excess.




Fig. 1. Measuring the mesio-distal diameter of the mandibular second molar (for the calculation of the dental perimeter)

The alveolar perimeter is measured between the mesial sides of the first permanent molars, with the help of a small string. Then the string is measured with a ruler and the value is written down in the medical record of the patient. (fig. 2).

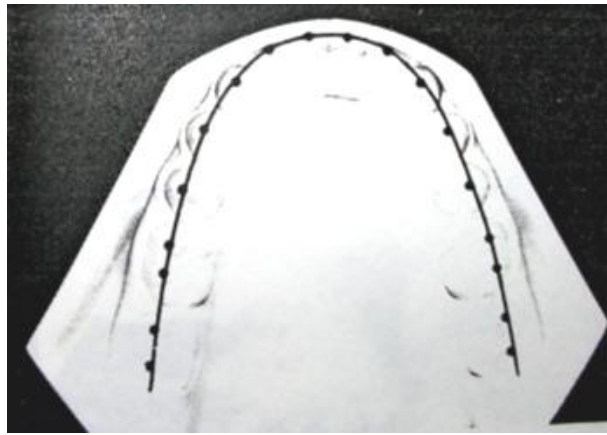


Fig. 2. The alveolar perimeter

Bolton Analysis

Bolton analysis helps in discovering if there is a difference in volume between the teeth on the upper arch and the teeth on the lower arch this measurement method is necessary for establishing a diagnosis and an appropriate treatment plan, as well as for discovering if there is a need for interproximal reduction (stripping).

There are two versions of this analysis - the Anterior Analysis and the Overall Analysis. If there are missing teeth on the lateral side, the Anterior Analysis is the only one that can be carried out.

Calculation method – Overall Analysis

- one measures and makes the sum of the mesio-distal diameters of the 12 lower teeth and the sum of the mesio-distal diameters of the 12 upper teeth (up to the second molar)
- the values obtained are written down in patient's medical record
- one calculates the ratio between the two values and the sum is multiplied by 100

The obtained percentage indicates the following:

- the normal value is 91.3 %
- any value that exceeds this percentage is a sign of excessive width of the lower teeth
- any value that is lower than this percentage is a sign of excessive width of the upper teeth

Depending on the values obtained, interproximal reduction will be performed either on the upper arch or on the lower arch.

Calculation method – Anterior Analysis

- the calculation formula stays the same, but it only contains the sum of the mesio-distal diameters of the six front teeth (up to the first premolar)
- the sum of the mesio-distal diameters of the six lower teeth/ the sum of the mesio-distal diameters of the six upper teeth x 100
- the normal value is 77,2 %.

8. CEPHALOMETRIC RADIOGRAPHY

Cephalometric radiography is employed in the orthodontic diagnosis in order to examine the dental and facial relationships of the patient before the treatment, the changes that appear during the treatment as well as for the final assessment after the orthodontic treatment.

The orthodontic diagnosis is not reached based on cephalometry alone, as it is complementary to the process of establishing the diagnosis.

Uses of the cephalometric analysis:

- Diagnosis purposes, in order to establish whether a malocclusion is due to skeletal or dental causes
- Allows the clinician to know exactly to what extent the patient deviates from the normal values.
- Monitoring the changes that appear during growth or during treatment.
- VTO (Visualized Treatment Objective)

A cephalometric analysis implies the precise localization of several points which represent intersections, lines or overlappings of the anatomical structures as a result of the radiological projection, and the assessment of the ratios between these cephalometric points and landmarks. Several cephalometric analyses have been developed with the purpose of establishing criteria and standards that could define an ideal of facial proportions. Based on the linear and angular measurements, one can establish the vertical and sagittal positions of the maxillaries as compared to the base of the skull, as well the position between themselves, their relationship with the dental structures, the interdental relationships and the assessment of soft tissues.

Methods of cephalometric analysis:

1. The manual method – transfer paper is superposed on the radiograph and the outline of the soft and hard tissues is traced
2. The digital method – there are many cephalometric softwares, among which the most popular are: Romexis Planmeca, AudaxCeph etc.

1. Employed landmarks in the analysis of the teleradiography

Cephalometric landmarks

1.1. Bony landmarks

NASION (N) – most anterior point on the frontonasal suture in the mid-sagittal plane; it corresponds to the nasal root.

– anatomic, bony, unilateral landmark

Localization: one traces the outline of the cortical plate of the frontal bone, the nasal bone and the frontonasal suture. Nasion is the meeting point of the three;

Applicability: Nasion is used as a reference point in drawing the angles and planes which assess:

- The relationship between the maxilla and the cranial base: ANS angle
- The relationship between the mandible and the cranial base: SNB angle
- The relationship between the maxilla, the mandible and the cranial base: ANB angle
- The position of the maxillary incisors: the angle between NA and the axis of the maxillary incisor and the linear distance NA - maxillary incisor
- The position of the mandibular incisors: the angle between NB and the axis of the mandibular incisor and the linear distance NB -mandibular incisor
- The angle of sella turcica: N-S-Ar

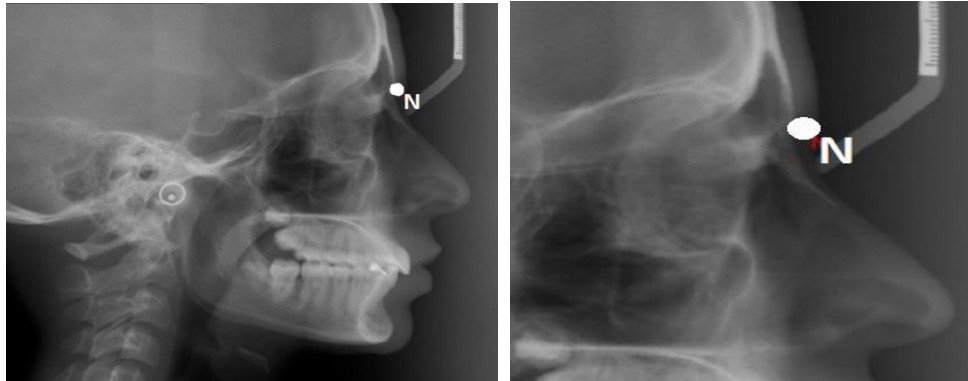

Fig. 1.1. Nasion – radiographic appearance

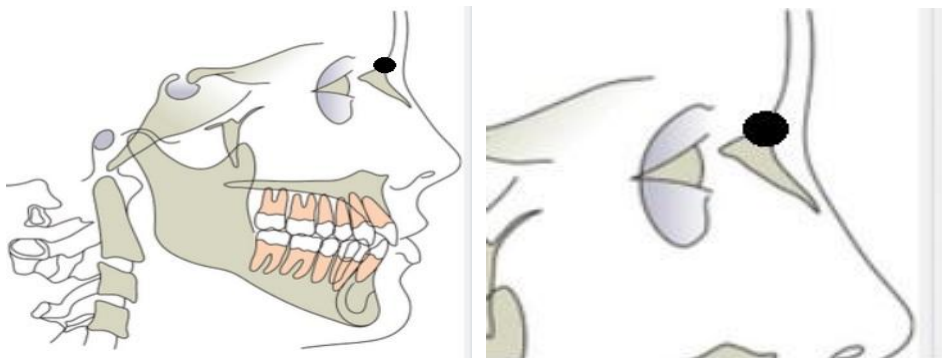


Fig. 1.2. Nasion – graphic illustration (Audax)

SELLA (S) – the midpoint of sella turcica

– anatomic, bony, unilateral landmark

Localization: the sella turcica is located in the upper body of the sphenoid bone and it is bounded by the anterior and posterior clinoid processes; one traces the outline of the clinoid processes and the lower margin of the fossa. The geometric center of the sella turcica is the Sella.

Applicability: it is used as a reference point in the construction of the angles and planes which assess:

- The relationship between the maxilla and the cranial base: ANS angle
- The relationship between the mandible and the cranial base: SNB angle
- The angle of sella turcica: N-S-Ar

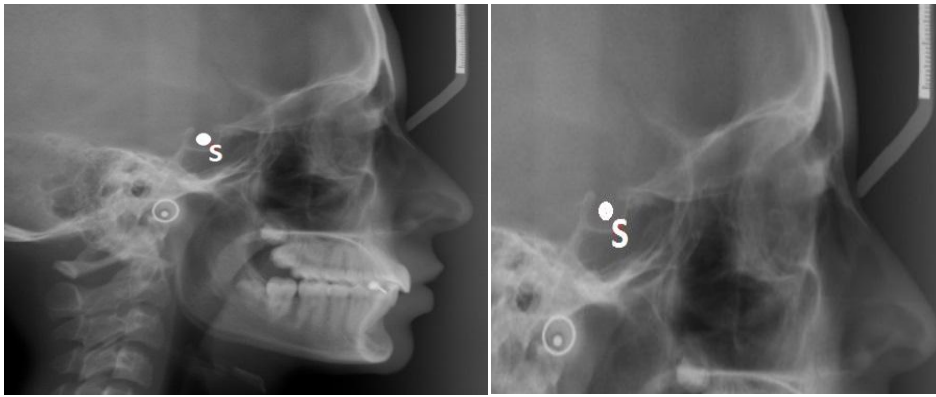


Fig. 1.3. Sella – radiographic appearance

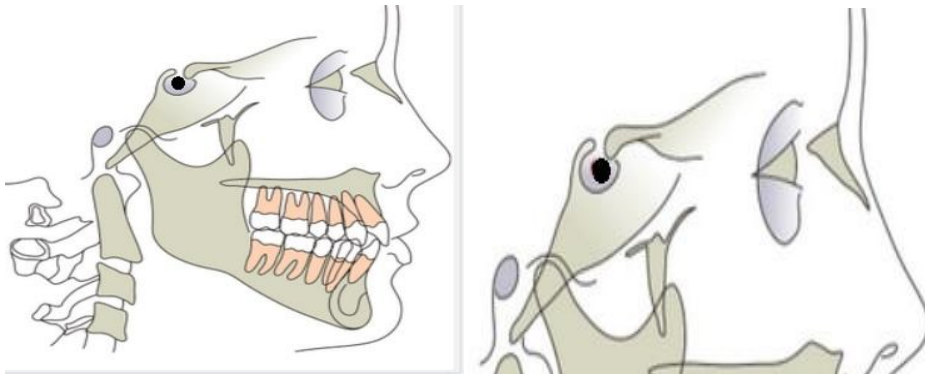


Fig. 1.4. Sella – graphic illustration (Audax)

BASION (Ba) – the most inferior point of the anterior margin of the foramen magnum, located at the base of clivus occipitalis.

– anatomic, bony, unilateral landmark

Localization: the distance between the upper delimitation of the second cervical vertebra and Basion is of 3 mm approximately.

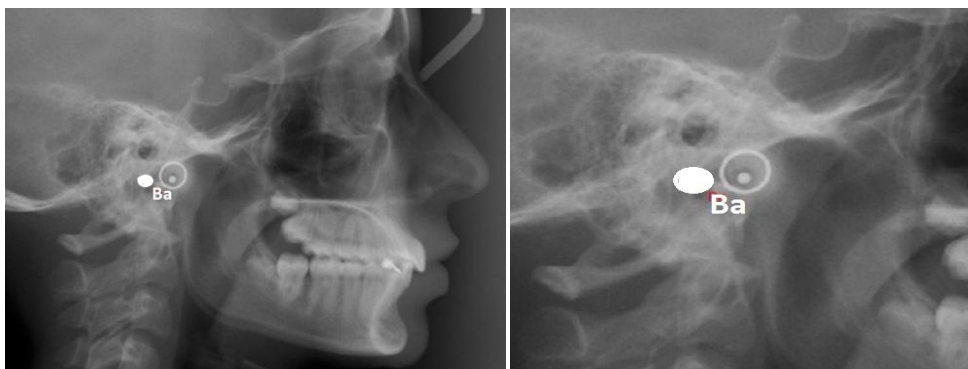

Fig. 1.5. Basion - radiographic appearance

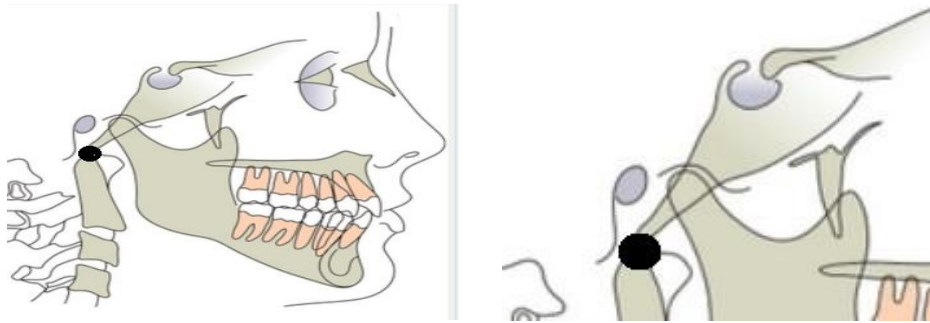


Fig. 1.6. Basion - graphic illustration (Audax)

PORION (Po) – the superior (most external) point on the bony delimitation of the external auditory meatus

– anatomic, bony, bilateral landmark

Localization: - 3-4 mm radiolucence, located at the same height as the condylar head approximately

- the internal auditory meatus is in an "11 o'clock position" as compared to the external auditory meatus

- the Frankfort Horizontal (Po-Or) makes a 27-29° angle with the cranium base (Ba-N).

Applicability: Porion is used as a reference point in drawing the Frankfort Horizontal (Po-Or) which assesses the vertical growth pattern using following angle:

- FMA angle - Frankfort Horizontal and the mandibular plane (Go-Me)

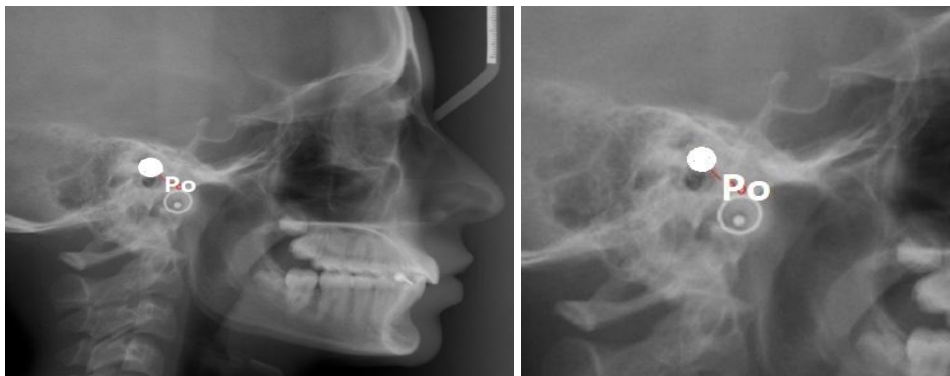

Fig. 1.7. Porion - radiographic appearance

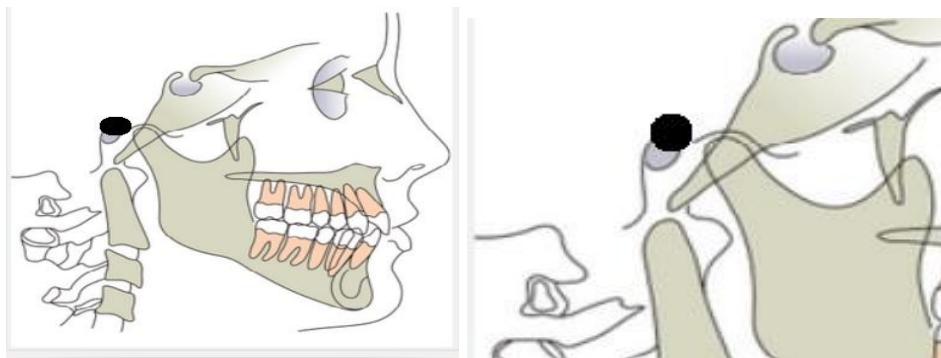


Fig. 1.8. Porion - graphic illustration (Audax)

ORBITALE (Or) – The lowest point in the inferior margin of the orbit .

– anatomic, bony, bilateral landmark

Localization: if the patient is in a correct position, right and left infra-orbital margins are superimposed on the lateral cephalogram and appear under the shape of a radiopaque line on the teleradiography. Orbitale will be the inferiormost point on the inferior margin of the orbit.

Applicability: Orbitale is used as a reference point in drawing the Frankfort Horizontal (Po-Or) which assesses the vertical growth pattern through:

- FMA angle - Frankfort Horizontal and the mandibular plane (Go-Me)

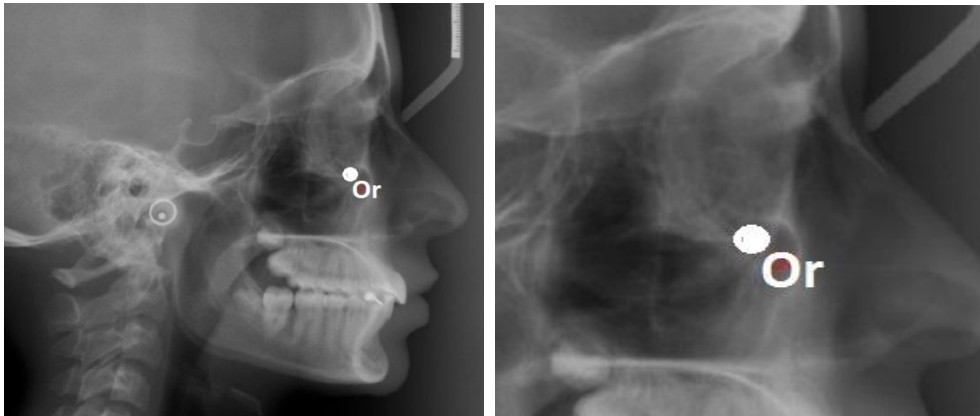


Fig. 1.9. Orbitale - radiographic appearance

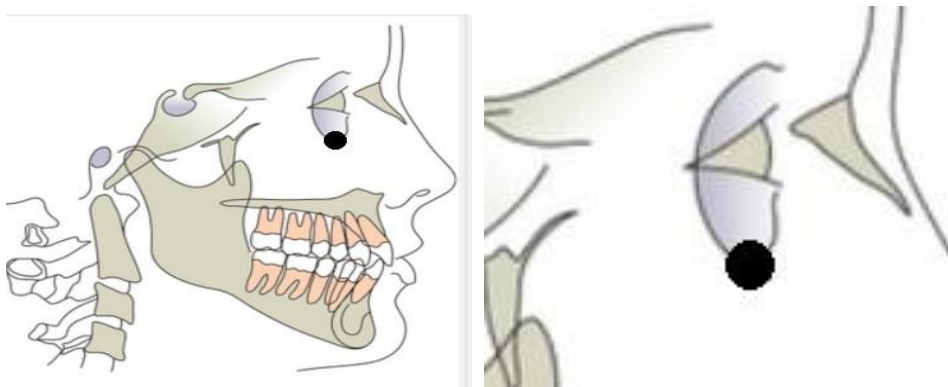


Fig. 1.10. Orbitale - graphic illustration (Audax)

THE ANTERIOR NASAL SPINE (ANS) – the anteriormost point of the nasal spine

– anatomic, bony, unilateral landmark

Localization: there is an individual variation in the length and width of the anterior nasal spine; in some cases, it can be long and thin, in other cases it can be short and thick.

- If the nasal spine is thin, it will appear unclear and it will overlap with the nasal cartilage
- If the nasal spine is thick, it will appear clear and it will be easy to trace.

Applicability: The anterior nasal spine is a landmark for drawing the palatal plane (ANS-PNS) employed in:

- Ricketts analysis/ McLaughlin analysis – vertical ratio between the maxilla and the mandible: the angle between the mandibular plane (Go-Me) and the palatal plane (ANS-PNS)
- The position of the maxillary incisor as compared to the palatal plane (the axis of the maxillary incisor – PP)
- McLaughlin analysis: the angle between the palatal plane and the occlusal plane

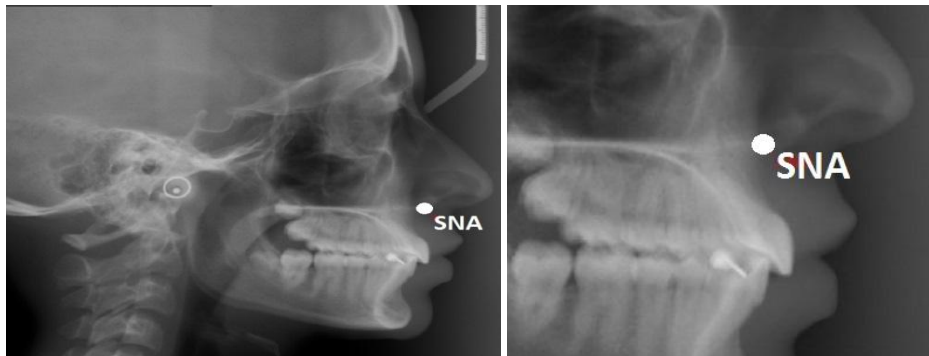


Fig. 1.11. ANS - radiographic appearance

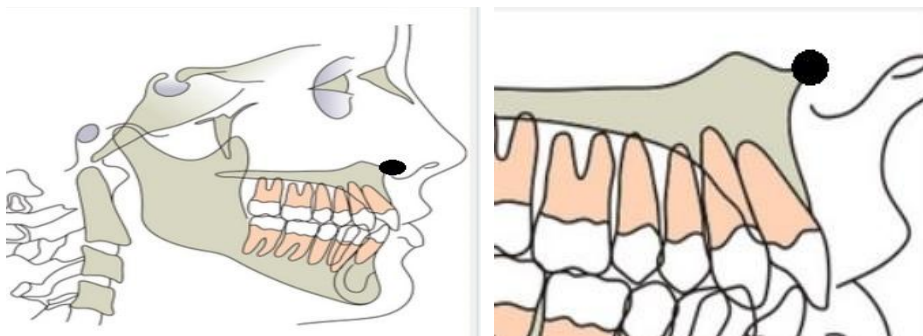


Fig. 1.12. ANS - graphic illustration (Audax)

THE POSTERIOR NASAL SPINE (PNS) – The posteriormost point of the hard palate
– anatomic, bony, unilateral landmark

Localization: just as for the anterior nasal spine, the length as well as the height of the posterior nasal spine may vary; it is difficult to trace it when there are unerupted teeth – in this situation, PNS may be localized between the floor of the nasal cavity and the lower margin of the palatal bone.

Applicability: The posterior nasal spine is a reference point for drawing the palatal plane (ANS-PNS) employed in:

- Ricketts analysis/ McLaughlin analysis – vertical ratio between the maxilla and the mandible: the angle between the mandibular plane (Go-Me) and the palatal plane (ANS-PNS)
- The position of the maxillary incisor as compared to the palatal plane (the axis of the maxillary incisor – PP)
- McLaughlin analysis: the angle between the palatal plane and the occlusal plane

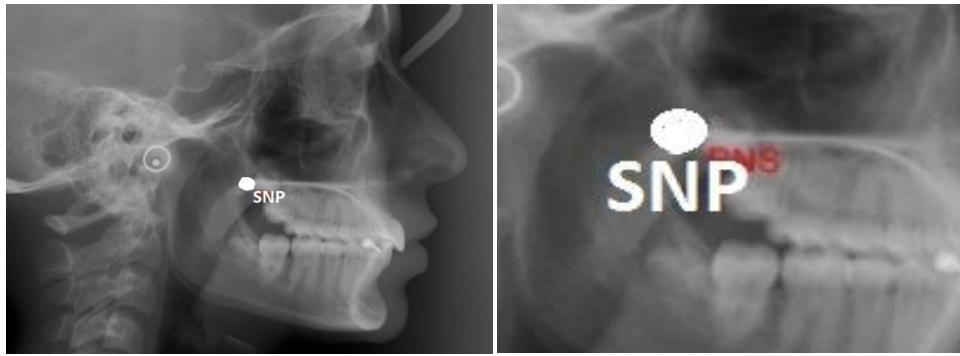

Fig. 1.13. PNS - radiographic appearance

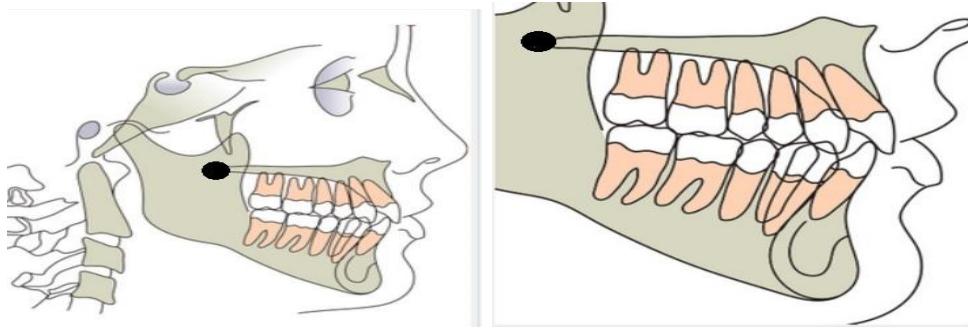


Fig. 1.14. PNS - graphic illustration (Audax)

PROSTHION (Pr) – the inferior- and anteriormost point of the upper alveolar process in the mid-sagittal plane.

– anatomic, bony, unilateral landmark

Localization: it delimits the alveola of the maxillary central incisor at the cemento-enamel junction

Applicability: a landmark in drawing the angle for assessing the position of the maxillasketal base to the cranial base: S-N-Pr

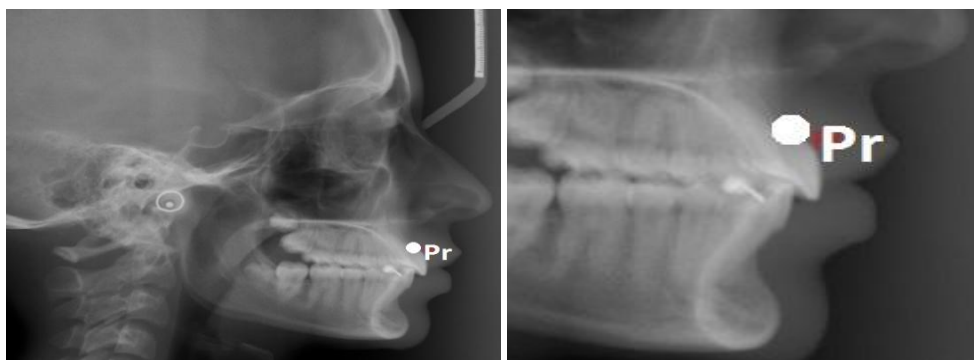


Fig. 1.13. Prosthion - radiographic appearance

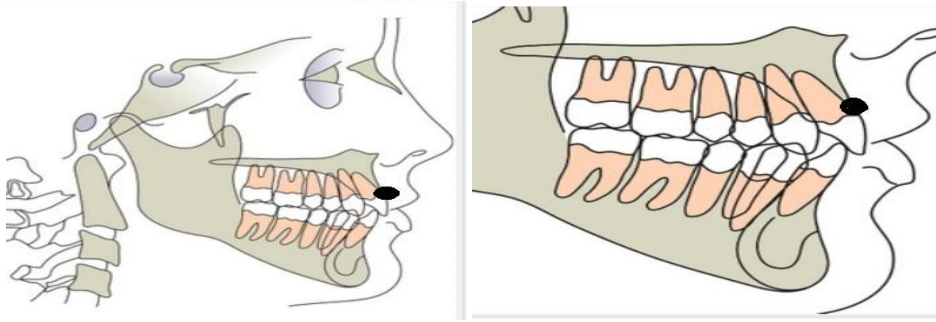


Fig. 1.14. Prosthion - graphic illustration (Audax)

A POINT – the posteriormost point on the curvature of the anterior nasal spine under ANS and in front of the root of the maxillary central incisor. The posteriormost point on the bony outline between ANS-Pr.

– anatomic, bony, unilateral landmark

Localization: one traces the outline of the palate bone, the anterior nasal spine and the anterior margin of the alveolar process. Then, one traces the outline of the maxillary central incisor including the apex and the incisal edge.

*A Point is 2 mm anterior to and approximately at the same height with the apex of the central incisor.

Applicability: a reference point in drawing the planes and the angles which assess:

- The relationship between the maxilla and the cranial base: SNA angle
- The relationship between the maxilla, the mandible and the cranial base: ANB
- The position of the maxillary incisors: the angle between NA and the axis of the maxillary incisor and the linear distance NA - maxillary incisor
- WITS analysis: the perpendicular drawn from the A Point to the occlusal plane
- Ricketts analysis: the distance/ angulation of the maxillary/mandibular incisors on the A-Pg plane

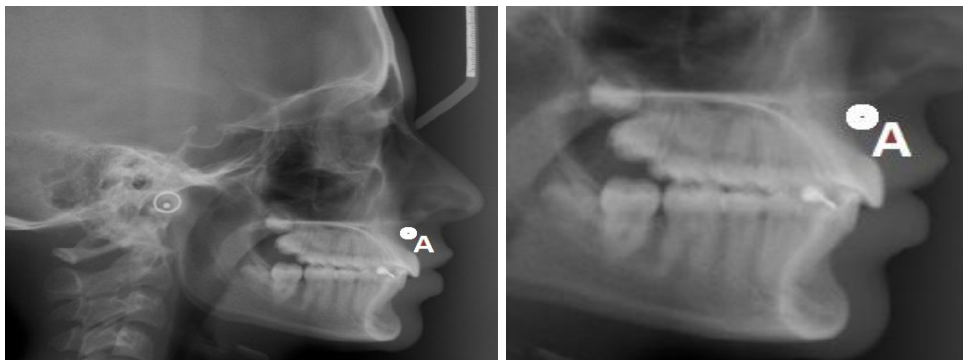


Fig. 1.17. A Point - radiographic appearance

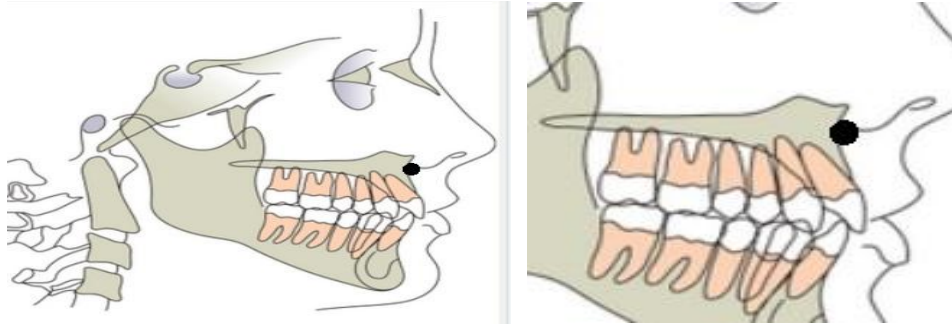


Fig. 1.18. A Point - graphic illustration (Audax)

INFRADENTALE (Id) – the superior and anteriormost point of the lower alveolar process in mid-sagittal plane. It delimits the alveola of the mandibular central incisor at the cemento-enamel junction.

–anatomic, bony, unilateral landmark

Localization: It delimits the alveola of the mandibular central incisor at the cemento-enamel junction

Applicability: it is a reference point in drawing the S-N-Id angle

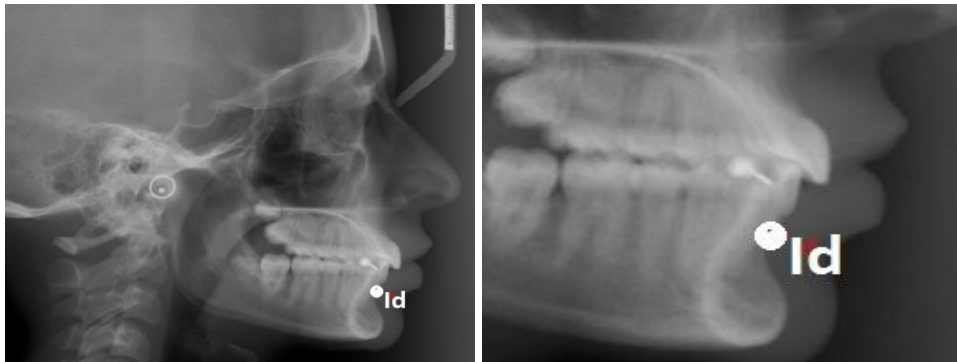


Fig. 1.19. Infradentale - radiographic appearance

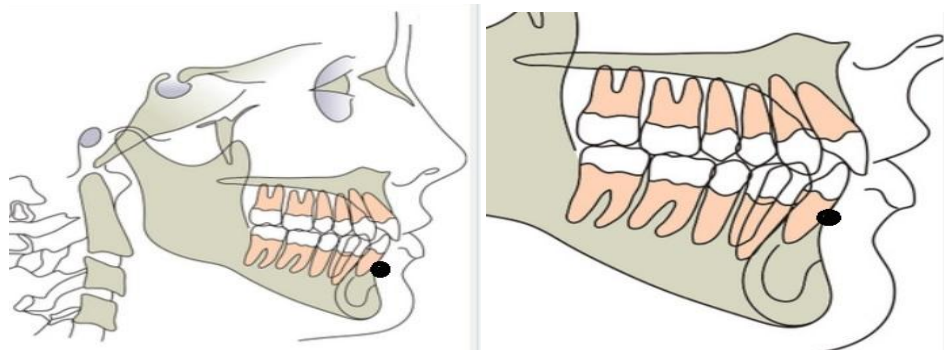


Fig. 1.15. Infradentale - graphic illustration (Audax)

POGONION (Pog) – the anteriormost midpoint on the mental protuberance

– anatomic, bony, unilateral landmark

Localization: one traces the outline of the labial cortical plate in the anterior symphysis. Below the B Point, there is a convex outline of labial cortical plate of mandible and Pogonion is its most prominent point.

Applicability: a reference point in drawing the planes and the angles which assess:

- The relationship between the mandible and the cranial base: the facial angle – S-N-Pog
- Ricketts analysis: the distance/ angulation of the maxillary/ mandibular incisors on the A-Pg plane
- McLaughlin analysis: the distance between Pog and the N-based perpendicular to the Frankfort Horizontal

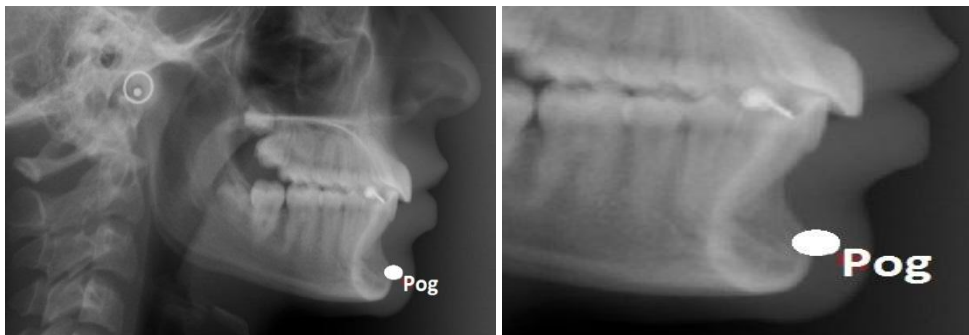


Fig. 1.21. Pogonion - radiographic appearance

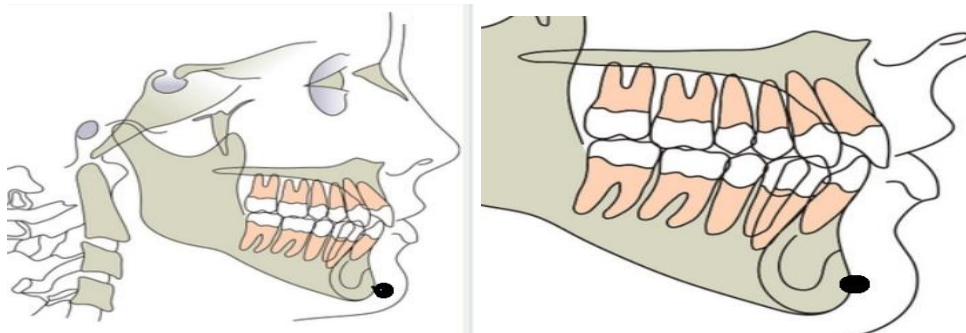


Fig. 1.22. Pogonion - graphic illustration (Audax)

B POINT – the posteriormost point on the profile of the mandibular alveolar process, between Id and Pog

– anatomic, bony, median landmark

Localization: one traces the outline of the labial cortical plate of the mandible from the Infradentale to Pogonion. B Point is the posteriormost point between the two.

Applicability: it is used as a reference point in drawing the angles and planes which assess:

- The relationship between the mandible and the cranial base: SNB angle
- The relationship between the maxilla and the mandible and the cranial base: ANB angle
- The position of the mandibular incisors: the angle between NB and the axis of the mandibular incisor and the linear distance NB - mandibular incisor
- WITS analysis: the perpendicular drawn from the B Point to the occlusal plane

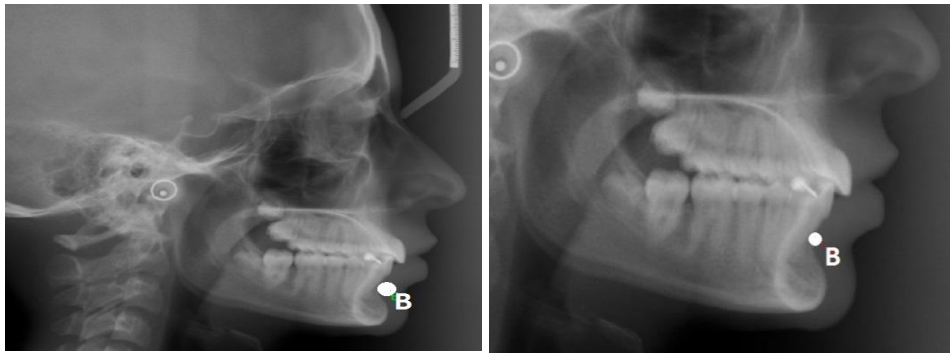


Fig. 1.16. B Point - radiographic appearance

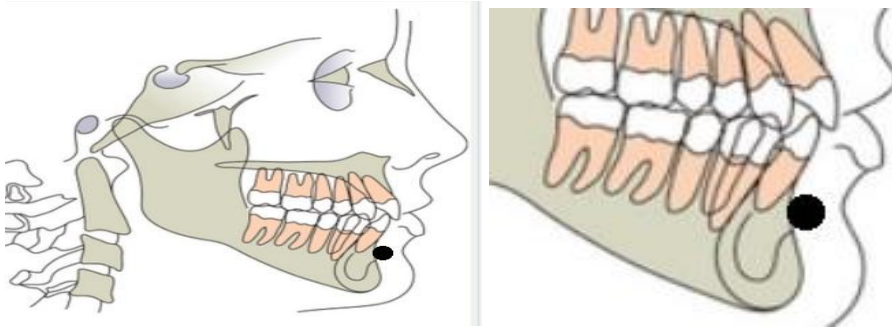


Fig. 1.17. B Point - graphic illustration (Audax)

GNATHION (Gn) – the anterior- and inferiormost point of the menton.

– constructed, bony, unilateral landmark

Localization: one traces the labial cortical plate of the mandible. Under B Point (the posteriormost point) there are Pog (the anteriormost point) and Me (the anterior- and inferiormost point). One then traces a straight line between Pog and Me; Gn is the middle of it, the point determined by the bisector of the angle of intersection of the facial plane (N-Pog) and the mandibular plane (Go- Me).

Applicability: a reference point in drawing the angles and planes which assess:

- The growth pattern: N-S-Gn angle
- Mandibular rotation: Jarabak – SeGn/Frankfort Horizontal axis
- Ricketts analysis: mandibular growth direction: the angle formed by the facial axis (Pt-Gn) with Ba-N

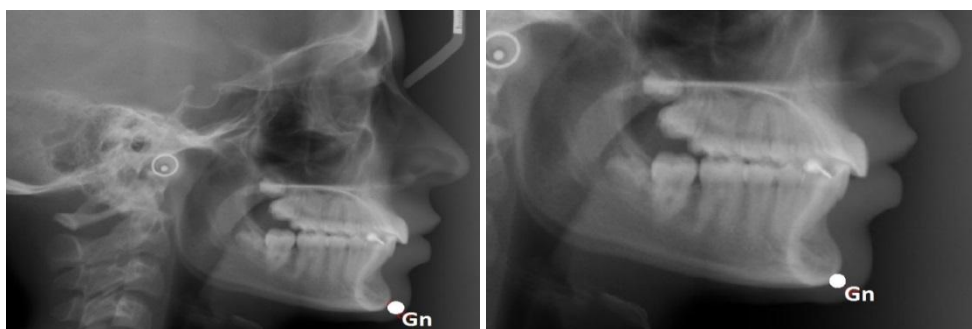


Fig. 1.25. Gnathion - radiographic appearance

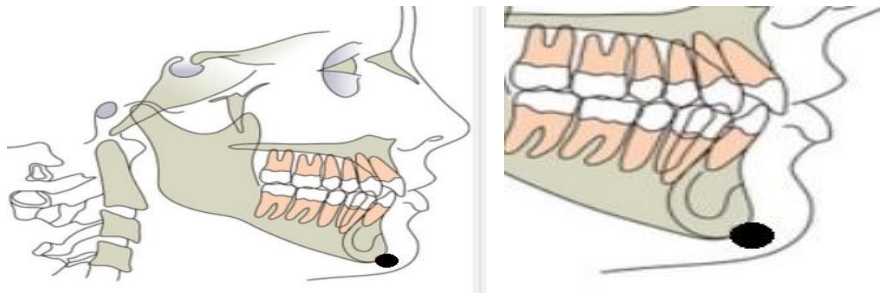


Fig. 1.26. Gnathion - graphic illustration (Audax)

MENTON (Me) – the inferiormost point on the mandibular symphysis.

– anatomic, bony, unilateral landmark

Localization: one traces the labial cortical plate of the mandibular symphysis; Menton is the anterior- and inferiormost point on the lower side of the mandibular symphysis.

Applicability: it is a reference point in drawing the Go-Me mandibular plane which is used when assessing:

- The position of the mandibular incisor: the angle formed by the axis of the mandibular incisor with the mandibular plane
- Tweed analysis: FMA angle formed by the Frankfort Horizontal (Po-Or) with the mandibular plane
- The growth pattern: the angle formed by the SN plane with the mandibular plane
- McLaughlin analysis: the angle formed by the occlusal plane with the mandibular plane
- McLaughlin analysis: the angle formed by the palatal plane with the mandibular plane

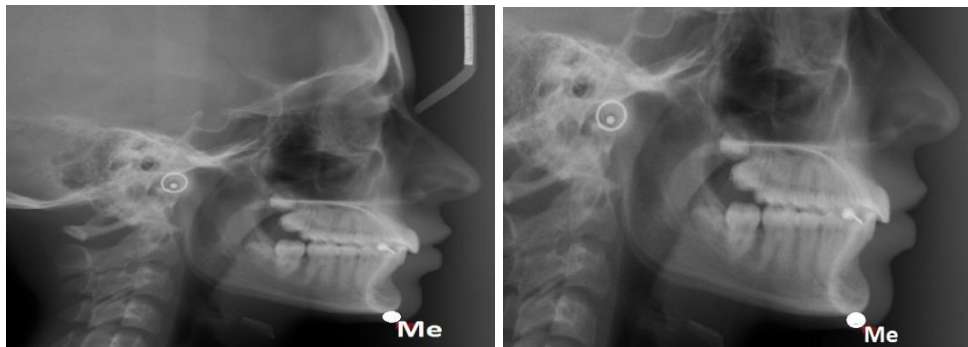

Fig. 1.27. Menton - radiographic appearance

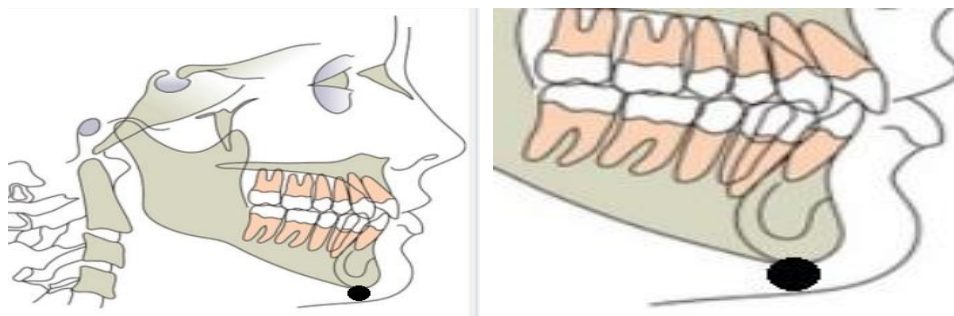


Fig. 1.28. Menton - graphic illustration (Audax)

GONION (Go) – the posteriormost, inferiormost and most lateral point of each gonial angle
– anatomic, bony, bilateral landmark

Localization: one traces the outline of the inferior and posterior borders of the mandible; Gonion is represented by the intersection of the tangent to the two margins.

Applicability: it is a reference point in drawing the Go-Me mandibular plane which is used when assessing:

- The position of the mandibular incisor: the angle formed by the axis of the mandibular incisor with the mandibular plane
- Tweed analysis: FMA angle formed by the Frankfort Horizontal (Po-Or) with the mandibular plane
- The growth pattern: the angle formed by the SN plane with the mandibular plane
- McLaughlin analysis: the angle formed by the occlusal plane with the mandibular plane
- McLaughlin analysis: the angle formed by the palatal plane with the mandibular plane

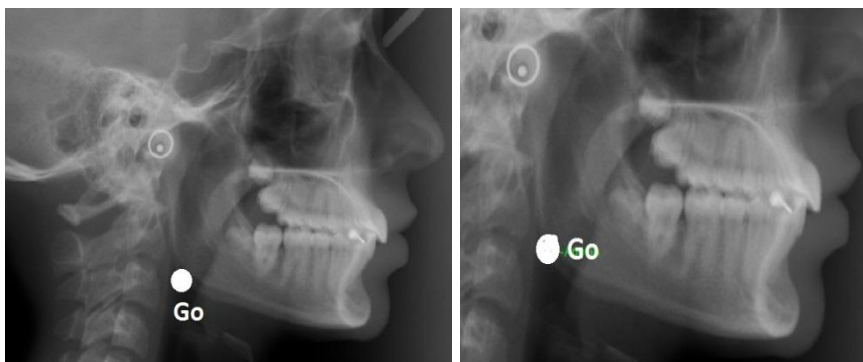


Fig. 1.29. Gonion - radiographic appearance

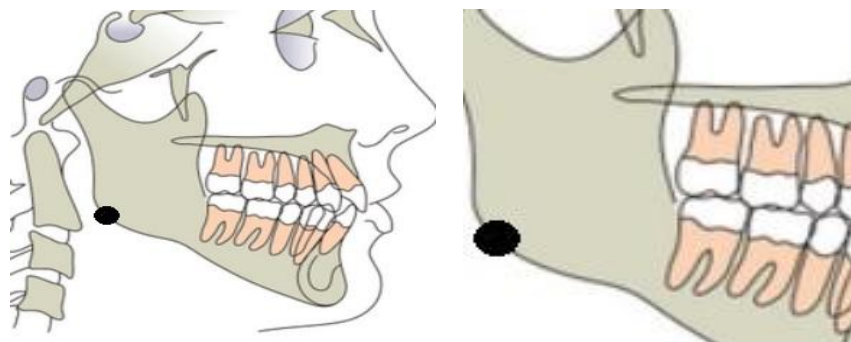


Fig. 1.30. Gonion - graphic illustration (Audax)

1.2 Cutaneous landmarks

GLABELLA (G) – the anteriormost point of the forehead in the mid-sagittal plane, at the level of the upper orbital ridges

– cutaneous, unilateral landmark

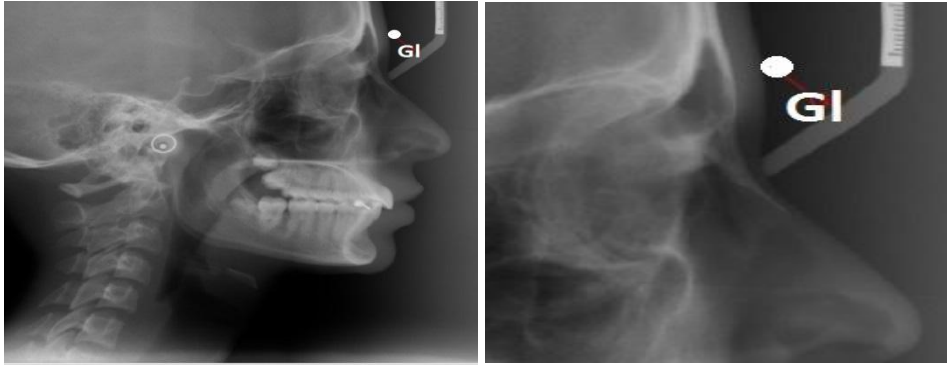


Fig. 1.31. Glabella - radiographic appearance

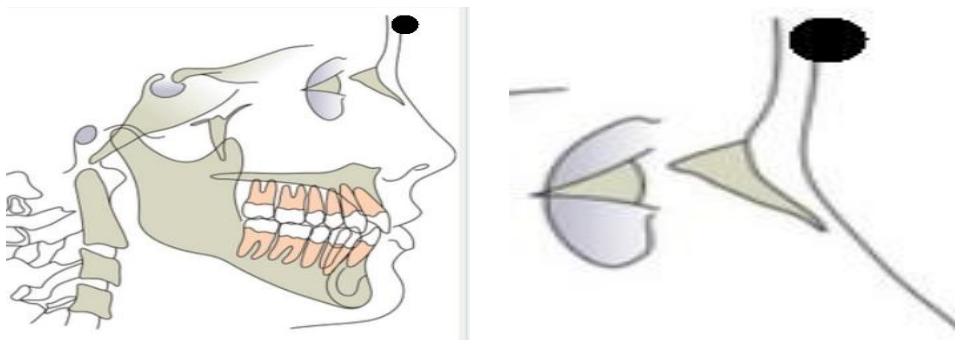


Fig. 1.32. Glabella - graphic illustration (Audax)

NASION (n) – posteriormost point of the nasal root

– cutaneous, unilateral landmark

Applicability: Nasofrontal or Dreyfus plane

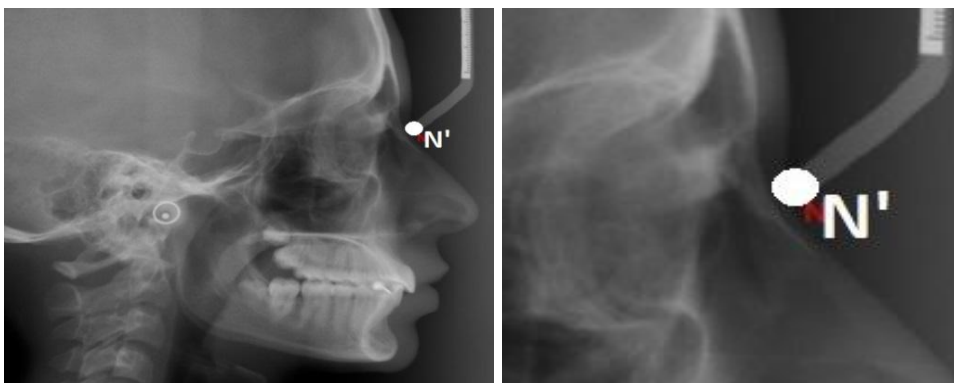

Fig. 1.33. Nasion - radiographic appearance

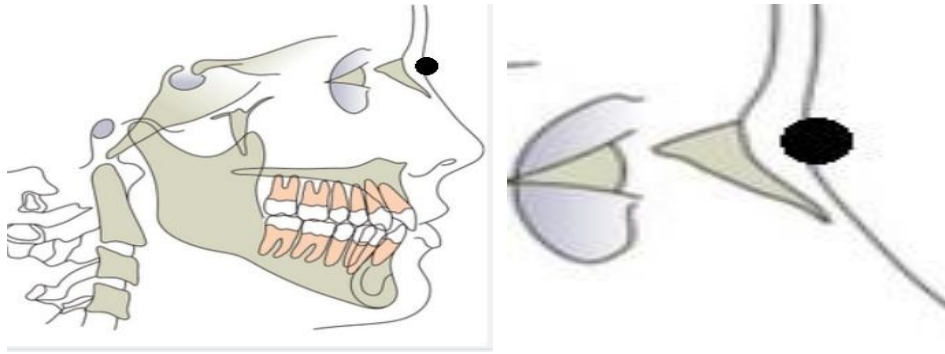


Fig. 1.34. Nasion - graphic illustration (Audax)

PRONASALE (Pn) – the anteriormost point of the nose

– cutaneous, unilateral landmark

Applicability

- landmark in assessing nasal projection
- Ricketts analysis: Ricketts' aesthetic line (E-line) – assessing the relationship between the maxillary/mandibular incisors and the upper/lower lip

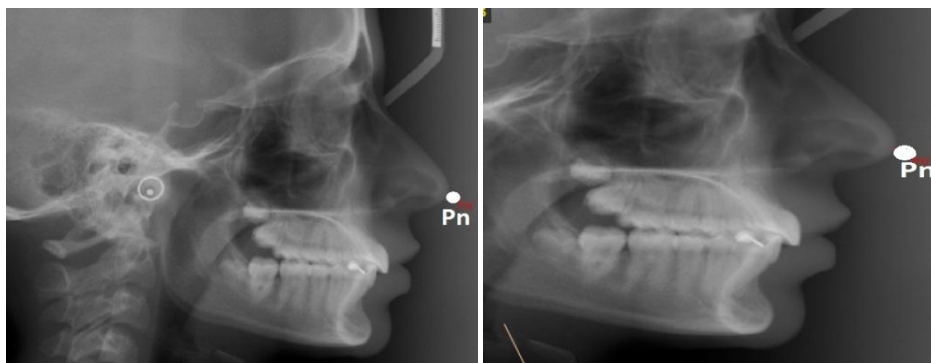


Fig. 1.35. Pronasale - radiographic appearance

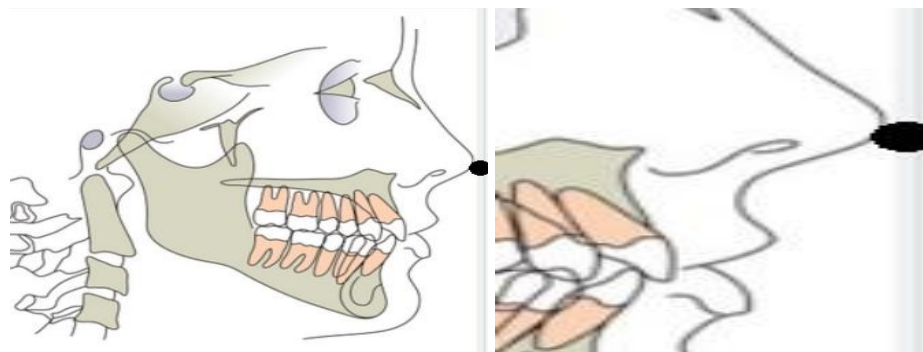


Fig. 1.36. Pronasale - graphic illustration (Audax)

SUBNASALE (Sn) – it corresponds to the junction between the philtrum of the upper lip and the columella in mid-sagittal plane

– cutaneous, unilateral landmark

Applicability:

- landmark in assessing nasal projection and nose height
- Burstone’s line – assessing the relationship between the maxillary/ mandibular incisors and the upper/ lower lip

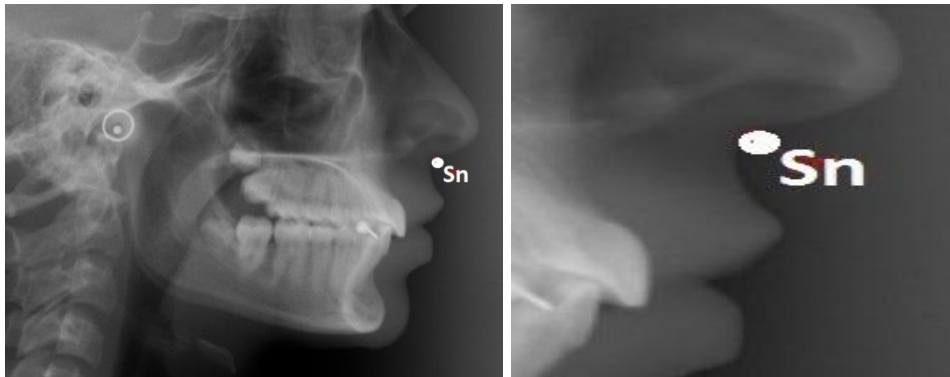


Fig. 1.37. Subnasale - radiographic appearance

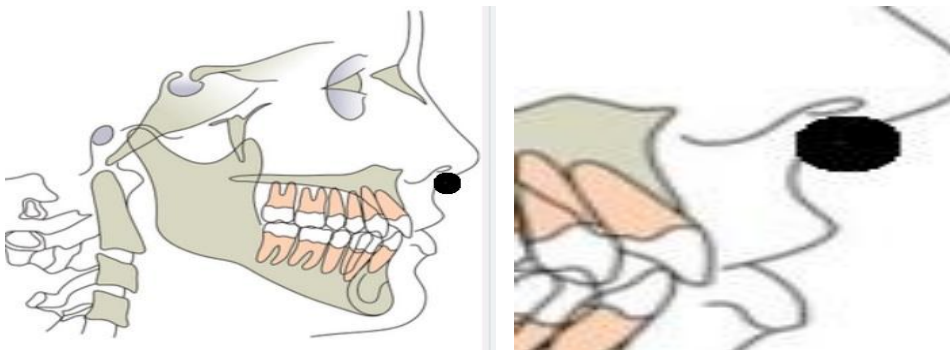


Fig. 1.38. Subnasale - graphic illustration (Audax)

LABIALIS SUPERIOR (Ls) – the anteriormost point of the margin of the upper lip

– cutaneous, unilateral landmark

Applicability:

- Holdaway line for assessing the relationship between the maxillary/ mandibular incisors and the upper/ lower lip
- Merrifield’s Z-angle for assessing the relationship between the maxillary/ mandibular incisors and the upper/ lower lip
- Measuring the length of the upper lip
- Arnett’s analysis – PIP (planned incisor position)

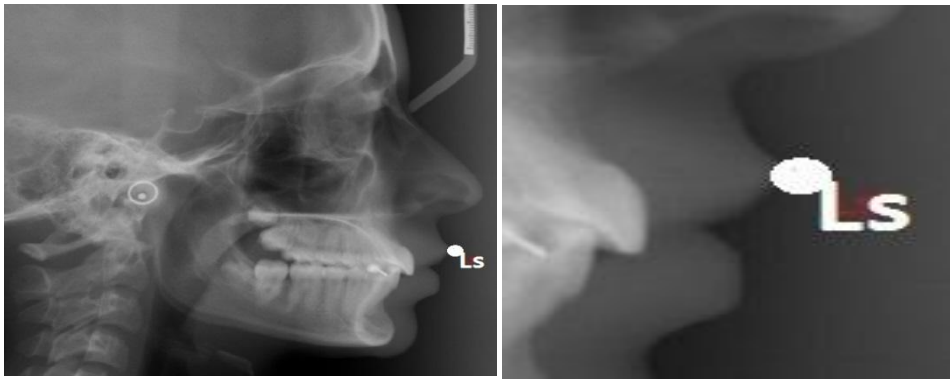

Fig. 1.39. Labialis superior - radiographic appearance

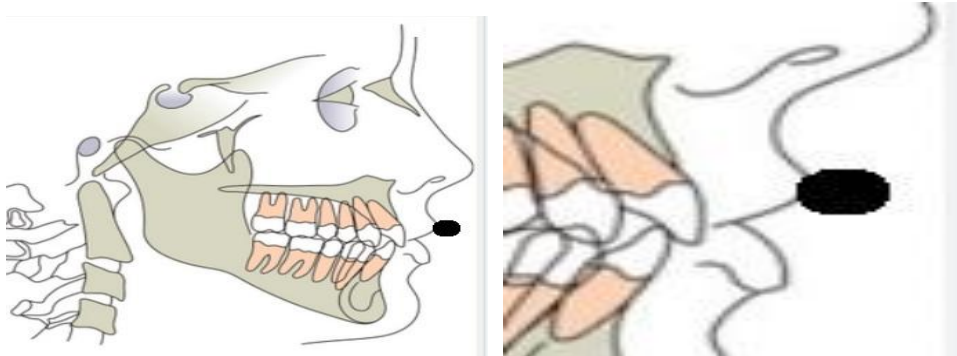


Fig. 1.40. Labialis superior - graphic illustration (Audax)

LABIALIS INFERIOR (Li) – anteriormost point of the interior margin of the lower lip
 – cutaneous, unilateral landmark

Applicability:

- Measuring the length of the lower lip
- Arnett's analysis – PIP (planned incisor position)

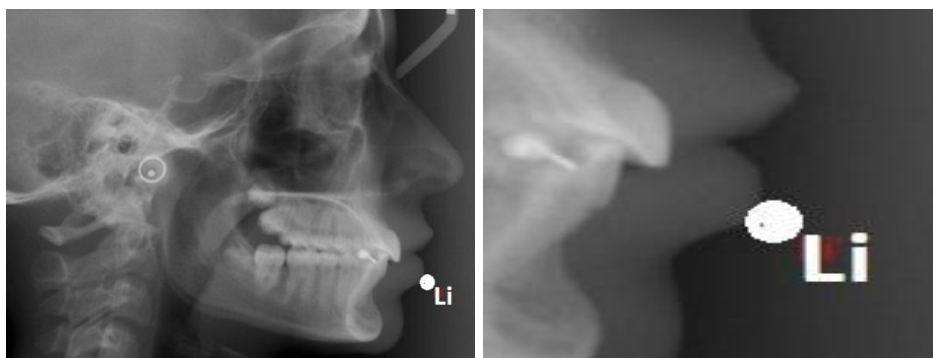

Fig. 1.41. Labialis inferior - radiographic appearance

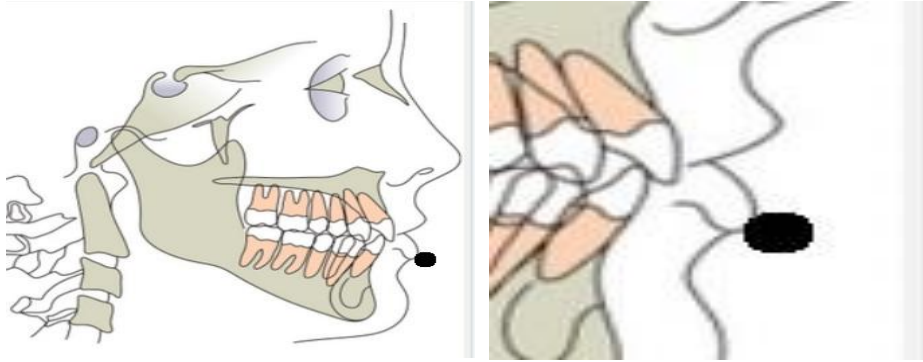


Fig. 1.42. Labialis inferior - graphic illustration (Audax)

SOFT TISSUE POGONION (Pog) – anteriormost point of the chin in mid-sagittal plane
 – cutaneous, unilateral landmark

Applicability:

- Landmark in assessing the chin projection
- Steiner’s aesthetic line - “S line”
- Ricketts’ aesthetic line – “E line”
- Burstone’s aesthetic line – “B line”
- Holdaway’s aesthetic line - “H line”

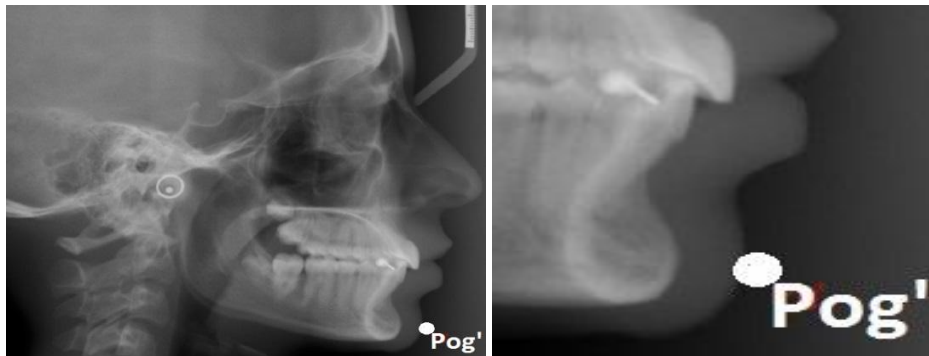

Fig. 1.43. Pogonion - radiographic appearance

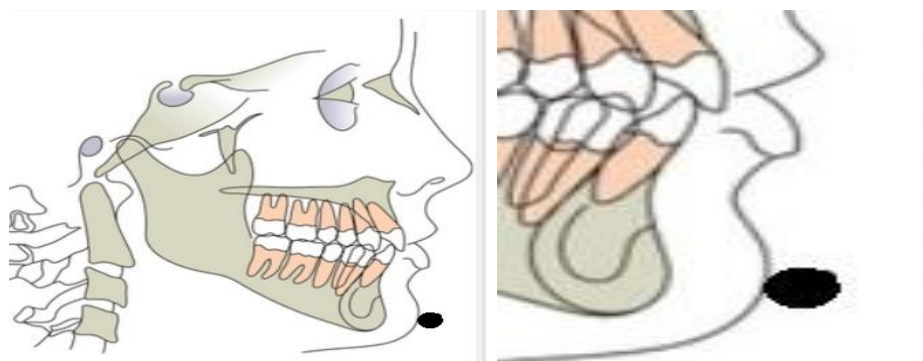


Fig. 1.44. Pogonion - graphic illustration (Audax)

CUTANEOUS GNATHION (Gns) – the point located between the anteriormost and the inferiormost points of the chin in mid-sagittal plane

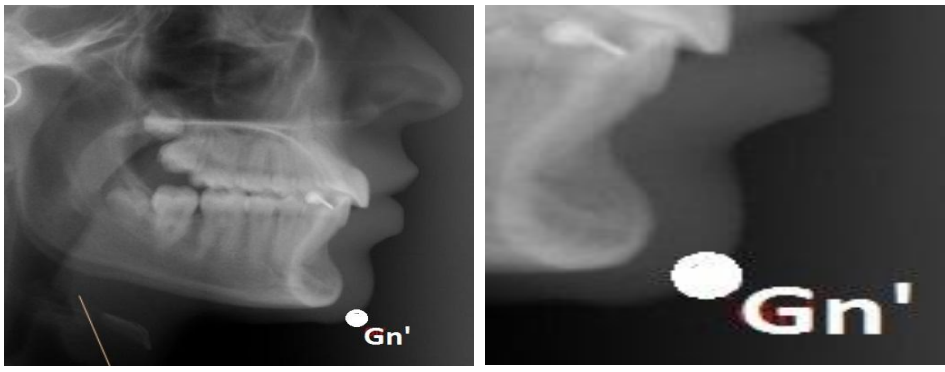


Fig. 1.45. Gnathion - radiographic appearance

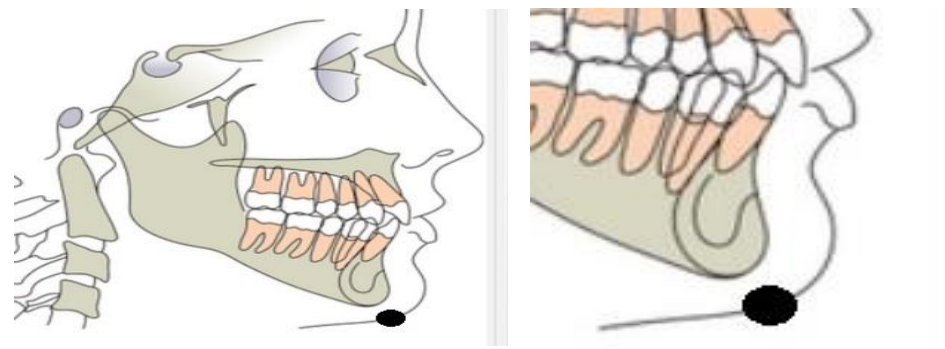


Fig. 1.46. Gnathion - graphic illustration (Audax)

2. PLANES AND AXES USED IN CEPH ANALYSIS

SN Plane: S-N
(Sella – Nasion)

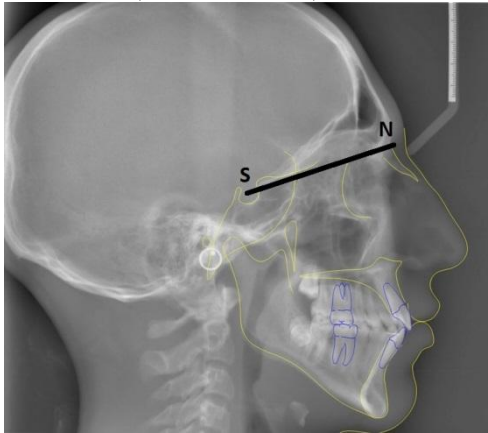


Fig. 2.1.

Frankfort Horizontal: Po-Or
(Porion – Orbitale)

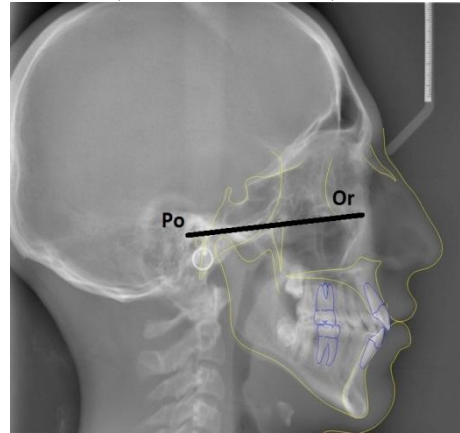


Fig. 2.2.

Palatal Plane: ANS-SNB
(Spina nasalis anterior - Spina nasalis posterior)

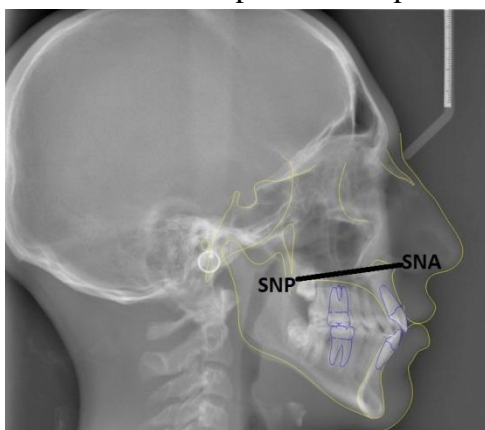


Fig. 2.3.

Mandibular Plane: Go-Me
(Gonion - Menton)

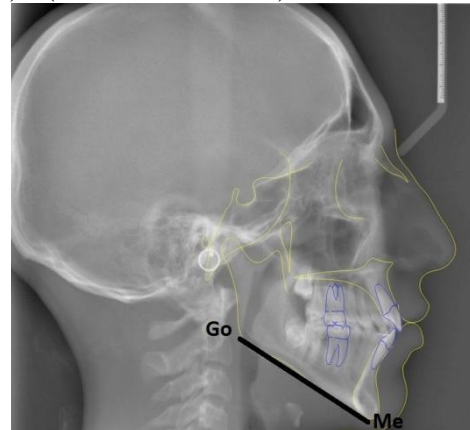


Fig. 2.4.

Occlusal Plane: the line that bisects the occlusion of the first molars and goes through the midpoint of the overbite or, if there is an open bite, through the space between the central incisors.

According to Ricketts: the line that goes through as many contact points between the occlusal surfaces of maxillary and mandibular teeth as possible; the line represents the linear half of the curve of Spee. [8,9]

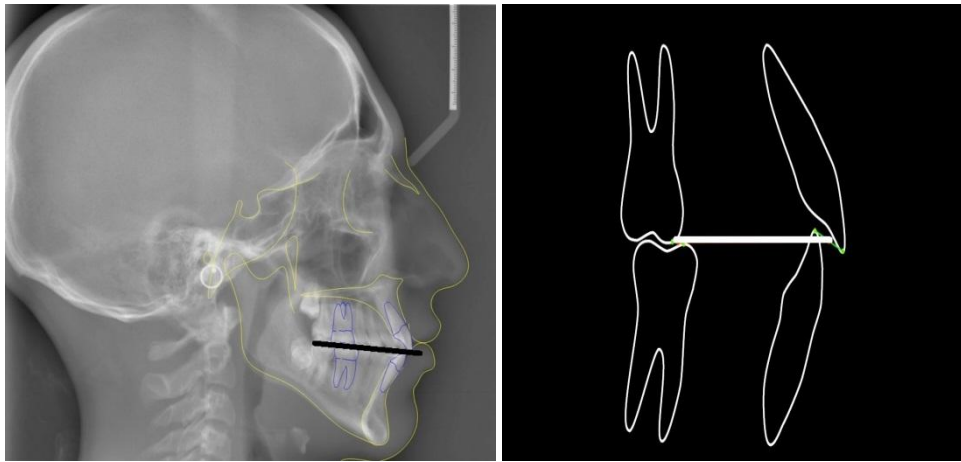


Fig. 2.5.

Facial Plane: N-Pog (Nasion – Pogonion) **Y Axis:** S-Gn (Sella – Gnathion)

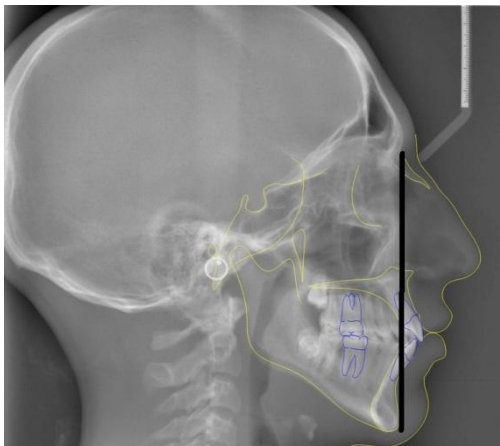


Fig. 2.6.

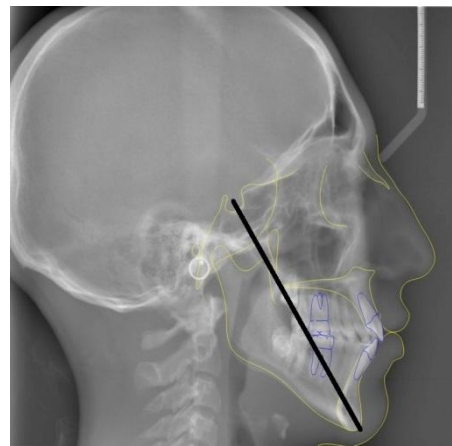


Fig. 2.7.

Steiner's Analysis

The cephalometric plane used in this analysis is **Sella – Nasion (S-N)**.

It assesses the position of the maxilla and the mandible at the cranial base and as compared to one another.

SNA. SNA angle assesses the position of the maxilla as compared to the cranial base in the sagittal plane. The normal value is **82° ± 2°**.

Higher values => protrusive maxilla

Lower values => retrusive maxilla

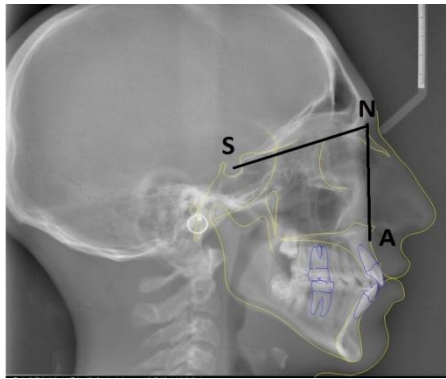


Fig. 1. ANS angle

SNB. SNB angle assesses the position of the mandible as compared to the cranial base in the sagittal plane. The normal value is $80 \pm 2^\circ$.

Higher values => protrusive mandible

Lower values => retrusive mandible

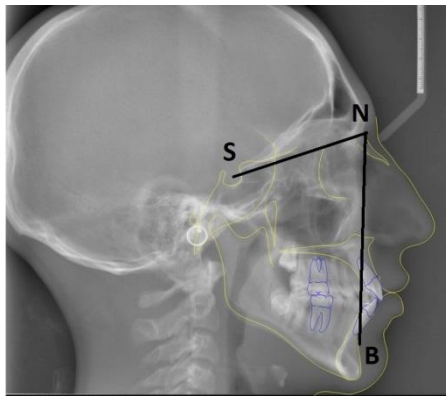


Fig. 2. SNB angle

ANB. ANB angle assesses the discrepancy of the mandible as compared to the maxilla in the sagittal plane. The normal value is of $2 \pm 2^\circ$.

The normal value is of $2 \pm 2^\circ$.

Higher values => Skeletal class II pattern

Lower or even negative values => Skeletal class III pattern

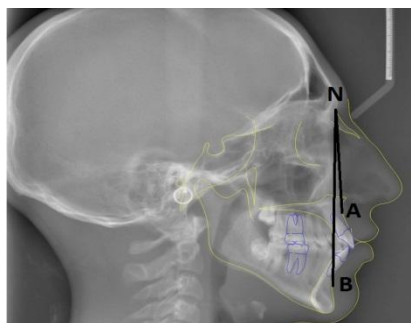


Fig. 3. ANB angle

Wits Analysis

It describes the relative position of the maxilla as compared to the mandible in the mid-sagittal plane. It is obtained by tracing two vertical lines from points A and B and measuring the distance between the intersection points on the occlusal plane.

When B point is located in front of A point, the result is a negative value.

According to Wits, the limit values of skeletal occlusions are the following:

- Skeletal class I = -3 mm up to +3 mm
- Skeletal class II = +4 mm and over
- Skeletal class III = -4 mm or less

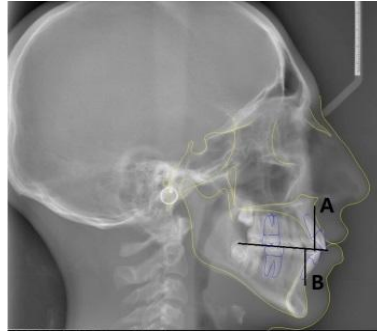


Fig. 4. Wits Analysis

Tweed Analysis

The drawing of a triangle, **Tweed's Triangle**, is the basis of this method. Planes used for Tweed's facial triangle :

- Frankfort's Horizontal Plane: Porion - Orbitale
- The mandibular plane: Gonion – Menton
- The axis of the mandibular incisors – which goes through the incisal edge and through their apex

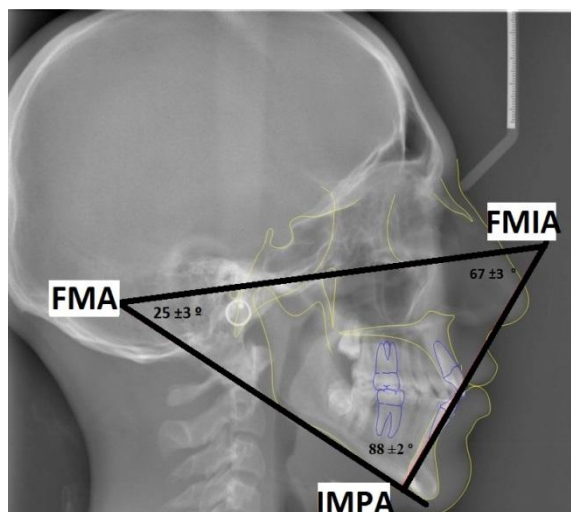


Fig. 5. Tweed's Triangle

FMA Angle:

- Allows the assessment of the skeletal growth pattern on the vertical line
- Normal value: $25 \pm 3^\circ$
- When the value is between the normal limits, the growth pattern is **normal divergent**
- When the value is higher than 28° , the growth type is **hyperdivergent**
- When the value is lower than 22° , the growth type is **hypodivergent**

IMPA Angle:

- Allows the assessment of the position of the mandibular incisors as compared to the bony base.
- The average value of the angle is of $88 \pm 2^\circ$
- Value higher than $90^\circ \Rightarrow$ the incisors are proclined
- Value lower than $86^\circ \Rightarrow$ the incisors are retroclined

FMIA Angle:

- Allows the assessment of the position of the mandibular incisor in the facial outline
- The average value of the angle is of $67 \pm 3^\circ$
- Value higher than $70^\circ \Rightarrow$ the incisors are retroclined
- Value lower than $64^\circ \Rightarrow$ the incisors are proclined

Inter-incisal Angle

- Expresses the reciprocal incisor angulation without any reference to the bony base.
- Normal value = 130°
- Value higher than $130^\circ \Rightarrow$ the incisors are retroclined
- Value lower than $130^\circ \Rightarrow$ the incisors are proclined

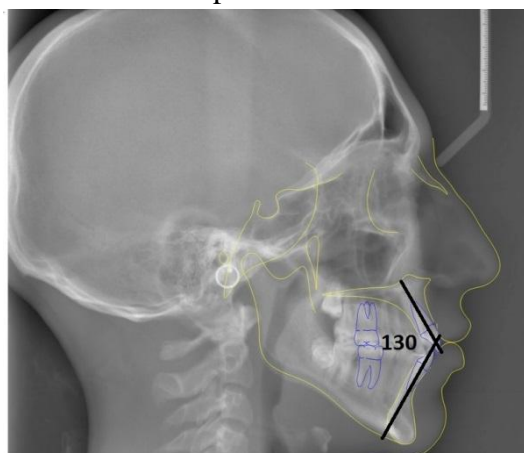


Fig. 6. The inter-incisal angle

Jarabak Analysis

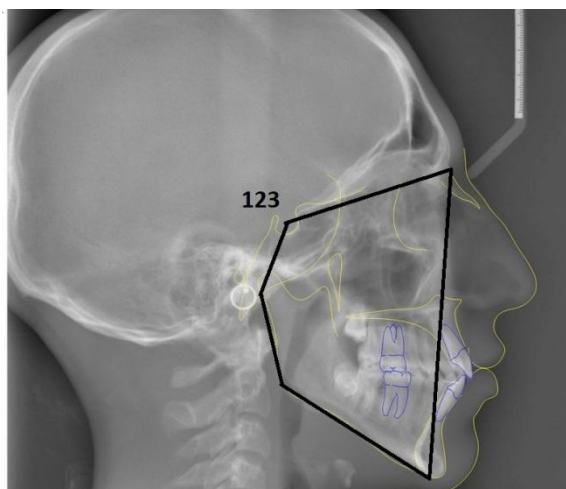


Fig. 7. The angle of the sella turcica

It offers information about facial growth and mandibular rotation.

The angle of the sella turcica (Ar-Se-N)

It shows the location of the mandibular fossa and of the condyle

Normal value: 123°

Value higher than 123° => Skeletal class II pattern

Value lower than 120° => Skeletal class III pattern

Aesthetic Analysis

The nasolabial angle – the angle formed by the tangent to the columella and the tangent to the upper lip

Normal value: 102°

Higher values => retruded lips

Lower values => protruded lips

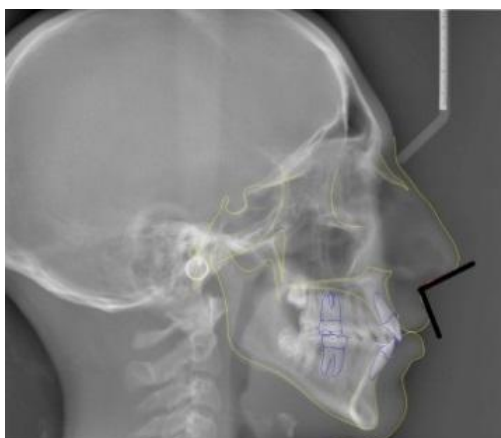


Fig. 8. The nasolabial angle

Upper lip to E-line (Pn-Pog)

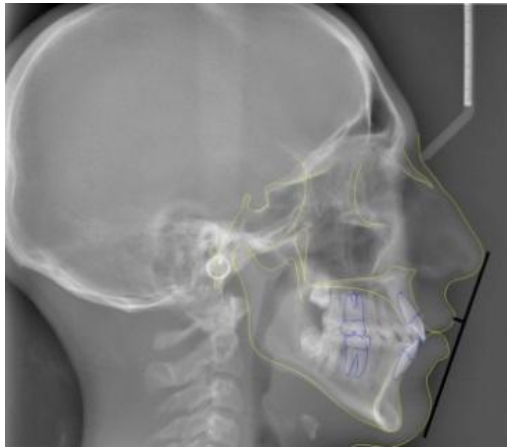


Fig. 9. Upper lip to E-line

Normal values: -4 ± 2 mm

Higher values \Rightarrow protruded upper lip

Lower values \Rightarrow retruded upper lip

Lower lip to E-line (Pn-Pog)

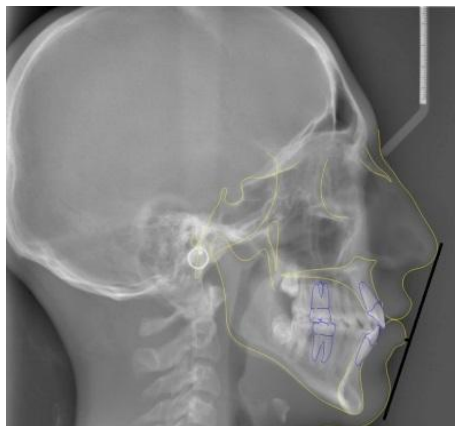


Fig. 10. Lower lip to E-line

Normal values: -2 ± 2 mm

Higher values \Rightarrow protruded lips

Lower values \Rightarrow retruded lips

9. DIGITAL CEPHALOMETRIC ANALYSIS

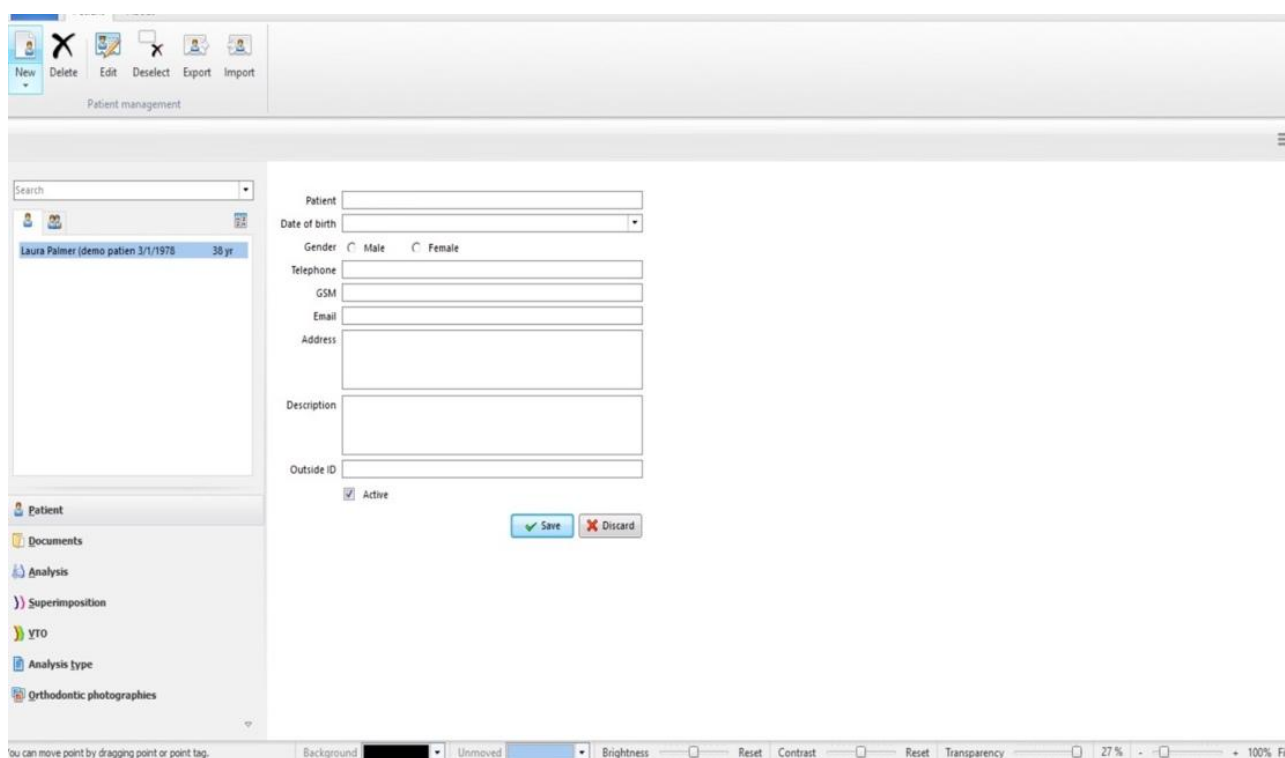
In order to simplify the diagnosis and treatment plan step, as well as the data storage step, various software types have been launched. They allow not only the cephalometric analysis, but also the analysis of the model and offer the possibility to make predictions regarding growth.

Audax Ceph

Audax Ceph allows digital cephalometric analysis, superimpositions and orthodontic treatment planning [10].

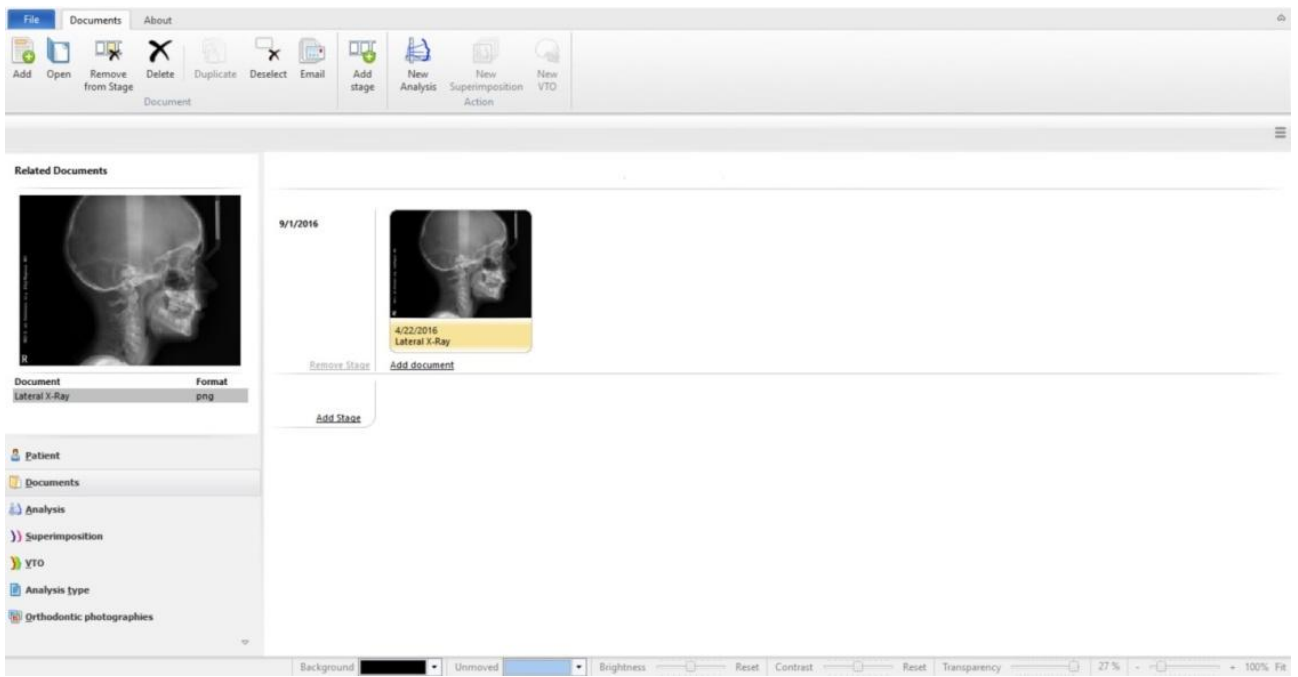
Steps:

1. The first step in digital analysis is adding the personal data of the new patient.

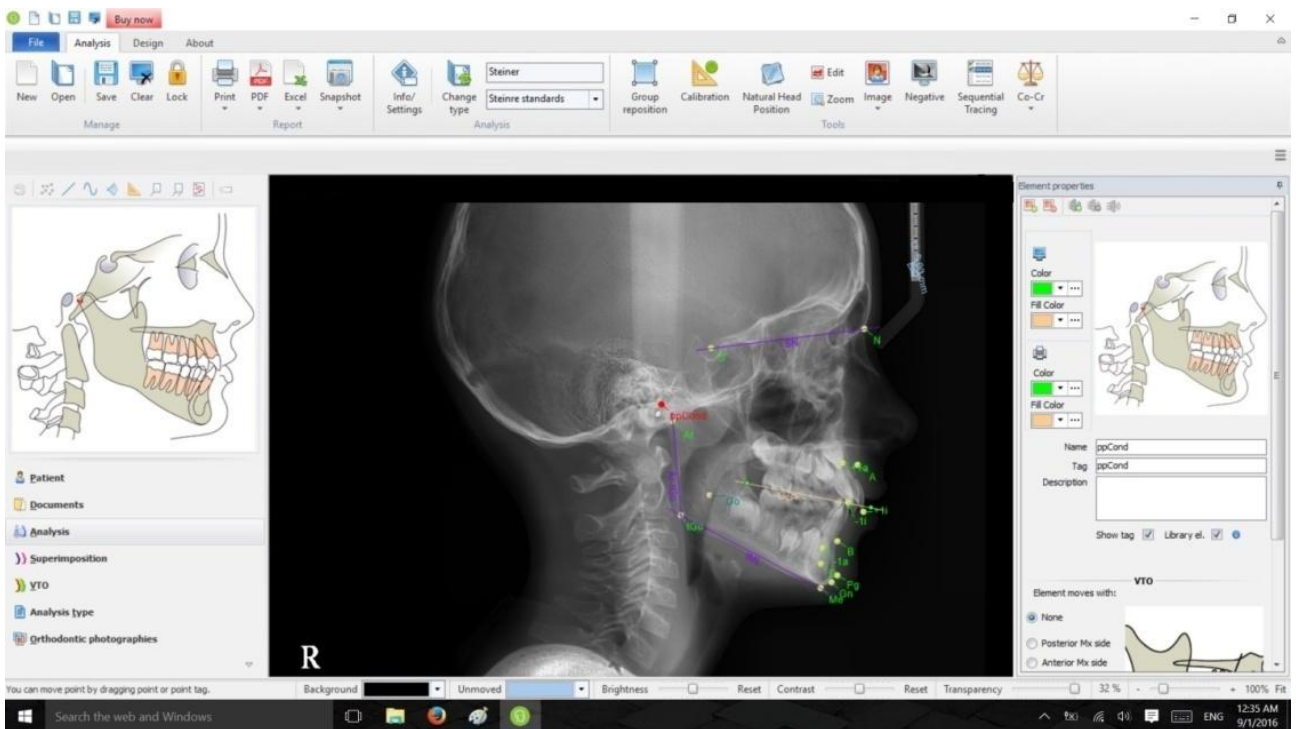


The screenshot displays the Audax Ceph software interface. At the top, there is a menu bar with options: New, Delete, Edit, Deselect, Export, and Import. Below the menu bar is a search bar and a list of patients. The first patient listed is "Laura Palmer (demo patient 3/1/1978 38 yr)". To the right of the list is a form for adding a new patient. The form includes fields for Patient name, Date of birth, Gender (Male/Female), Telephone, GSM, Email, Address, Description, and Outside ID. There is also a checkbox for "Active". At the bottom of the form are "Save" and "Discard" buttons. The bottom of the interface shows a status bar with various settings like Background, Unmoved, Brightness, Contrast, and Transparency.

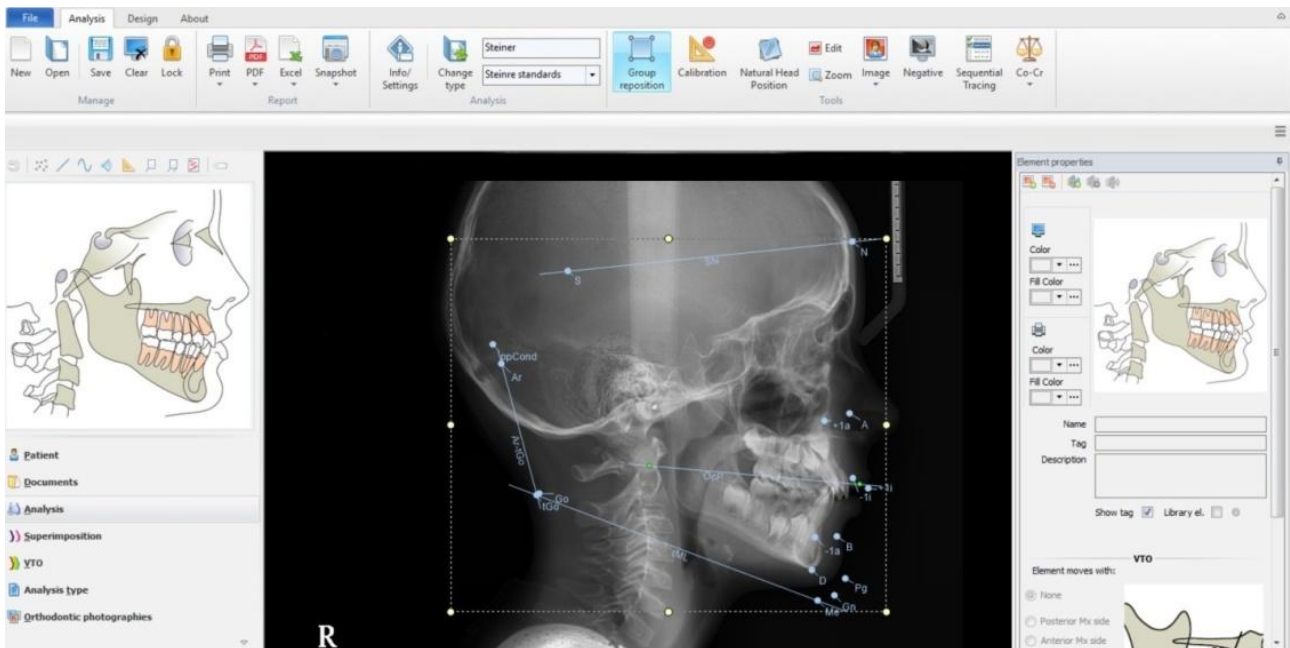
After having added the new patient, one adds his/her documents: teleradiograph, PA radiograph, orthodontic photos, photos of the model, etc. One selects *New Analysis* to begin the digital cephalometric analysis.



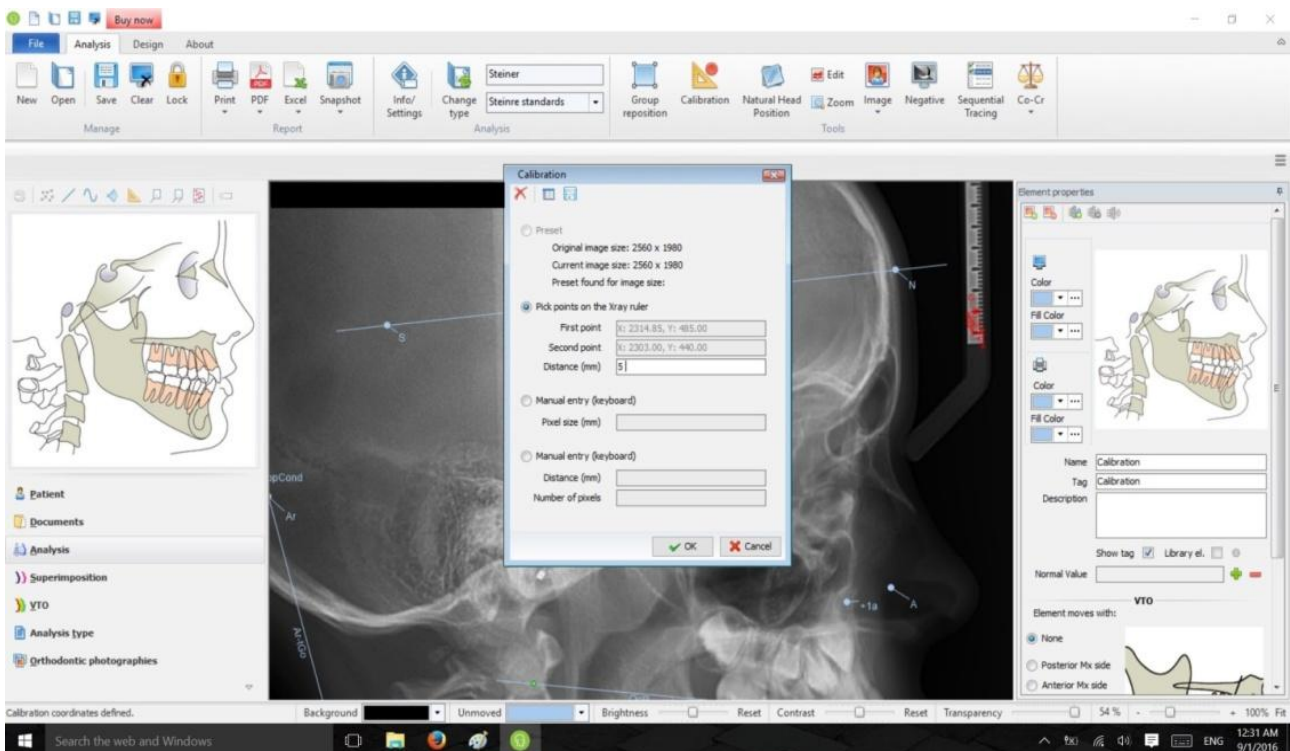
2. One selects the desired type of cephalometric analysis. In this case, we have opted for Steiner's Analysis.



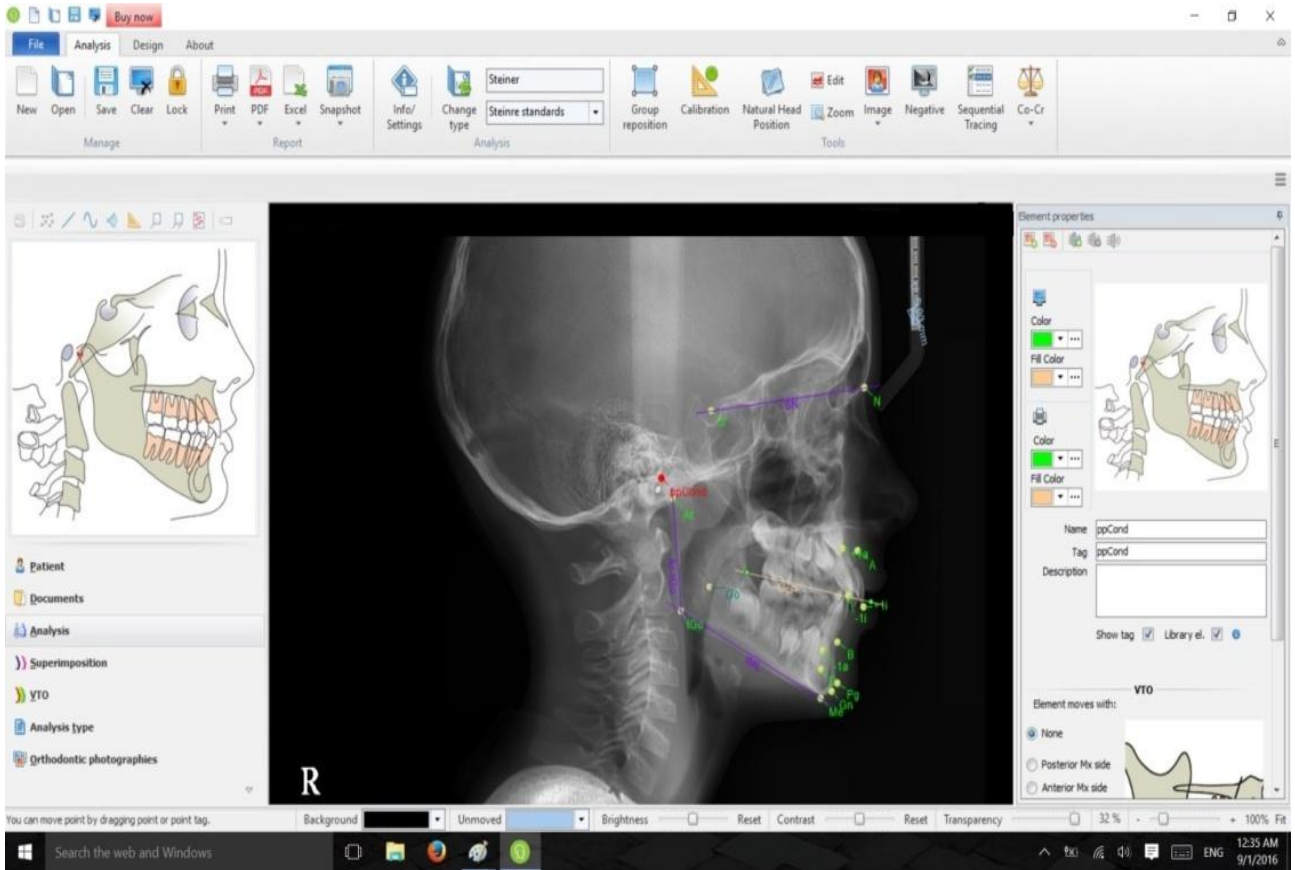
3. After having selected the desired cephalometric analysis, all the landmarks that are necessary for performing the analysis will appear and will group in order to be as close to the ideal position as possible.



4. Calibration is an important step in turning the results from pixels to millimeters.

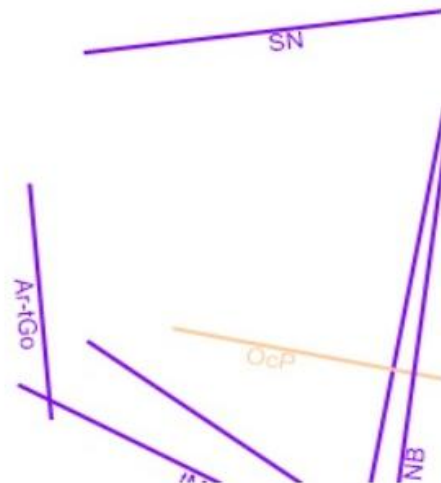
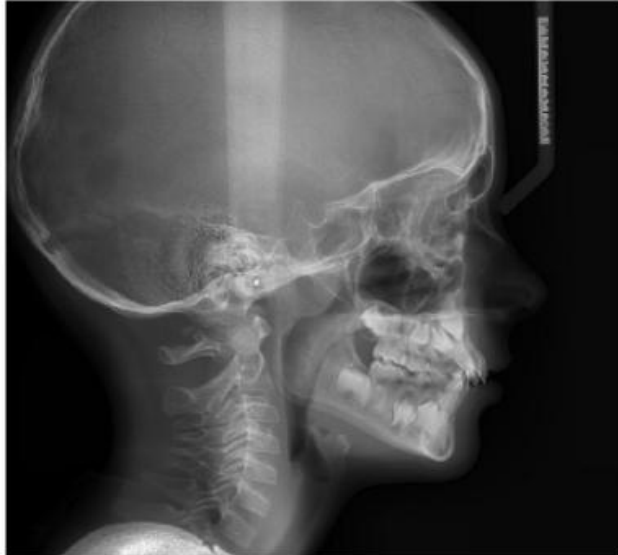

5. One precisely positions the cephalometric landmarks that are needed for the analysis.



6. The results of the cephalometric analysis

Patient	Status
	Date of birth 10/3/2006
	Date of image 4/22/2016
	Analysis type Steiner



MEASUREMENT	NORMAL VALUE	VALUE	DIFFERENCE	BIAS
-------------	--------------	-------	------------	------

Other

MEASUREMENT	NORMAL VALUE	VALUE	DIFFERENCE	BIAS
Angle SNA	85	80	-5	•
Angle SNB	79	76	-3	
ANB	3	4	1	•
SND	77	72	-4	•••
Interincisal angle	140	127	-13	•
SN/OcP	14	18	4	
SN/GoGn	30	42	12	
+1/NA	22	26	4	
+1/SN	103	106	3	
-1/NB	25	22	-3	
+1i/NA mm	4	3	-1	
-1i/NB mm	4	2	-2	
Pg/NB mm	N/A	2	N/A	
Holdaway ratio %	1	126	125	•••
S-Lpoint mm	51	39	-12	
S-Epoint mm	22	22	0	

10. DIAGNOSIS RESULTS

SAGITTAL PLANE

1. Skeletal

Steiner's Analysis – ANB angle

- The normal value is of $2^\circ \pm 2^\circ \Rightarrow$ **Skeletal class I**
- Higher values \Rightarrow **Skeletal class II**
- Lower or even negative values \Rightarrow **Skeletal class III**

Wits Analysis

- Skeletal **class I** = -3 mm up to +3 mm
- Skeletal **class II** = +4 mm and over
- Skeletal **class III** = -4 mm or less

2. Dental (according to Angle)

- **Class I** – the canines and the molars are in a normal occlusion
- **Class II** – the canines and the mandibular molars are in a distalized position
- **Class III** – the canines and the mandibular molars are in a mesialized position

3. Soft tissue

- **Class I** – the lips are in antero-posterior harmony and the menton is well positioned in the profile
- **Class II** – the soft tissue subnasal part is prominent as compared to the soft tissue mandibular part (convex profile)
- **Class III** – the soft tissue part is located behind the soft tissue mandibular part (concave profile)

VERTICAL PLANE

1. Skeletal

Tweed Analysis – FMA Angle (Normal value: $25 \pm 3^\circ$)

- When the value is between the normal limits, the growth pattern is **normal divergent**
- When the value is higher than 28° , the growth pattern is **hyperdivergent**
- When the value is lower than 22° , the growth pattern is **hypodivergent**

2. Dental

- Normo-occlusion
- Supraocclusion
- Infraocclusion

3. Soft tissue

- **Hyperdivergent:** slight subnasal concavity, lip incompetence, shallow labiomentental groove
- **Hypodivergent:** pronounced subnasal concavity, protruded lips during occlusion, deep labiomentental groove, reduction of the lower section
- **Mesodivergent:** harmony between the subnasal concavity and the labiomentental groove and harmonious lips.

11. CBCT IMAGING IN ORTHODONTICS

CBCT is an accurate imaging technique which produces images that ease the diagnosis. All the conventional procedures before it, either intra- or extraoral, had a number of limitations, as the image they rendered was in 2D. CBCT use in orthodontics is different: precise diagnosis of dental inclusion, of hyper- or hypodontia, highlighting articular or periodontal pathology, assessing bone density, bone resorption and/or radicular resorption. CBCT can offer extremely important information in the case of congenital malformations, skeletal anomalies which should undergo orthognathic surgery, or in assessing the airways. When recommending this investigation, the doctor must consider the ratio between the benefit of obtaining the diagnosis and the amount of radiation the patient receives.

The three planes used in this investigation are: coronal, sagittal and axial, alongside the 3D rendition.

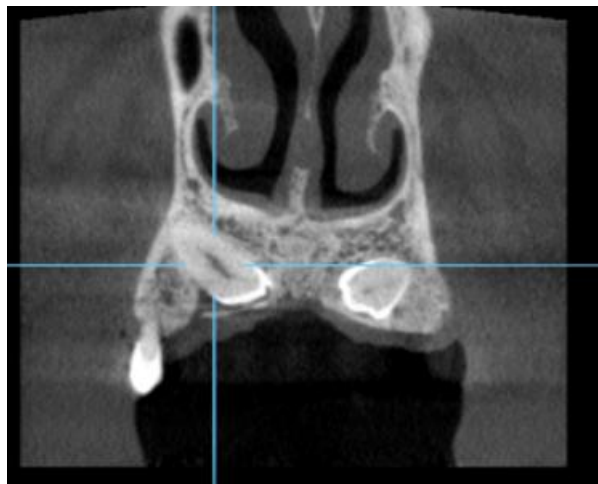


Fig. 1. Coronal section – CBCT investigation in a case of bilateral inclusion of maxillary canines

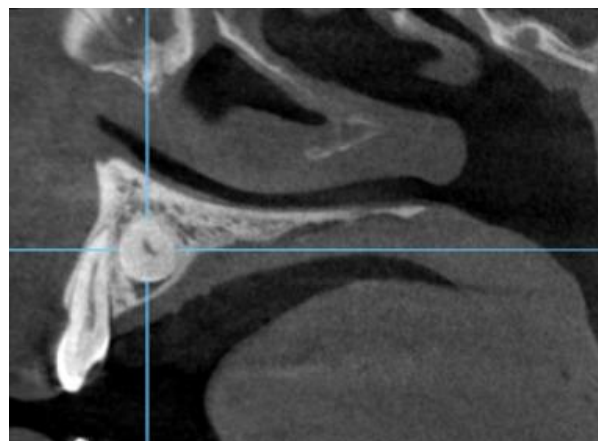


Fig. 2. Sagittal section – CBCT investigation in a case of bilateral inclusion of maxillary canines

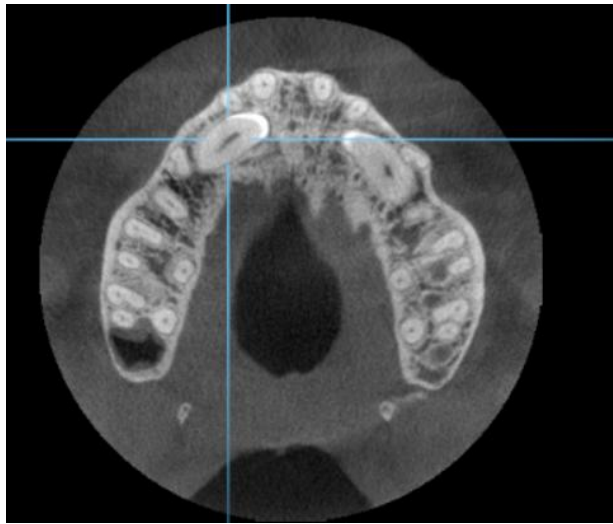


Fig. 3. Axial section – CBCT investigation in a case of bilateral inclusion of maxillary canines

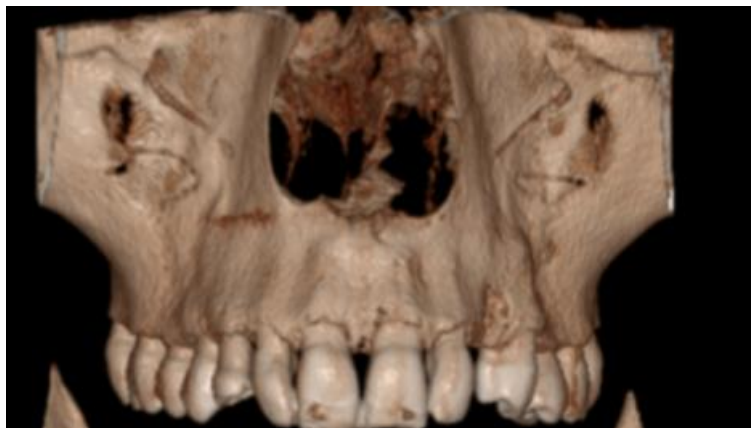


Fig. 4. Axial section – CBCT investigation in a case of bilateral inclusion of maxillary canines, with the persistence of a temporary canine on the arch (5.3)

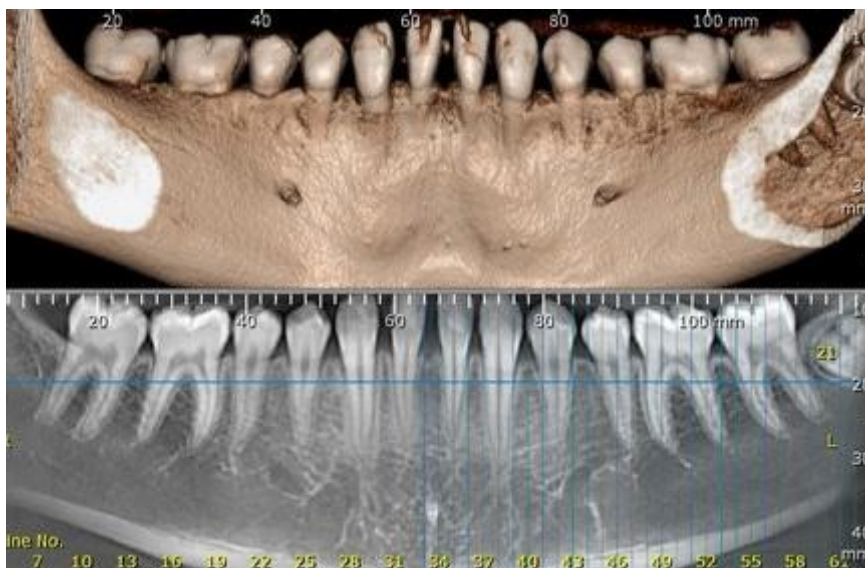


Fig. 5. CBCT investigation – congenital absence of mandibular lateral incisors

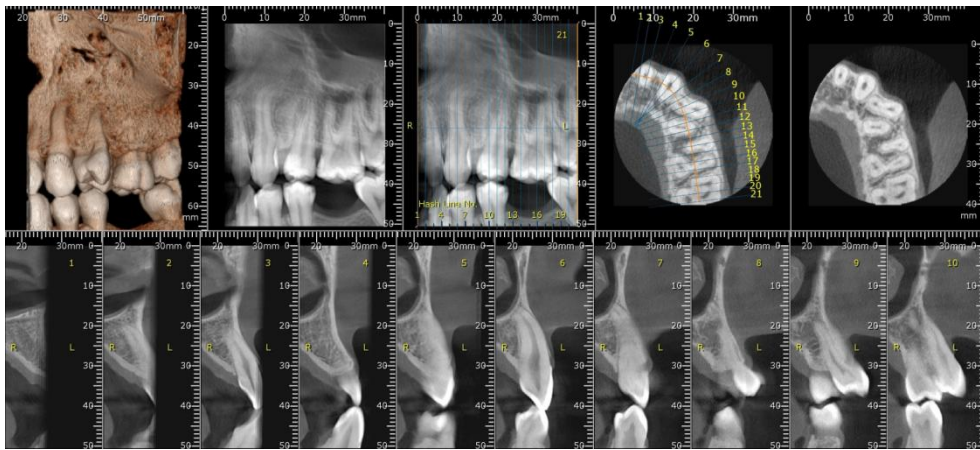


Fig. 6. CBCT investigation - transposition

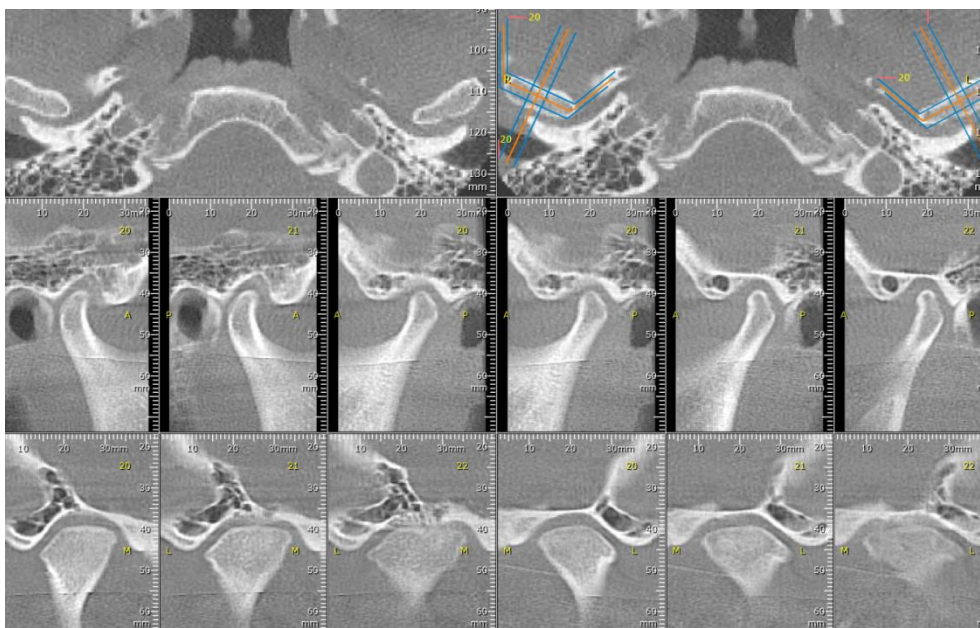


Fig. 7. CBCT of the temporomandibular joint, highlighting the changes at the level of the condyle

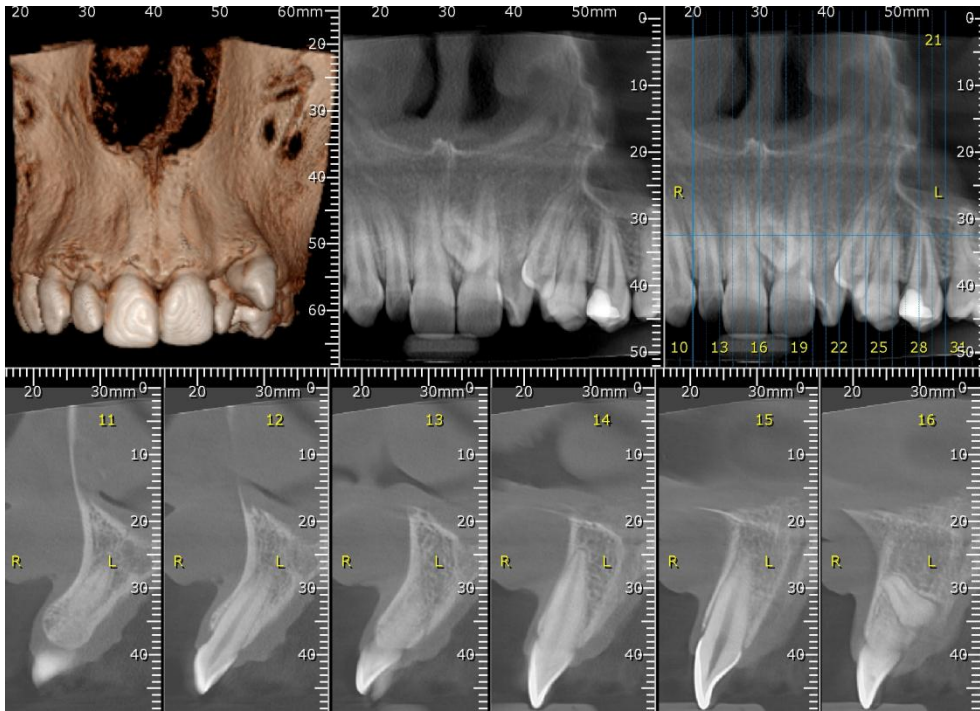


Fig. 8. CBCT investigation highlighting the presence of a mesiodens

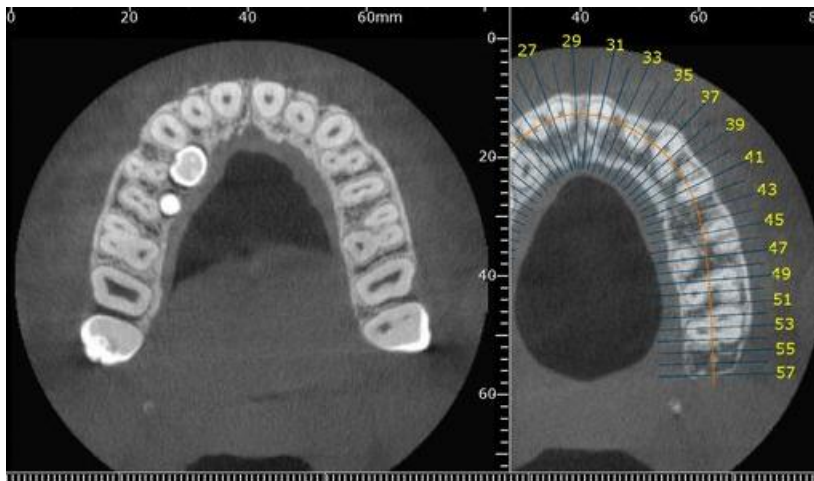


Fig. 9. CBCT investigation highlighting the presence of some extra teeth (axial section)

12. REMOVABLE APPLIANCES

In this category we can include the orthodontic appliances which are applied on the dental arches with the help of some retention means (clasps or labial bows). Removable appliances generate active orthodontic forces, thus causing changes at the level of the dentoalveolar process [13]. The most representative are upper and lower plates.

Upper plates

Components (fig. 1)

- acrylic base plate
- retention components (clasps)
- active components (screw, labial bow, vestibular spring, secondary springs)

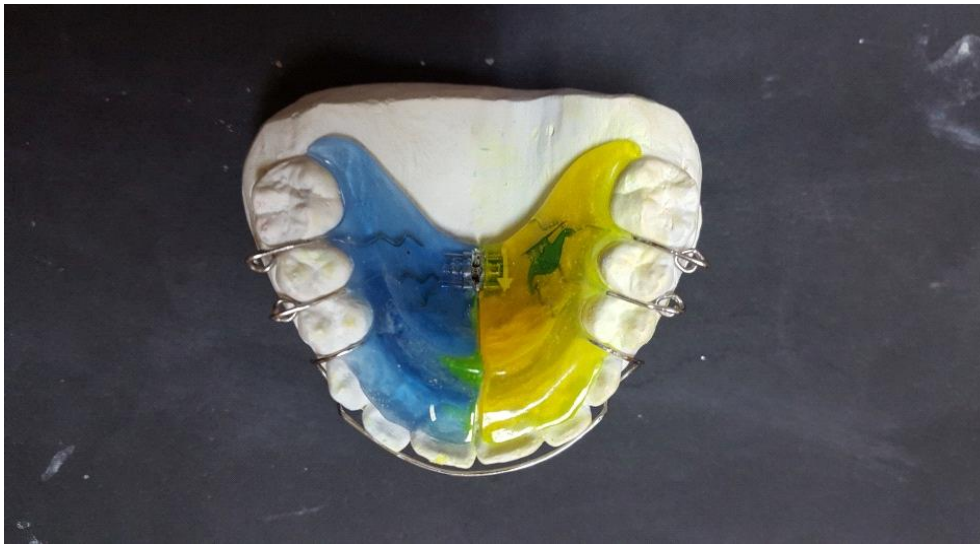

Fig. 1. Upper plate: medially split acrylic plate, with a screw, labial bow, four Stahl clasps

The acrylic base plate

It lies on the palate and all the other components of the appliance are fixed on it. It follows the outline of teeth at the level of the cemento-enamel junction, up to the last molar on the arch, and its concavity is directed towards the posterior part.

The base of the acrylic plate can be split in several ways:

- on the median line – with the help of the screw, the transversal maxillary expansion is carried out (narrow maxilla)
- transversally – by using the screw, the incisors and canines will be directed towards the anterior part (negative overjet)
- Y-shaped – by using a special screw, radial expansion is carried out (micrognathia)

- L-shaped – the lateral expansion of one hemiarch is carried out when the screw is placed on the long side of the L (unilateral crossbite); the distalization of a group of teeth is carried out when the screw is placed on the short side of the L (group mesial positioning = in the situation where the primary canine has been prematurely lost, the mesialisation of the premolars takes place, the space of the permanent canine being occupied).

The active components

- ***The orthodontic screw*** – is made up of a retentive portion which is incorporated into the acrylic plate; the screw proper has a rod with an orifice through which the appliance is activated with the help of an activation key. There is a marked arrow which shows the direction of the activation; through the screw, intermittent orthodontic forces are exerted onto the dentoalveolar arches, leading to expansion.

- ***The labial bow*** – is made of 0.6-0.7 mm Wieplaw wire

It is made up of two clasps which get out of the acrylic plate between the canines and the first premolars, two activation clasps in front of the canines and an active horizontal part which comes in contact with the incisors. The labial bow has several effects: retrusion of the incisors, derotation of the incisors together with the secondary springs that are located palatally in the plate (making a force couple), egression of the incisors if it is placed closer to the cemento-enamel junction, ingression of the incisors if it is placed closer to the incisal margin, it keeps the lip away in the case of lip hypertonia. It may contain a finger bend instead of the activation clasp for ectopic canines. It has an effect in the retrusion and distalization of the canines.

- ***Secondary springs***

- the springs in the shape of an 8 or of the letter S cause the labial movement of teeth or their derotation together with the labial bow

- the springs in the shape of the letter C – prevent the sagittal movement of a tooth or help in closing a diastema

- the spring resembling the clubs shape allows the closing of a diastema or the creation of a gap between two teeth (when the clasps are opened)

- the spring in the shape of a mushroom allows the labial movement of the entire frontal group of teeth

Acrylic plates are active mechanic appliances to which one can add some ***functional elements***, that is, elements which influence the muscles: the inclined plane, the bite plane and the lingual shield.

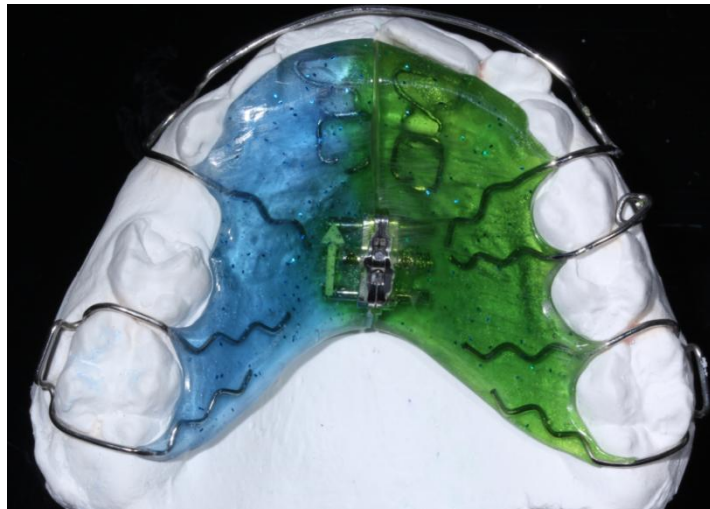


Fig. 2. Acrylic plate with springs in the shape of an 8 for 1.1. & 2.1.

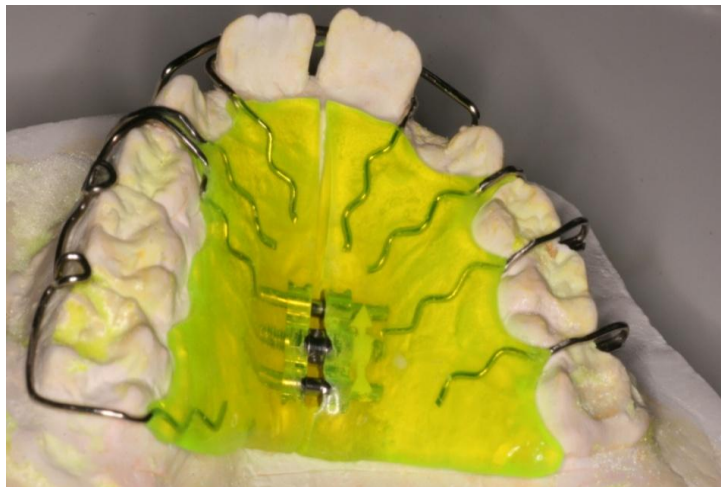


Fig. 3. Plate with two C-shaped springs for closing the diastema

a. The inclined plane

The anterior palatal area of the plate is no longer concave. The acrylate takes the form of a ramp which makes an angle of 60 degrees with the occlusal plane. The purpose of this inclined plane is to allow the mandible to glide towards anterior, which is why it is used in distalised occlusions (mandibular retrognathism) and acts upon the propulsive muscles of the mandible.

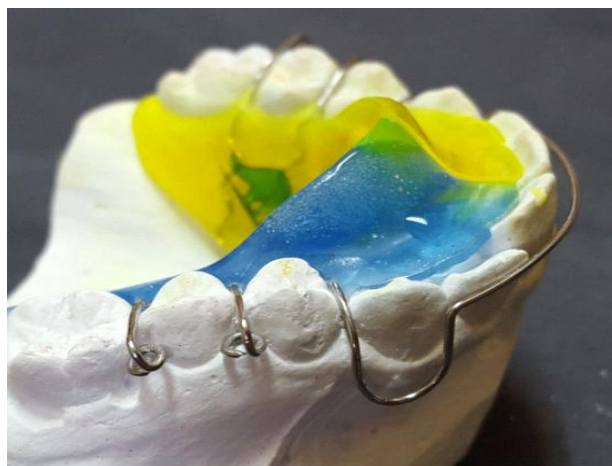

Fig. 4. Plate with an inclined plane

b. The anterior bite plane

It is also located in the anterior part of the plate, behind the upper incisors. It is of a certain thickness and it forms a 90 degrees angle with the occlusal plane. During occlusion, its thickness causes disocclusion in the lateral area, which means it acts upon elevator and depressor muscles of the mandible. Its purpose is to cause the intrusion of the mandibular incisors and the egression of the premolars and molars. This is why it is recommended in the case of a deep bite [13].

The clasps

- are used as anchoring elements and do not have an active role in the orthodontic therapy (fig. 3)
- there are several types of clasps: Adams, Schwarz, Stahl, Jackson etc.

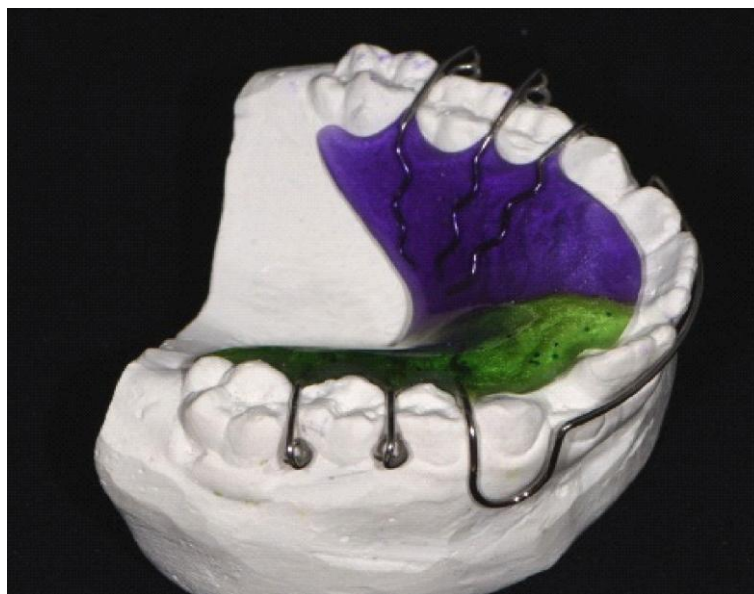

Fig. 5. Stahl clasps

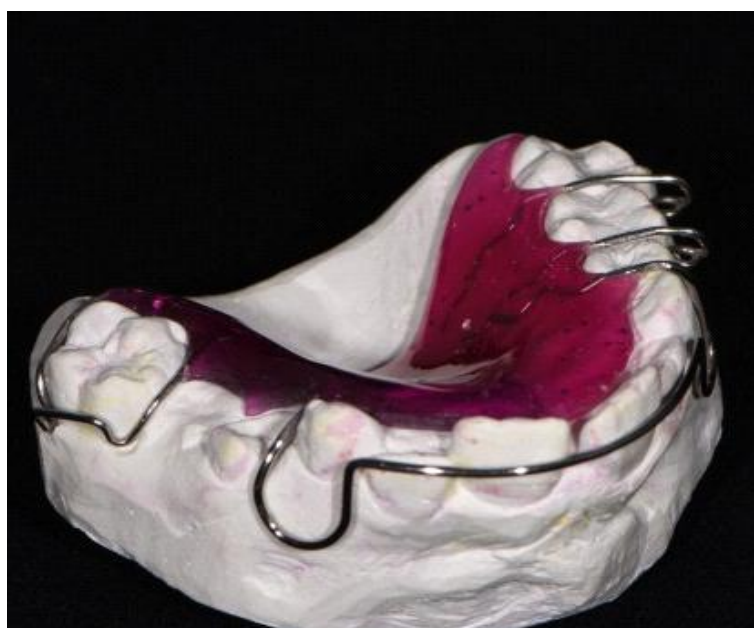

Fig. 6. Acrylic plate with Adams clasps

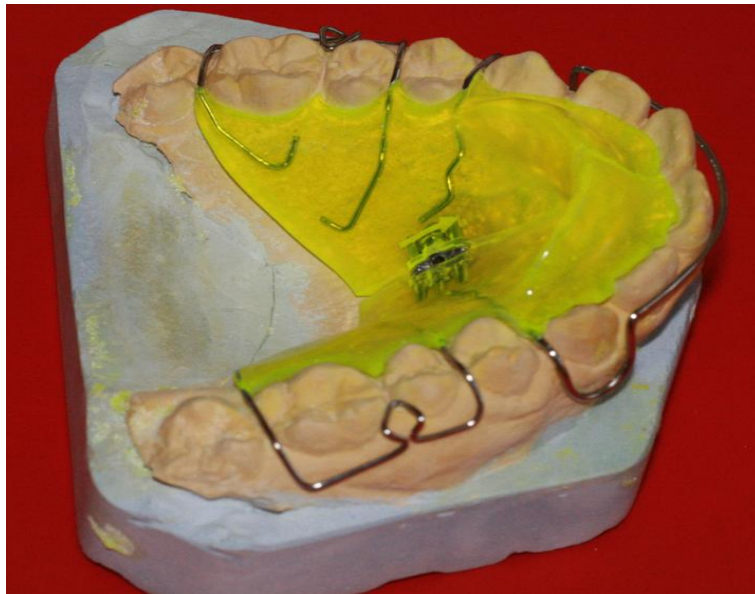

Fig. 7. Acrylic plate with Schwarz clasps

Adams clasps are used to anchor isolated teeth.

Schwarz clasps (simple or double) are used for the permanent teeth and are anchored between teeth in front of the premolars or molars, above the contact points. Their shape is that of an arrowhead or of clubs.

Stahl clasps are more used in primary dentition or primary mixed dentition (primary molars). In permanent dentition, they are used for the mandible, as they are less voluminous.

As anchoring systems, one can also use *posterior biteblocks*. These are especially employed in the case of crossbite, because, if activated with the screw, they have a better effect on the lateral expansion (they include teeth and alveolar processes altogether). They are used in situations where the occlusion has to be uplifted – frontal negative overjet, negative occlusion. Sometimes, they may prove useful in intruding the molars in the case of open bite.

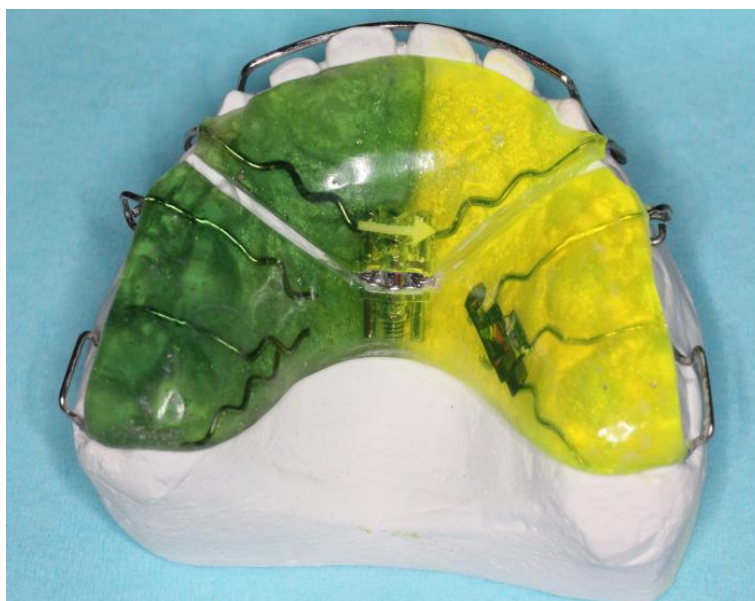

Fig. 8. Plate with posterior biteblocks & screw for sagittal expansion, used in the case of negative overjet.

The upper plate may also contain *paralingual extensions* made of acrylate. They are recommended when the mandibular incisors are not crowded, but, as the maxillary expands, the lateral areas of the mandible need to be expanded too.

Manufacturing stages of the removable appliances

- Manufacturing the passive components (clasps) and the active ones (labial bow and secondary springs) from Wipla wire on the working model
- Placing the orthodontic screw
- Applying the acrylate using the *salt and pepper* technique
- Adding some functional elements made of acrylate (if necessary)
- Sectioning the acrylic plate and finishing the appliance so as to make its external surface have a mirror-like shine

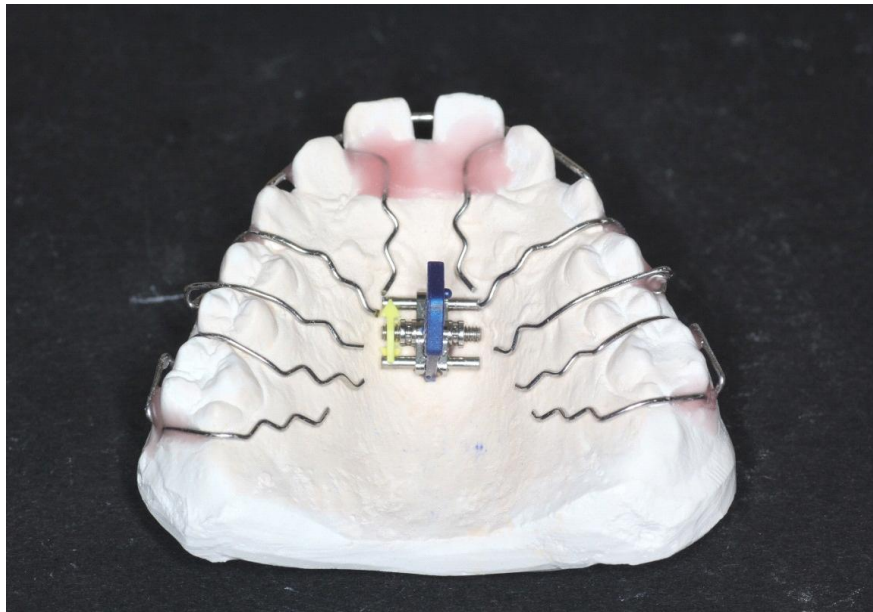


Fig. 9. Manufacturing the metallic components and positioning the screw (the elements are fixed with wax on the working model so as not to move)

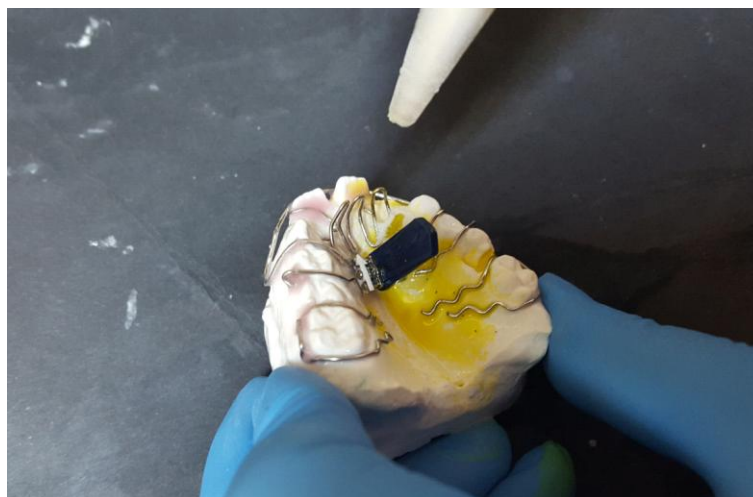

Fig. 10. Applying the acrylate using the *salt and pepper* technique

c. The lingual shield

The lingual shield is the third functional element which can be added to the upper plate; it is used in correcting infantile swallowing and the open bite caused by this vicious habit respectively. It may be made of acrylate, but most often it is made of Wipla wire.

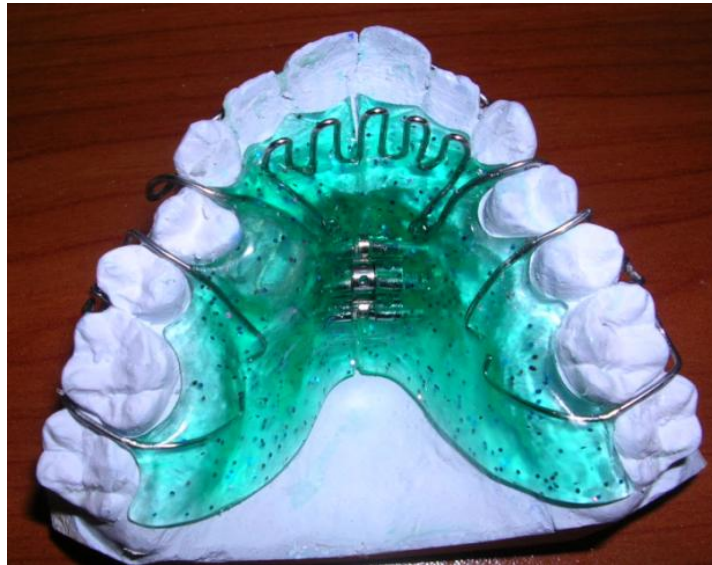

Fig. 11. Upper plate with lingual shield

Manufacturing stages

The lingual shield is made up of 3-4 loops of Wipla wire; it is most frequently made by using crampon pliers, but some other special tool may also be used. The lateral arms of the shield must be adapted so as to integrate in the acrylate.

The lingual shield may also be welded to two orthodontic rings, which are cemented in the oral cavity (fixed interception appliance), in the case of uncooperative patients.

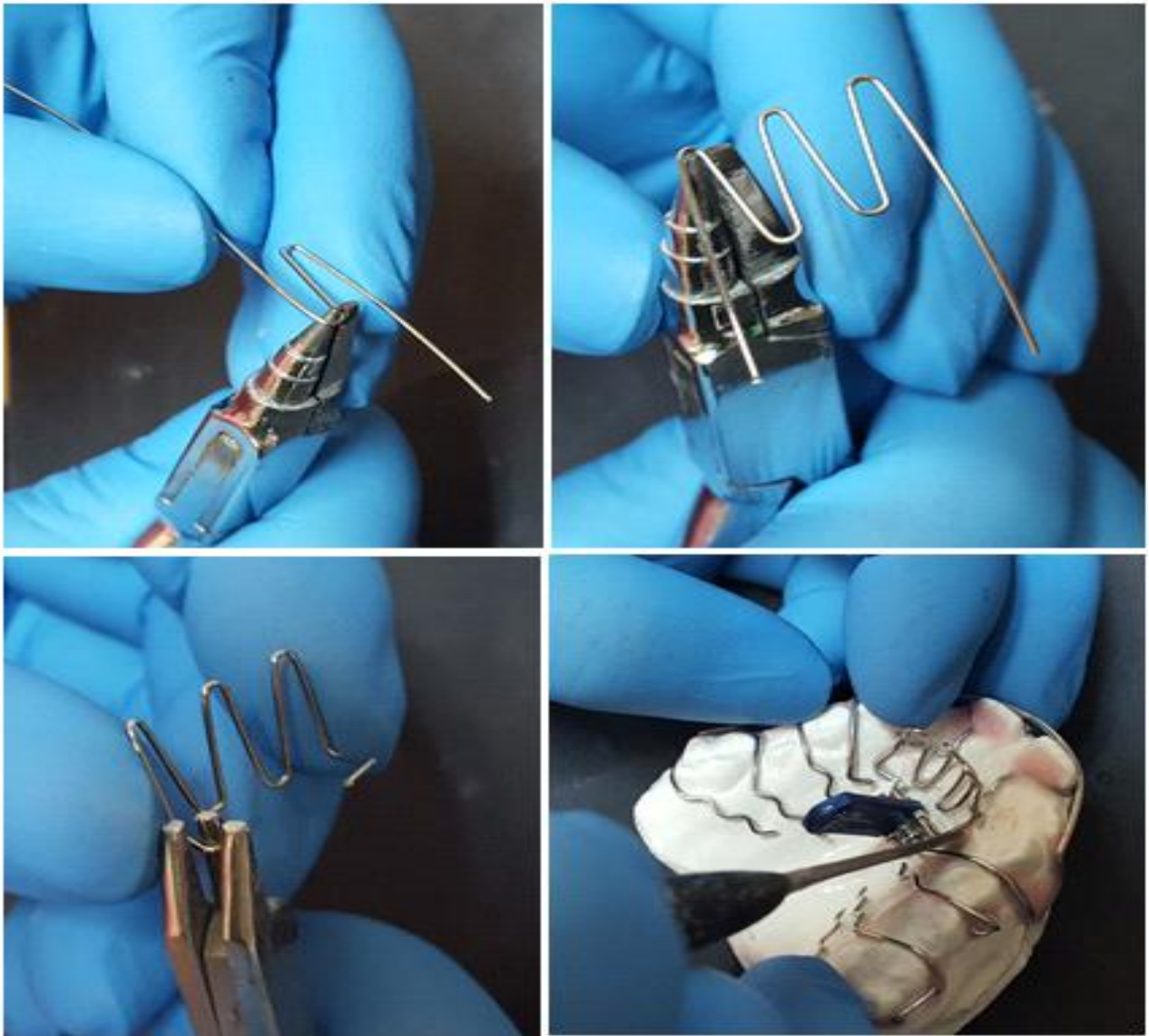


Fig. 12. Lingual shield manufacturing stages: making of the loops and of the lateral arms, fixing the shield on the working model so as to integrate it in the acrylic plate of a removable appliance.

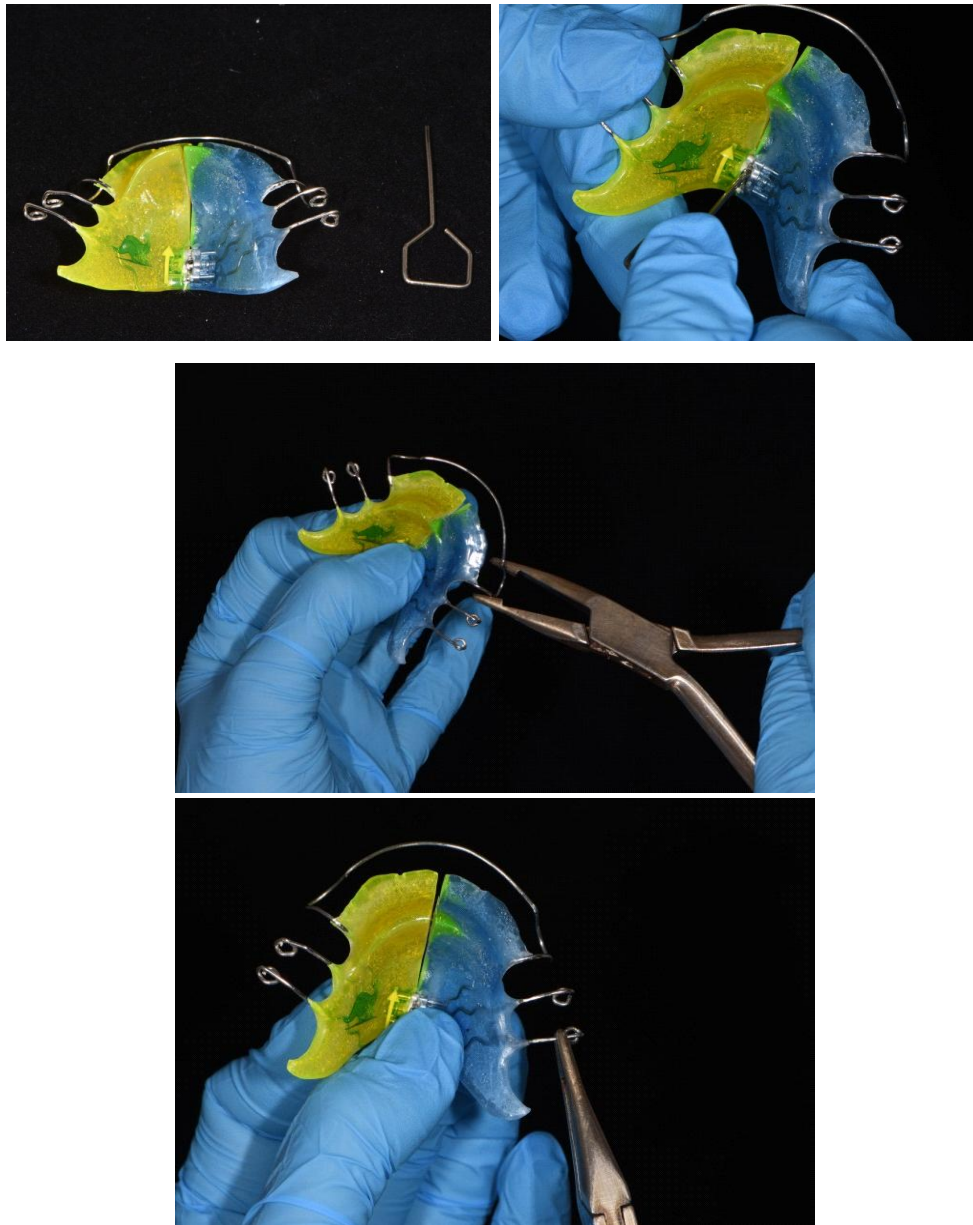


Fig. 13. Ways of activating a removable appliance: activating the screw with a key, activating the labial bow by tightening the activating loops, adjusting a Stahl clasp

Lower plates

A lower plate can be split on the median line, it has a screw and (usually) Stahl clasps. It also contains a labial bow and secondary springs (in the shape of an 8 or of the letter S).

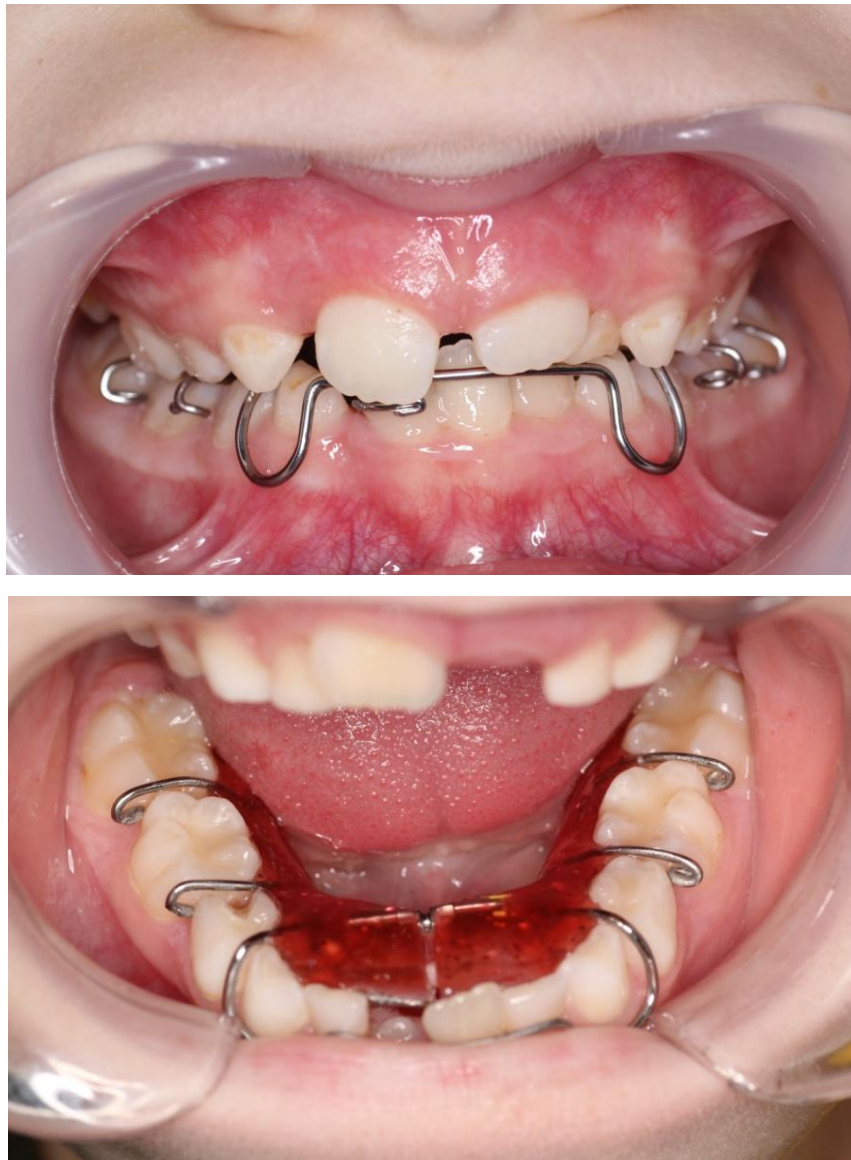


Fig. 14. Patient with lower plate

The advantages of removable appliances

1. They are not voluminous and it is easier to wear them
2. They are recommended when there is an occlusal discrepancy between the maxilla and the mandible
3. Functional elements to act upon the muscles may be added to them

The main disadvantage would be that the clasps (especially the Stahl ones) may distort or suffer a rupture due to repeated removal of the appliance from the oral cavity; in late mixed dentition (when the premolars begin to erupt), they may block the eruption of the premolars, and they often need to be removed; this affects the stability of the appliance.

13. FUNCTIONAL APPLIANCES

There is a wide range of functional appliances. The most used are the following:

- Andresen activator
- Balters bionator
- Frankel appliance
- Twin-Block appliance
- Herbst appliance
- Trainer systems /Myobrace

Andresen Haupl Activator

Maintaining the appliance in the oral cavity is possible by closing the mouth (muscle contraction), which turns the appliance from a passive into an active one. As it has an effect on muscles, it turns into a **functional appliance**, taking over, eliminating or directing the natural muscular forces. These forces transmit to teeth and to bony bases as well [12, 13,14].

Components

The acrylic component is made up of two parts: an upper one and a lower one.

The upper plate comprises the palatal sides of all teeth and its concavity is distally oriented.

The lower part is designed on the lingual side of the alveolar process, without extending too much in the sublingual fossa, so as to avoid retention.

The two parts are united through *an interocclusal acrylic mass*, which will comprise the occlusal sides of the mandibular lateral teeth up to the apexes of the labial cuspids, and, in the frontal part, the acrylate will cover the incisal third of the mandibular front teeth.

The screw is the element through which the expansion of both maxillaries in the transverse direction is carried out (standard activator).

The labial bow: the upper and the lower springs (the same type as for the acrylic plates, including the finger spring).

The secondary springs (in the shape of number 8, of the letter S, of a mushroom, etc.)

The positioning pins lean on the mesiolabial surface of the first permanent molars. Their function is to ensure the sagittal position of the appliance. They are made of round 0.8 mm Wipla wire.

Manufacturing

As for all functional appliances (the bionators, Frankel, Herbst, Twin Block appliances), the activator is manufactured in the so-called "*corrected*" / "*built*" *occlusion*. In the case of distalized occlusions at the level of the first permanent molars, the appliance will be manufactured in neutral occlusion at the level of those molars (fig. 1).

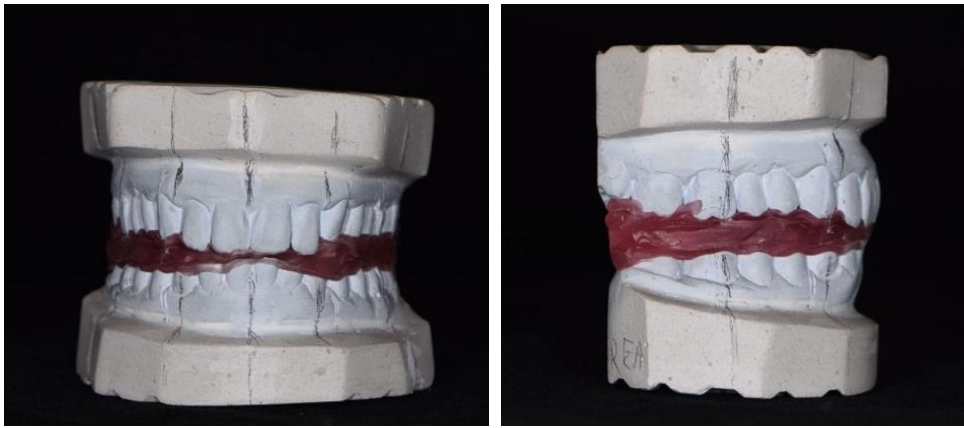

Fig. 1. A "corrected" occlusion made with the help of a wax roll

Clinical stages of an activator's manufacturing

On the study model, one traces 5 vertical lines with the chemical pencil. Two of those lines (one on the right, one on the left) must cross through the apex of the mesiolabial cusp of the maxillary first molar and through the first groove between cusps of the mandibular first molar (neutral relationship). Other two lines (right-left) must cross through the apex of the cusp of the mandibular canine, between the maxillary canine and the maxillary lateral incisor (neutral relationship). The last line must coincide with the bimaxillary interincisive line. These lines are prolonged at the level of the model base, for a better control over the landmarks. Because some cases are particular, sometimes it might be impossible to trace all the five lines, but the lines at the level of the molars must always be traced in neutral occlusion. If it is not possible to trace the lines symmetrically, not even at the level of the molars, one chooses the neutral ratio on the side where there is one, but, at the same time, all the other landmarks must coincide.

Some roll-shaped wax is heated up using an alcohol lamp. The roll is then applied on the lower arch of the model, which must be moistened beforehand, so as to avoid sticking. The surplus at the end is cut out; the roll must slightly exceed the distal surfaces of the permanent molars. The upper arch of the model is then applied on the wax roll and is pressed upon. This step is carried out on a flat, rigid surface, and not by keeping the model in one's hands. The thickness of the wax roll must be 1-2 mm greater than the in occlusion at rest, that is, about 4 mm. (fig. 2)

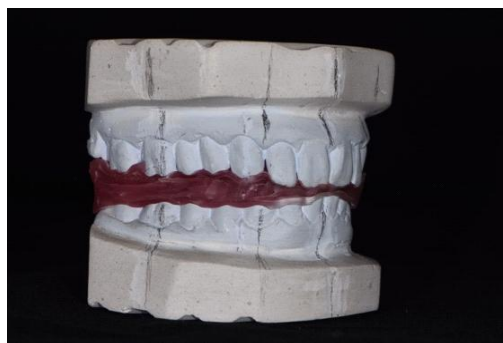

Fig. 2. 4-mm thick wax roll

The wax surplus at the level of the labial surfaces of teeth is removed using a spatula, so that the incisal and occlusal margins of teeth become visible.

Then, this occlusion built on the model is checked out in the oral cavity of the patient. Before checking the model, the patient must do some exercises (of mesialisation or laterality of the mandible) for habituation.

There are two checking techniques: 1. the wax mould is applied on the lower arch and is fixed using the fingers; the mandible is guided to contact with the upper arch or 2. the wax mould is applied on the upper arch and is fixed using the fingers; the mandible is guided to perform the correct occlusion.

Errors that may appear:

- During occlusion, the ends of the wax roll may glide towards the interior part and the roll cannot be later applied on the model
- If the wax is too soft, the patient will reduce its thickness during occlusion and the desired 4 mm thickness will not be preserved
- If the wax is too cold, it becomes rigid and the patient has the tendency to misperform the occlusion

After checking the corrected occlusion in the oral cavity, one checks if the indentations left by the teeth in the wax, as well as the vertical lines traced beforehand coincide on the model.

Based on this corrected occlusion, the dental technician will manufacture the *wax model* of the future appliance; this model will contain all the elements of the appliance: the screw, the labial bow, the secondary screws and the positioning pins. The model is fixed either in the articulator, or using an occlusion key made of gypsum.

This model is checked in the oral cavity: one checks the thickness of the interocclusal mass, the occlusion in the three planes and the placing of the wire elements.

This is the stage where any disparities that may have appeared can still be set right. Anything related to the wax model is set right by the doctor in the oral cavity and on the model. Anything related to the metallic components (wires, screw) is set right by the technician. The final step is creating the acrylic appliance.

Recommendations and effects of the activator

The activator is most recommended in *class II skeletal malocclusions (distalized occlusions) with mandibular retrognathism* and during the active growth phase [12].

Orthopedic effects

In a distalized occlusion, the activator mesializes the mandible for a neutral relationship at the level of the first permanent molars and has an effect on the propulsive, elevator and depressor muscles of the mandible, which are hypotonic in this kind of occlusions. By strengthening the muscles, the mandible is repositioned in both the sagittal and vertical planes. This effect was called „*jumping bite*” by Andresen.

After some longitudinal studies, **Petrovici A.** noticed that the upper insertion of the *lateral pterygoid muscle* is very important in the skeletal adaptation and in stimulating the growth of the condyle cartilage. The conclusion of his studies is that the myotactic reflex and the isometric contraction induce muscular and skeletal adaptation and a new mandibular occlusal pattern [14].

Ruf et al. (2002) mention that, during the mesialization of the mandible, the mandibular condyle moves too, getting out of the distal blockage in the glenoid cavity and benefitting from favourable growth. It is well-known that the growth center – *the condylar cartilage* - is active up to around 15 years of age and ensures the growth of the vertical side of the mandible. These changes also improve the growth of the lower section of the face [11].

As it has no anchoring systems and is maintained in the oral cavity by closing the mouth, it causes the contraction (toning) of *the orbicularis oris muscle*.

Other studies have shown that, when a patient is swallowing the saliva, if wearing the activator, there is greater muscular activity of *the masseter muscle*.

All these effects on the muscles and on the repositioning of the mandible, as compared to the maxilla during the growth phase, minimise the chances of relapse.

This is why most of the quoted authors recommend that, if a child has permanent dentition (over 12 years old) and a fixed orthodontic treatment is foreseen, he should wear an activator or another functional appliance beforehand. They also suggest that these appliance are also worn during the fixed orthodontic treatment and during the final stage, as a means of contention.

Adebimpe O Ibitao et al. have carried out a comparative study on a group of children and a group of adults having a class II skeletal malocclusion (hyperdivergent). They have recorded all their cephalometric data at the beginning of the treatment and at the end of it. The children have been treated with activators and the adults have undergone orthognathic surgery in both maxillaries. At the end of the treatment, the cephalometric landmarks have shown the same evolution and final results in children as in adults [15].

The dentoalveolar effects are the following:

- retrusion of upper incisors
- protrusion of lower incisors
- mesially-oriented eruption of mandibular posterior teeth

The activator may also be recommended in *class I malocclusions (open bite or deep bite)* and in *class III malocclusions*; for the latter, another type of activator is employed, and that is Wunderer activator.

Contraindications

1. Class I malocclusion with crowding of teeth where there is great discrepancy between the two maxillaries
2. Increased height of the lower section
3. Emphasized vertical growth of the mandible
4. Nasal stenosis

Advantages of the activator

1. It improves the usually hypotonic perioral muscular function
2. It constrains the patient to perform nasal breathing
3. It hampers vicious habits and parafunctions (thumb- or lower lip sucking, infantile swallowing)
4. In late mixed dentition, when the primary molars are being replaced by the permanent ones, it does not only not hamper the eruption of permanent teeth, but it may also direct it, if selective polishing of the interocclusal acrylic mass is performed.

Disadvantages of the activator

1. It is bulky and difficult to tolerate
2. It is worn especially during the night (when the muscles are relaxed) and for some hours during the day, which is why the treatment may take a bit longer

Rules for wearing and for activating the appliance

The appliance should be worn during the night and it should be washed with the toothbrush and some toothpaste in the morning. It should be kept in a container with some water in it. It is advisable to wear the appliance for a couple of hours during the day too, because this is when the muscles are completely activated to maintain the appliance in the oral cavity.

The check up should be carried out every two weeks, when the screw is activated by an eighth turn, that is, by 45 degrees (fig. 3); if the situation allows, one can perform several turns. The activation of the secondary springs and of the labial bow (fig. 4) and selective polishing of the interocclusal mass are carried out depending on the clinical situations that appear in the process (fig.5).

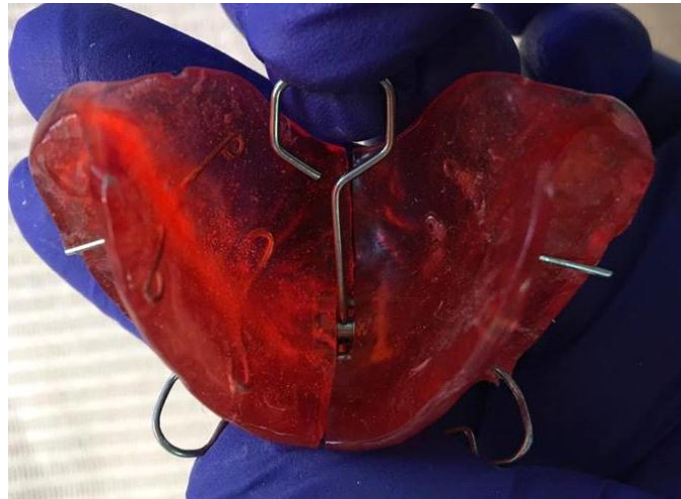


Fig. 3. Activating the median screw

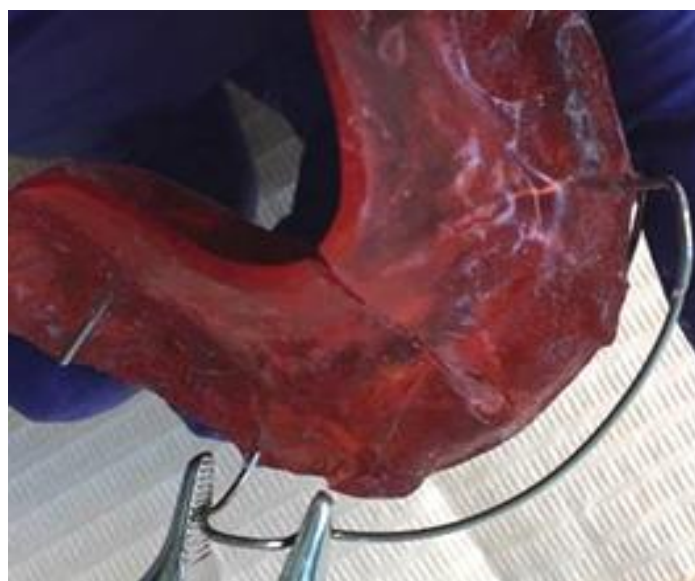

Fig. 4. Activating the labial bow



**Fig. 5. Polishing the interocclusal mass
(molar egression, retrusion of upper incisors)**

Wunderer Appliance

This type of appliance is recommended for patients with class III malocclusion (mandibular prognathism or maxillary retrognathism). It resembles the activator, but the screw is placed so as the two plates glide in the anterior-posterior way during activation, and so the sagittal discrepancy between maxillaries is corrected (the upper plate glides towards the anterior part and the lower one glides towards the posterior part). This activator also has labial bows and one can add 8-shaped or S-shaped secondary springs to it.



Fig. 6. Wunderer Appliance

Balters Bionator

This type of appliance is a reduced variant of the activator:

- the acrylic part is made up of a narrow lower plate and two upper lateral winglets. It anchors only on the dental part, and not on the alveolar one
- it contains a lingual spring whose purpose is to stabilize the appliance and to direct the tongue and the mandible towards the anterior part
- the labial bow has a buccinator loop in order to remove the buccinator muscle

Through its design, it creates a balance between the tongue and the perioral muscles which have an effect on the shape of the arches, and so the tongue benefits from adequate functioning room.

Classification:

- Type I bionator: used in treating Class II division 1 malocclusions, with good results in mixed dentition [13]
- Type II bionator: used in treating open bites (where the tongue is kept away by teeth)
- Type III bionator: used in treating Class III malocclusions



Fig. 7. Balters Appliance

Frankel Appliances

These moveable appliances are designed based on the labial shield principle: the dental arches must be protected from the action of the external muscles (buccinator, masseter, genioglossus muscles) in order to ensure their optimal development. Thus, the appliance has lateral shields and lip pads.

Frankel appliances are in fact some skeletal labial shields which do not affect phonation (they may also be worn during the day) and their purpose is to neutralize myo-dynamic disorders.[13]

Classification:

- Frankel I – used in treating Class II division 1 malocclusions (distalized occlusion with upper front teeth protrusion)
- Frankel II - used in treating Class II division 2 malocclusions (distalized occlusion with upper front teeth retrusion)
- Frankel III - used in treating Class III malocclusions (mandibular prognathism or maxillary retrognathism)

Twin-Block Appliance

It is extremely effective in correcting the sagittal discrepancy between maxillaries (distalized occlusions), through the help of the inclined planes of the double plates.

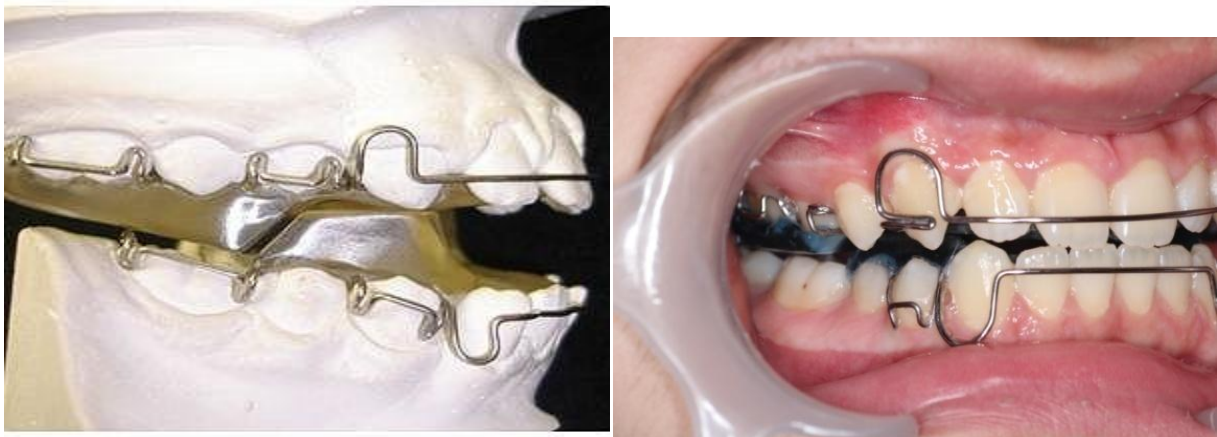


Fig. 8. Twin Block

Herbst Appliance

This appliance contains a bilateral telescopic mechanism based on a crankshaft system, which forces the mandible to take an anterior position when closing and opening the mouth (this is effective in correcting class II malocclusions – distalized occlusions).

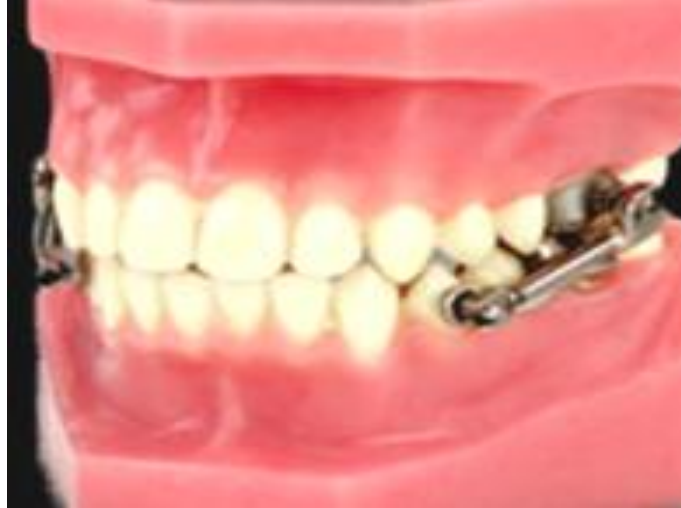

Fig. 9. Herbst Appliance

Myofunctional appliances/ Trainer systems

These are performing devices used in guiding the growth and in intercepting oral bad habits. They represent a modern alternative to the standard activator. They are made of soft silicone (type 1) and hard silicone (type 2). These bimaxillary appliances correct bad habits and help in aligning teeth. They may also correct discrepancies between the maxillaries (I-2 and I-3 trainers) [1].

Trainers

- For children: T4K
- For adults: T4A
- For patients wearing fixed appliances: T4B
- Myobrace: for light anomalies which also need alignment

“Myofunctional Research Company” (Australia) - The Trainer System

The interceptive treatment with T4K takes place in two phases:

1. Phase no. 1:

- Eliminating bad habits; a very flexible removable appliance, which can adapt even to severe malocclusions
- The appliance must be worn for an hour during the day and during all the night
- Duration of treatment: 6 to 8 months.

2. Phase no. 2: correcting teeth alignment
- A new, harder removable appliance
 - Duration of treatment: 6 to 12 months

The I-2 trainer repositions the mandible, corrects Class II malocclusions and improves alignment of teeth.

The I-3 trainer is recommended in treating negative overjet during the first phases of mixed dentition.

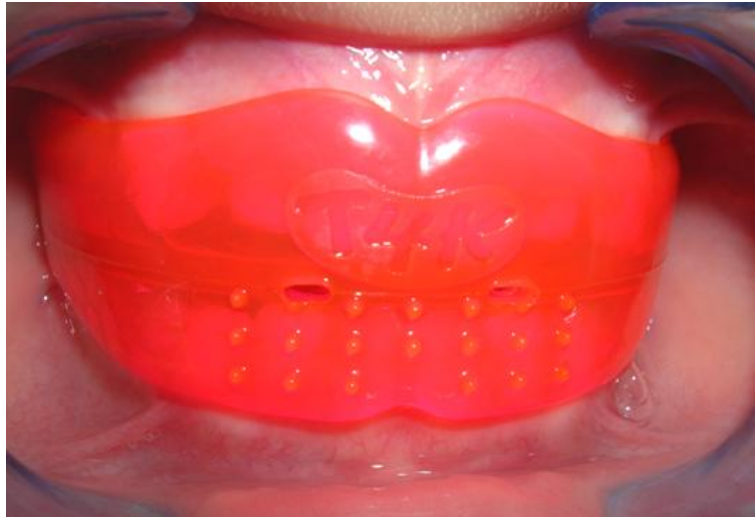


Fig. 10. T4K trainer during phase no. 2

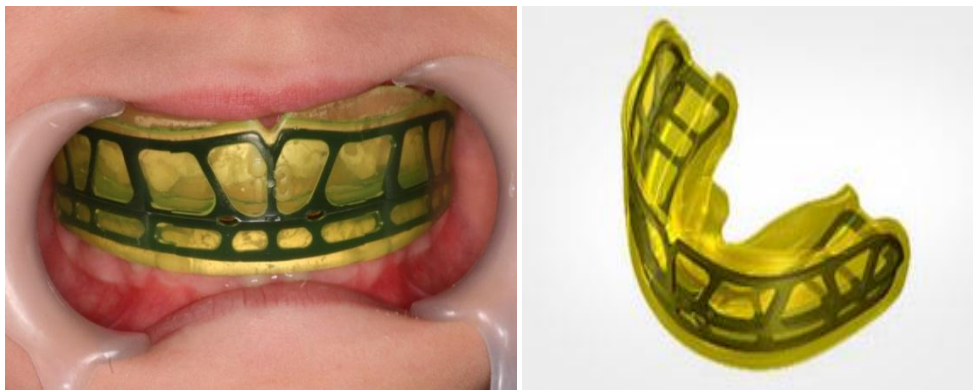

Fig. 11. I-3 trainer for intercepting Class III anomalies

MYOBACE

- Created in 2004
- Has the main traits of the T4K and improved dental alignment properties
- Recommended for children with mixed or permanent dentition

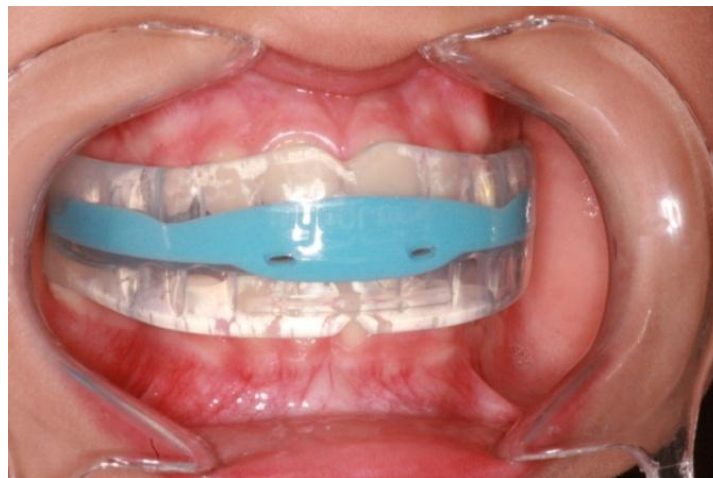
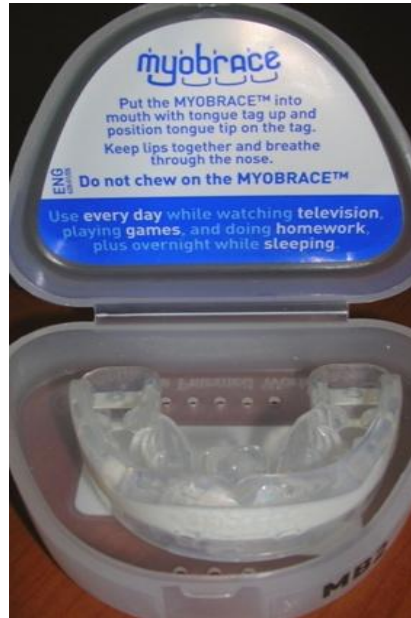
Fig. 12. Myobrace

14. FIXED INTERCEPTION APPLIANCES

Interceptive treatment is very important in ensuring the harmonious development of the dental arches. The interception of orthodontic anomalies with the help of various means (myofunctional exercises, removable or fixed appliances) is much easier to perform at a young age, when there is still a possibility of early correction. Fixed appliances are more effective because they cannot be removed. [1]

The lingual shield

- it is extremely useful in preventing finger sucking or infantile swallowing
- it may be attached to an upper plate (as we have mentioned before), but it can also be welded on the molar bands



Fig. 1. Fixed appliance with a lingual shield

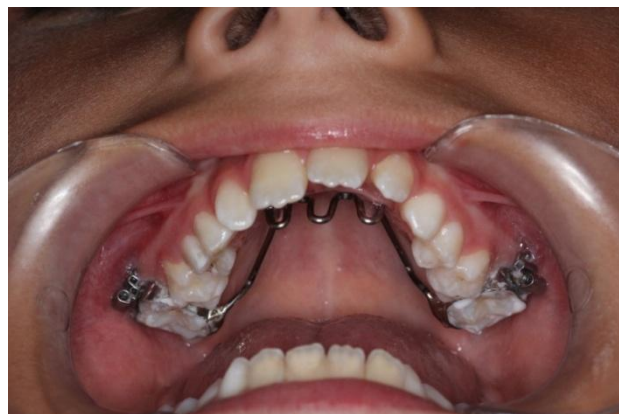

Fig. 2. Lingual shield on cemented molar bands

- for a precise adaptation, it is recommended to choose the right dimension of the bands, to adapt them on the working model and to take a new dental impression with the bands placed in the oral cavity; this way, the manufacturing precision of the appliance will increase.
- after taking the impression, one may get to manufacturing the shield proper and to its welding on the bands.
- the appliance is cemented in the oral cavity and it is maintained until one notices the disappearance of the bad oral habit

Another type of shield is the one employed in the case of unilateral crossbite caused by the habit of sleeping with one's hand(s) under one's head.

There is a number of muscle re-education exercises which may be used in patients with an infantile swallowing pattern. These exercises require daily repetition and perseverance on the part of the patients [17,18]. When the patient does not comply with these requirements, one can resort to a fixed appliance with a small acrylic ball fixed to an Omega loop on a TPA (a transpalatal arch). The small ball can roll with the help of the tongue, thus removing its interpositioning habit. The tongue will take a posterior position at the level of the palate, and the negative effects on the dental arches will be removed [2]. This appliance may also be used in adults because it can be combined with a fixed dental appliance.

The Transpalatal Arch (TPA)

It has the purpose of keeping the molars in place during the orthodontic treatment and of increasing the posterior anchorage. In mixed dentition, it also helps as a space maintainer. When it is designed at a certain distance from the palate, it can cause the intrusion of the molars. By activating the transpalatal arch, the derotation of the molars may be obtained.

Work stages in manufacturing a TPA

- one chooses the orthodontic bands so as they can easily fit the maxillary first molars
- with the help of a pair of pliers, one creates the median loop and the lateral braces
- the end of the lateral braces must come in contact with the palatal sides of the bands fixed on the maxillary first molars, so that the appliance is passive the moment it is cemented in the oral cavity
- then the orthodontic tubes are welded at the level of the orthodontic bands
- after welding, the appliance may be positioned in the oral cavity

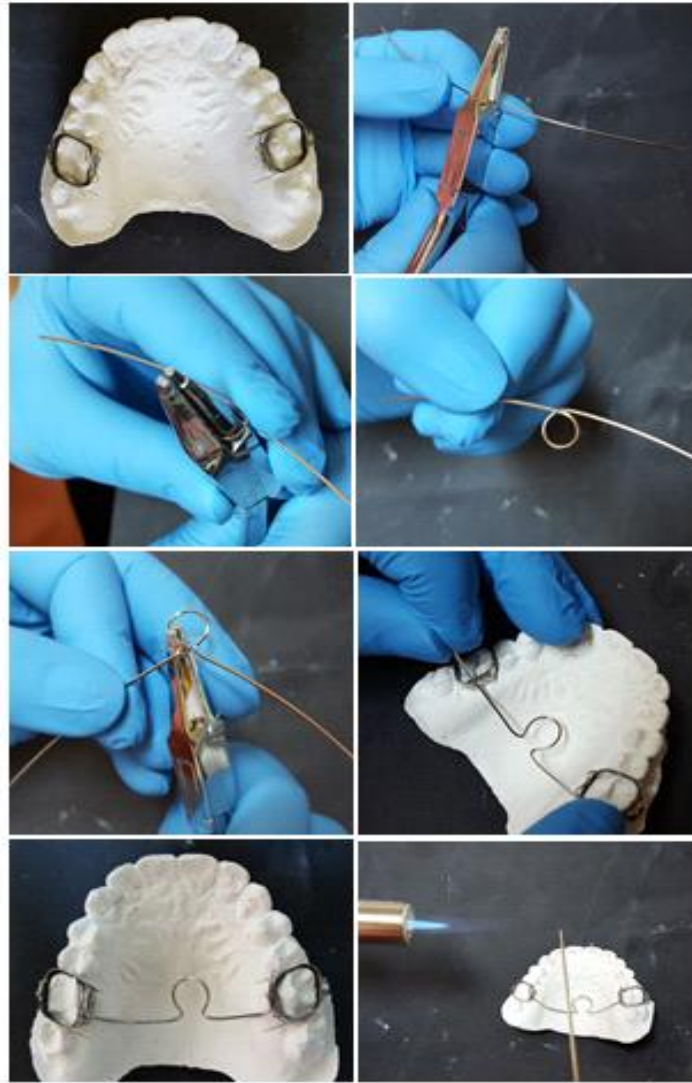


Fig. 3. Work stages: manufacturing a transpalatal arch

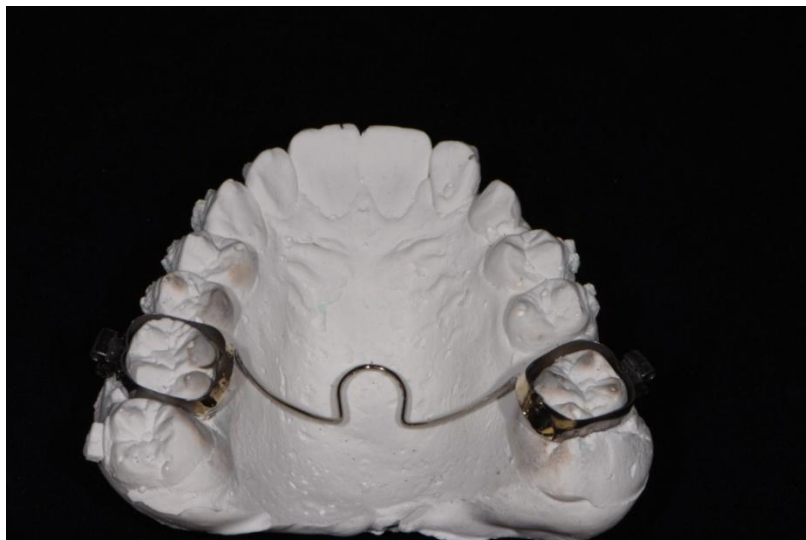


Fig. 4. Transpalatal Arch (TPA)

15. OTHER FIXED APLIANCES USED IN ORTHODONTICS: EXPANSION AND DISTALIZATION APPLIANCES

In order to obtain a quick expansion in the transverse plane, one can use the following appliances: the disjunctor, the quad-helix, the fan-type expander etc. These devices are active orthodontic appliances. They are cemented in the oral cavity and their purpose is to increase the transverse diameter of the upper arch (fig. 4). The distalizer (fig. 5) is another frequently used appliance, especially in the case of a Class II malocclusion. It is recommended in the following situations:

- Class II anomaly
- before the eruption of the maxillary second molar
- when one wishes to obtain space in the mesiodistal plane

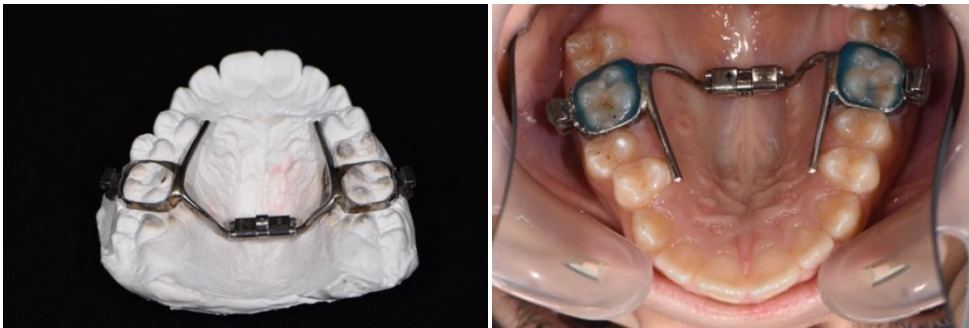

Fig. 1. Disjunctor used for a symmetric transversal expansion

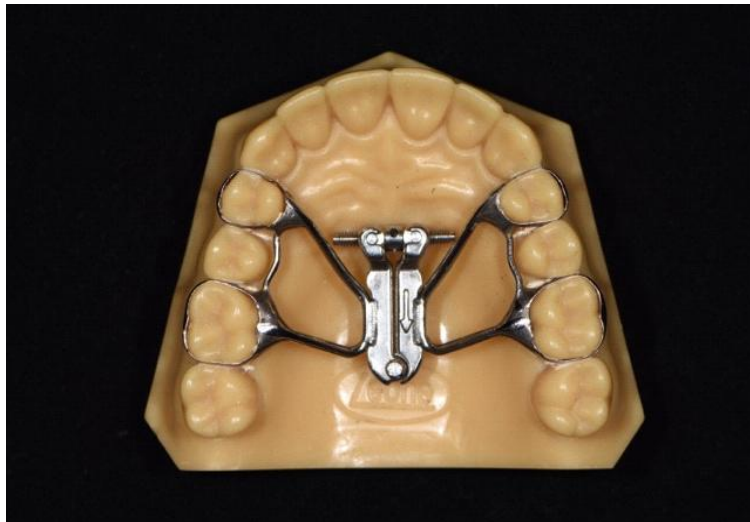

Fig. 2. Fan-type expander

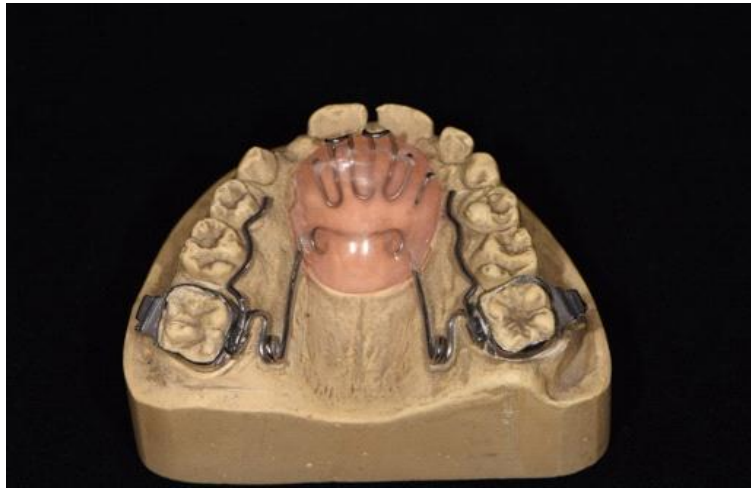

Fig. 3. Fixed appliance with two activation loops, a Nance button and a lingual shield

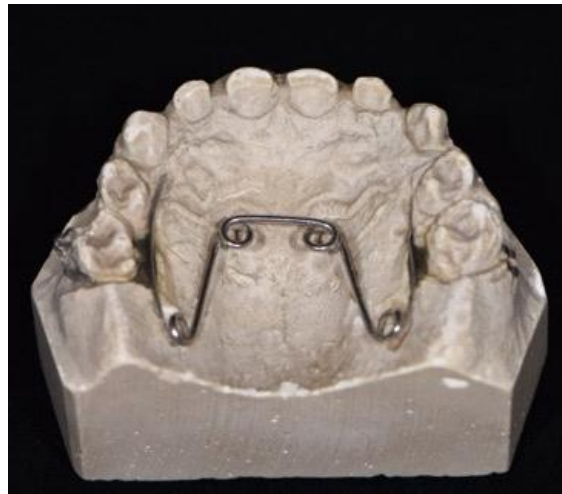

Fig. 4. Quad-helix

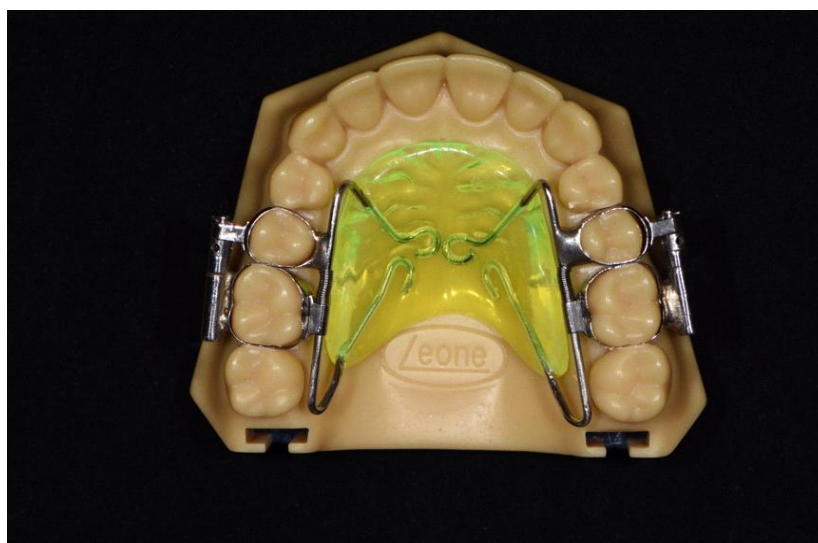
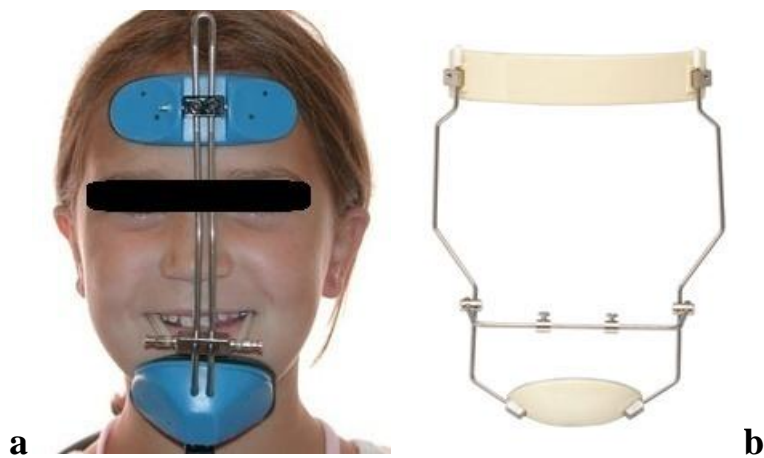
Fig. 5. Distalizer with a bilateral effect

16. EXTRAORAL FUNCTIONAL APPLIANCES

These are orthopedic devices which control facial growth, as they are worn during the growth phase. There are various types and ways of applying them. Some of the cases when such an appliance is recommended are the following:

- Increasing the anchorage
- Molar derotation/distalization
- Correcting the Class III malocclusion
- Correcting the Class II malocclusion and redirecting growth



**Fig. 1. Facemask used in treating maxillary retrusion (ab).
b - Delaire mask**

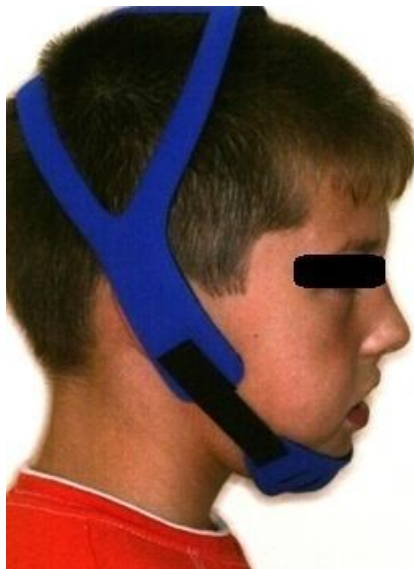

Fig. 2. Occipital-pull chin cup used in treating mandibular prognathism

17. VACUUM-FORMED ORTHODONTIC APPLIANCES

Vacuum-formed orthodontic appliances have various applicabilities. These appliances have initially been used only as passive appliances that maintained the results of an orthodontic treatment, or as space maintainers in children or adults (until the prosthetic resolution of the case). Nowadays, the number of recommendations regarding the use of these appliances has increased, and they have various roles as active appliances:

- interceptive appliances with an inclined plane: they are used in patients during the growth phase who suffer from a Class II or III malocclusion
- aligners for minor dental changes: small dental corrections after an orthodontic treatment with a fixed appliance/ patients with a stable occlusion but a slightly malpositioned tooth or few malpositioned teeth
- aligners for major dental changes: in treating some orthodontic anomalies (Invisalign, Clear Aligner, My Clear Brace etc.) [19,20]

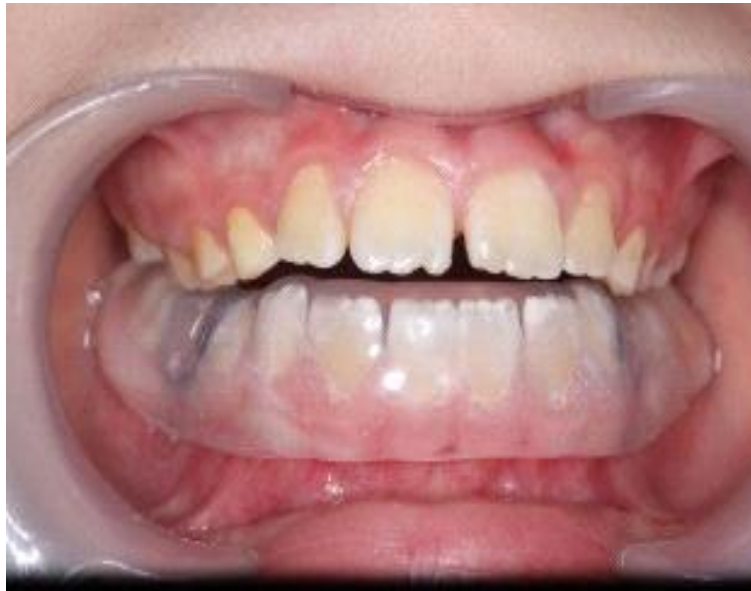

Fig. 1. Vacuum-formed appliance

Interceptive appliances with an inclined plane

These appliances are recommended in treating a Class II or III anomaly in children. Used as functional appliances, they can guide the growth of the mandible in children in order to obtain a normal relationship between teeth and between the bony bases. The functioning principle of such an appliance refers to guiding the mandible and obtaining a new position for it as compared to the maxilla. The inclined plane is a common element used in other orthodontic appliances, but through this system, it can also be used in the case of tooth luxation in children, as it is made of dental composite [21].

The splint is made of thermoplastic (PETg, polyethylene, polycarbonate) and the inclined plane is made of acrylate [20].

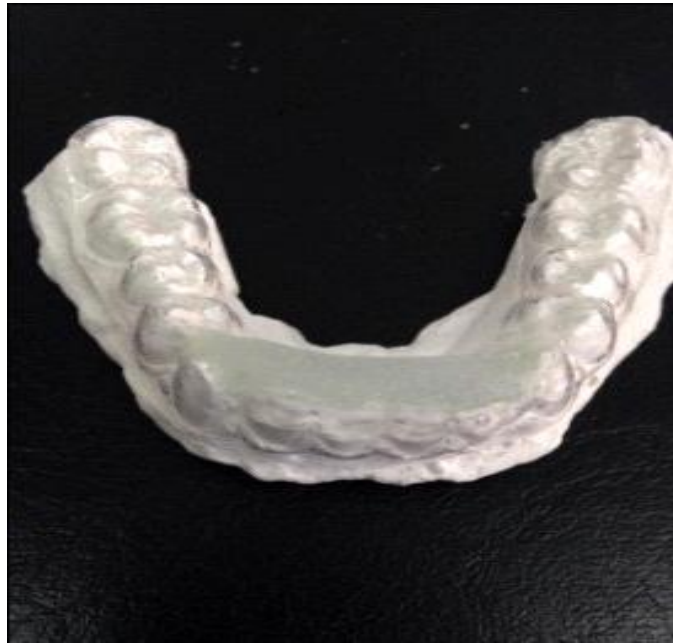

Fig. 2. Splint with an acrylic inclined plane

In order to also obtain a slight expansion at the level of the dental arch, the splint may include a median expansion screw.

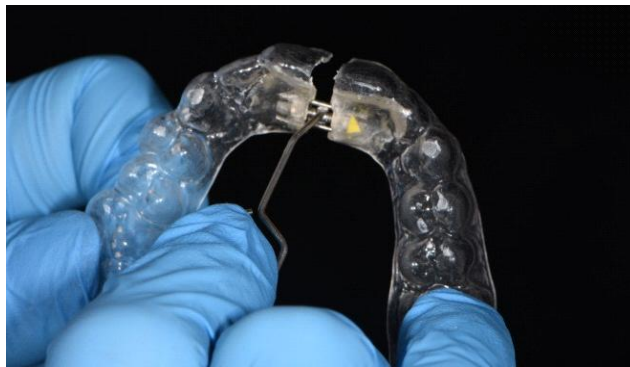

Fig. 3. Activating the expansion screw of an orthodontic splint

Vacuum-formed appliances for minor dental corrections

The manufacturing process of these appliances is very simple and requires the following components:

- a thermo vacuum forming machine (e.g. Ministar/Biostar Scheu Dental or similar machines)
- aligner foils of various sizes (0.6 mm, 0.8 mm, 1 mm)
- Isofolan foils
- the plaster model of the patient
- plaster models saw
- discs
- flowable composite
- dental curing light
- acrylic drill polisher

The tooth that will be corrected with the help of the aligner must be removed from the plaster model with the help of the saw and of the discs. It will then be fixed on the model in its new position with the help of some flowable composite, so that it is perfectly framed on the dental arch in all of the three planes. The composite is then polymerized with a dental curing light for at least 30 seconds. Thus, one obtains the patients' model with the new position of the tooth.

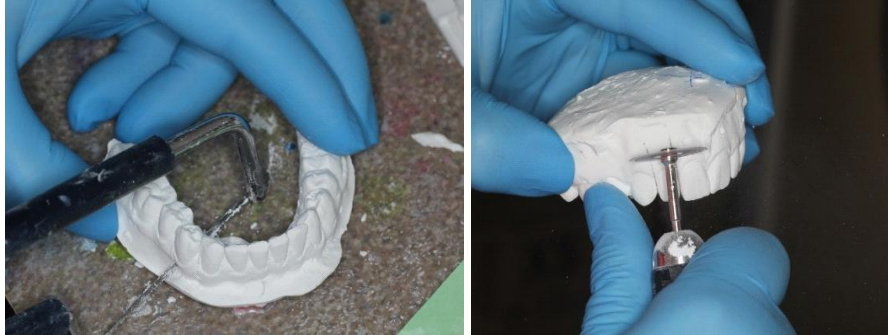

Fig. 4. Removing the tooth from the plaster model

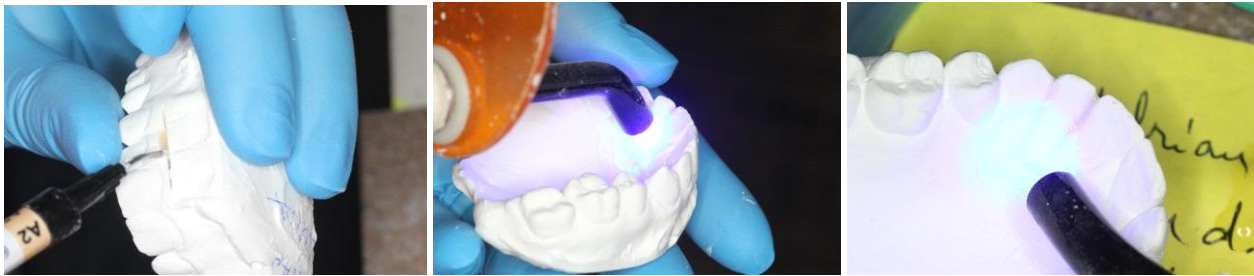


Fig. 5. Fixing the tooth in its new position with the help of the composite and polymerizing it with the dental curing light

In the meantime, the thermo vacuum forming machine should be prepared. One must wait for the machine to reach the working temperature. In order to obtain an effective mouthguard, at first, one must apply an Isofolan foil, which broadly has the same effect as a spacing varnish in fixed prosthetics.



Fig. 6. Isofolan foil applied on patient's model after 25-second heating

This 0.01 mm-thick foil is heated for 25 seconds in the thermo vacuum forming machine and then applied on the model containing the corrected tooth position. The purpose of the foil is to maintain an optimum distance between the teeth and the aligner proper, for the patient to be comfortable with it.

The Isofolan foil is then cut and the only portion that is maintained on the model is the one closely adapted at the level of the dental arch. The procedure is repeated, but this time the foil is 0.6 or 0.8 mm-thick, as it is prepared for the mouthguard proper. These two sizes are the most employed in practice. The difference between them lays in the required heating time: 25 seconds for the 0.6 mm-thick foil and 30 to 35 seconds for the 0.8-thick one.

The model is placed in the Ministar machine. The foil for the aligner is heated and then applied on the patient's model, which also contains the Isofolan foil at the level of the dental arch. After obtaining a close adaptation of the aligner foil, the model is removed from the machine [20]




Fig. 7. Preparing the polyethylene foil and the model on which the Isofolan foil is applied

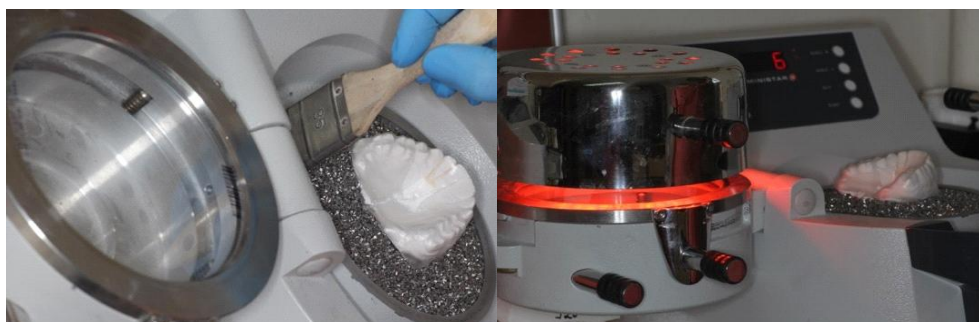


Fig. 8. Preparing the machine and reaching the working parameters (time, temperature)



Fig. 9. Obtaining the aligner after reaching the optimum parameters and after the thermo vacuum forming process

Next comes the cutting of the splint out of the model with the help of some discs fixed on a straight utensil and the finishing stage. The outline of the splint must consider the periodontium, its limit being guided by the cemento-enamel junction.

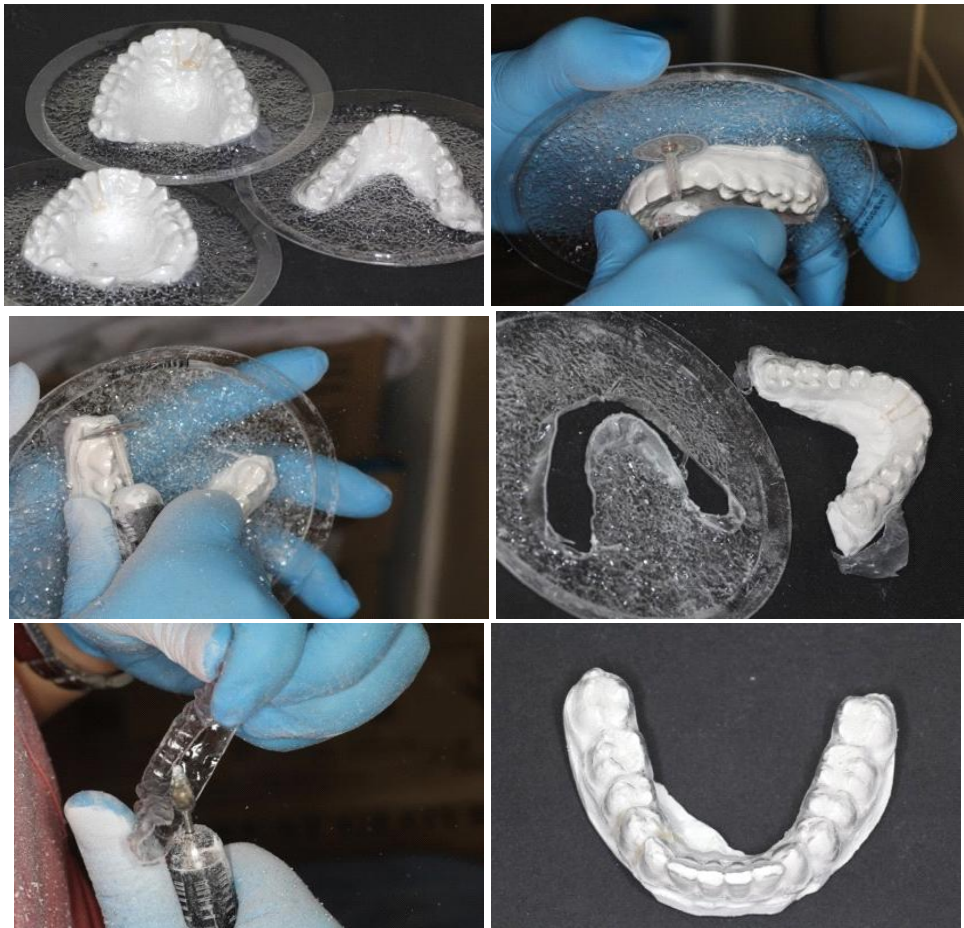

Fig. 10. Cutting out the excess material and finishing the splint with the help of the discs and of the acrylate drill polisher

After finishing, the aligner/splint is ready to be inserted in the oral cavity.

Aligners for major dental corrections

The treatment with such appliances implies a complete diagnosis and a detailed assessment of the case. The patient benefits from a number of aligners made with the help of CAD/CAM technology, after a 3D analysis of the case (a digital setup and a software which analyzes planned dental movement). The manufacturing technique of these aligners implies the purchase of a much more complex equipment (3D scanner, 3D printer, 3D software) and is performed only in specialized laboratories. Usually, the ones who benefit from this kind of treatment are adult patients with minor or medium malocclusions. This treatment is not suitable in the more severe cases. Moreover, the orthodontist must have a certificate proving (s)he is capable of treating the cases with the help of aligners [22,23].

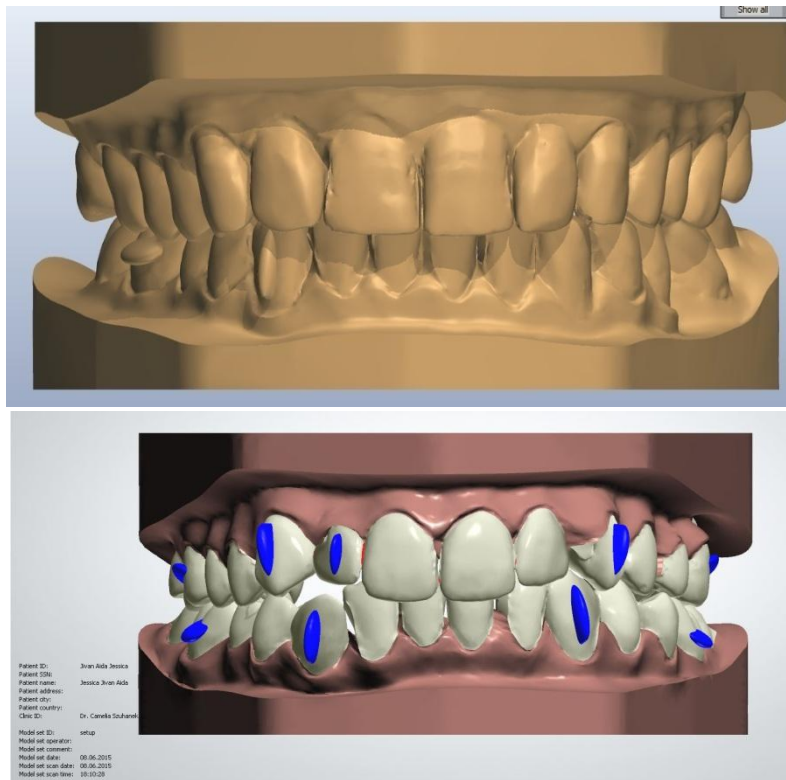


Fig. 11. Digital setup for the Clear Aligner system

Devices for relapse prevention made of thermoplastic materials

Bimaxillary retention devices (positioners) can also be manufactured from thermoplastic material (e.g. polyethylene), just as the splints/aligners, but they must be much thicker. They are used at the end of the orthodontic treatment, in order to maintain the relationship between the arches (fig. 13).

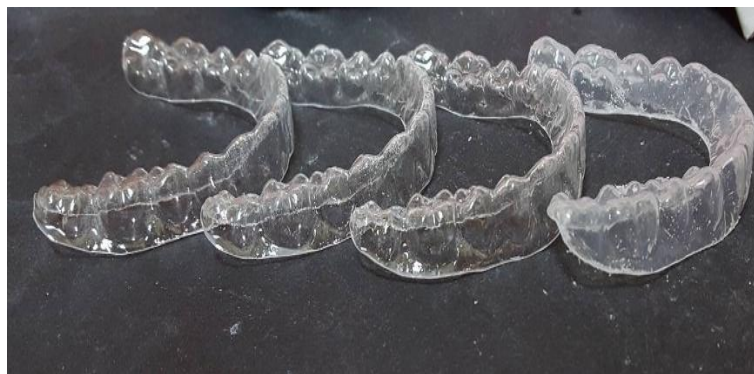

Fig. 12. Retention splints

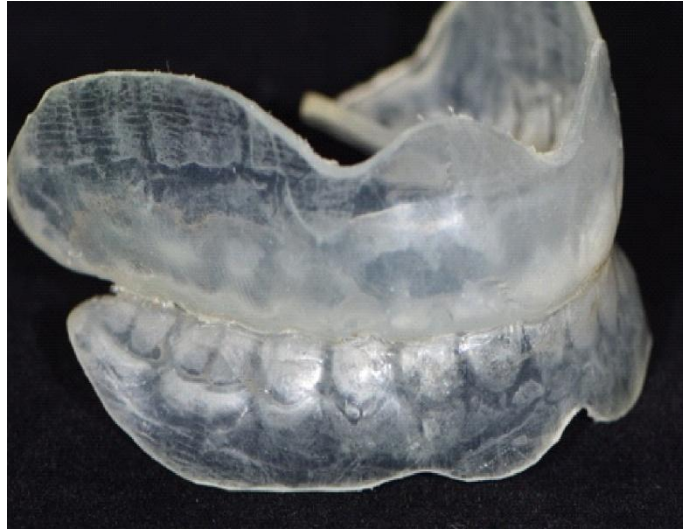


Fig. 13. Positioner (bimaxillary device)

18. FIXED ORTHODONTIC APPLIANCES

Fixed orthodontic appliances are used in treating dental anomalies in both children and adults. They are made of the following elements:

1. Brackets – incisors, canines, bicuspid
2. Tubes/bands – at the level of the first molars and sometimes also at the level of the second molars
3. Wires – either metallic or metallic with a white coating layer
4. Ligatures – either elastic or metallic

The brackets

The orthodontic bracket is a passive component of the fixed orthodontic appliance which allows the transfer of the force exerted by the orthodontic wire to the tooth on which it is fixed.

There are various bracket prescriptions, but the most employed nowadays are Roth and MBT in the *Straight Wire* system. Each bracket for each tooth has a different design and contains a certain piece of information regarding the angulation (tip), the torque and the in-out values. The orthodontist does not have to resort to wire bending, and this is where its name (*Straight Wire*) comes from. In the past, all brackets used to be identical and each desired orthodontic movement was carried out through various wire bends (the Edgewise system) [24,25].

The straight wire technique uses the slow friction principle, which means that, for the wire to perform its action, there must be as little friction as possible between the bracket slot and the wire.

A bracket is made up of several elements: the base, adapted to the convexity of the tooth and containing grid-like retention systems, four wings, a slot (0.018" or 0.022" in diameter) where the wire is inserted and a hook (canine bracket). Some types also have hooks at the premolar level.

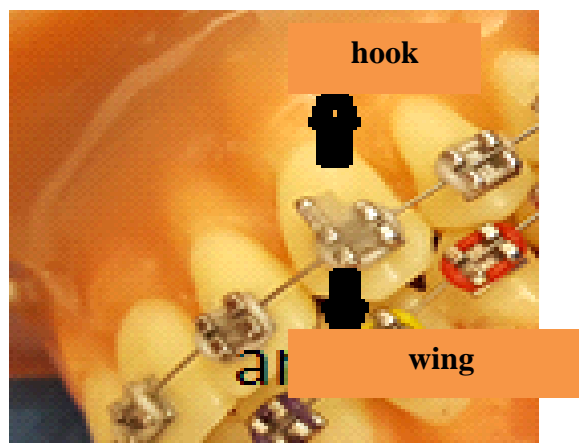


Fig. 1. A bracket and its components

There are various bracket classifications (considering their size, the material, the slot size), so that the orthodontist is able to choose the right option depending on the characteristics of the clinical case and on the wish of the patient. The classifications can be made considering:

The size:

- medium
- mini
- ultra mini

The material:

- metal: nickel titanium alloy, chromium, steel – their disadvantage is that of being inaesthetic
- composite – they are aesthetic, but much more fragile
- ceramic – monocrystalline or polycrystalline
- ceramic with a metal slot – it is both an aesthetic option and an effective one (regarding friction) [26]

The slot size: Frequently employed versions can have the following sizes:

- 0.018” (0.45 mm)
- 0.022” (0.55 mm)

The ligation method:

- with the help of elastic or metal ligatures (tie wing)
- self ligating brackets – with a clip (do not require elastic bands)

The surface on which they are stuck:

- labial brackets
- lingual brackets

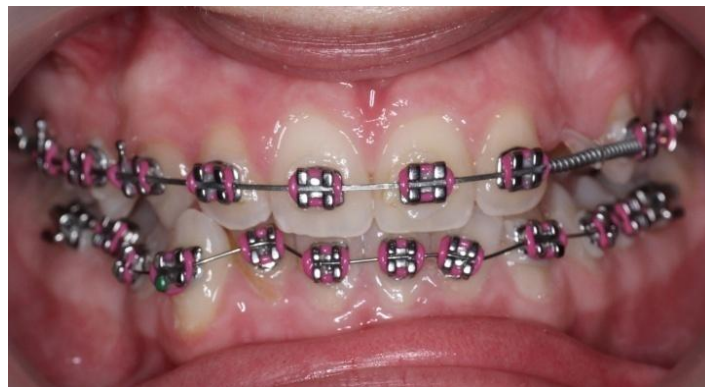

Fig. 2. Fixed metallic labial appliance

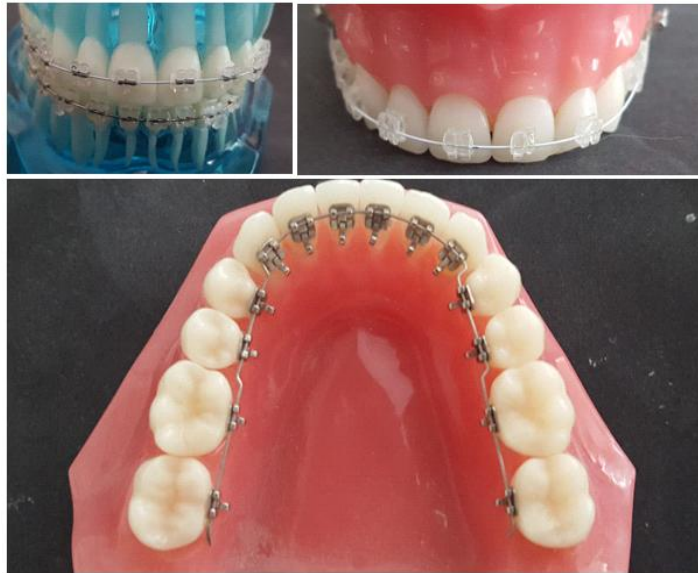

Fig. 3. Various bracket types: ceramic with a metal slot, ceramic and lingual

There are two methods of fixing the brackets: the direct method and the indirect method. The direct method implies the individual fixing of the brackets, a procedure carried out by the orthodontist in the dental office. The indirect method implies the manufacturing of a transfer splint. The dentist or the technician fixes the brackets on the patient's model, and, with the help of the splint, they are then fixed, in the same position and at once, in the oral cavity. This method is much more precise and is mostly used in lingual orthodontic technique [25]. The fixing of the brackets is performed through an adhesive technique: etching, bonding and self polymerized or photopolymerized composite (light cure).

The orthodontic wires

The orthodontic wires are positioned in the bracket slots and are fixed with the help of the ligatures, in order to exert force. The wires have various sizes, shapes and are made of several alloys.

Classification of the wires depending on the section shape:

- Round (e.g. 0.012", 0.014", 0.016", 0.018")
- Square (e.g. 0.016 x 0.016 ")
- Rectangular (e.g. 0.016 x 0.022")
- Combined sections (e.g. two-dimensional wires)

Classification of the wires depending on the alloy they are made of:

- Gold
- Stainless steel
- Cobalt-Chromium
- Nickel Titanium
- Alpha Titanium
- Beta Titanium
- Titanium Molybdenum (TMA)

- Aesthetic coated wires

- **NiTi/Nitinol** (nickel, titanium; some also contain copper, for increased elasticity) – these are flexible, shape-memory wires; there are also metallic wires with an aesthetic white coating.

These are active wires with a different action on teeth: the first ones, used at the beginning of the treatment, are round wires (from 0.12 up to 0.16 or 0.18), used for tooth alignment and for leveling the occlusal plane; later on, the rectangular ones are employed; these increase the arch perimeter and correct the torque and the tooth angulation.

- **SS** (stainless steel) – they are rigid, inactive, deformable wires; they can also be round or rectangular; the latter have two main actions: that of fixing the obtained results and optimising the torque (which is why they are used at the end of the treatment) or that of closing gaps (for example, in the case of premolar extractions)

The wires are preshaped in the ideal standard shape, but there are also shapes adapted to the face (dolicho- or brachycephalic face shape), that is, to the type of the anomaly [25, 29].




Fig. 4. Different wire shapes

Aesthetic wires

- Metallic wires, coated with a polymer layer (PTFE Teflon – carbon and flourite or epoxy resins)
- Nonmetallic wires - fiber reinforced composite (Simply Clear – Biomers Products/OptiflexOrmco)

The wires for the upper arch are different as compared to the wires for the lower arch. The upper wire is 3 mm larger than the lower wire, in order to maintain a proper ratio between the arches.

The molar tubes/bands

Bands are fixed at the level of the molars, on a base similar to the one of a bracket. Each band contains a slot, for the insertion of the wire, and a hook. Each molar has its own tube/band (right/left upper tube, right/left lower tube). The tubes, just like the brackets, contain a certain piece of information regarding the angulation (tip), the torque and the in-out values, depending on the prescription. The tubes are more hygienic and more comfortable than the bands.



Fig. 5. Dental tube and orthodontic bands containing a tube, a hook and a palatal wing

If one opts for bands, they must contain the before mentioned tubes and the hook. The bands are also used in case the fixed orthodontic appliance is associated with other devices (TPA, expander, quad-helix etc.). If used independently, their advantage is that palatal wings can be welded on them; these are useful in criss-cross elastic tractions between arches (for instance, in case of cross-ratio at the level of the molars); another advantage is that the bands do not uncement as easily as the tubes fixed through the adhesive technique (the rings are cemented with glass ionomer cement).

The ligatures

The ligatures can be elastic (elastic chain mode) or metallic. They are applied over the wings of the bracket and over the orthodontic archwire respectively. Elastic ligatures must be changed periodically and this represents a sort of activation because they lose their elasticity in the oral cavity and no longer exert the same pressure on the archwire. They are applied using a Mathieu forceps.

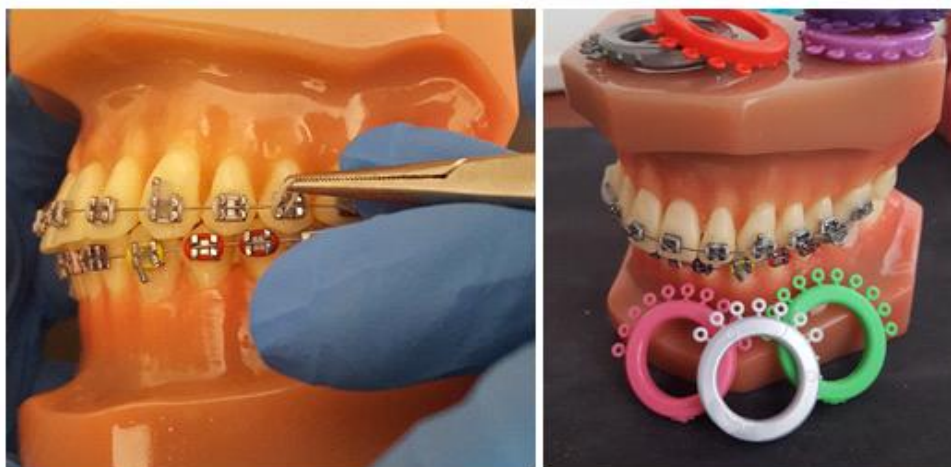

Fig. 6. The technique for applying elastic ligatures

19. HANDLING ORTHODONTIC EMERGENCIES IN THE DENTAL OFFICE

There are various orthodontic emergencies that any dentist must be familiar with, in case the patient cannot go to an orthodontist (due to the distance or the place of residence of the patient). These emergencies represent simple manoeuvres that can be performed in any dental office.

Irritations of the oral mucosa

The sores that patients wearing a fixed orthodontic appliance experience are caused by the hooks on the brackets and on the molar tubes or by a protruding bit of wire at the level of the molars. There are some simple solutions for these situations:

- Applying orthodontic wax or composite at the level of the hook or of the wire;
- Cutting the wire using an orthodontic cutter or a turbine (depending on the option the dentist makes);
- Repositioning the wire in its tube with the help of a forceps, if the wire has worked itself out of place.

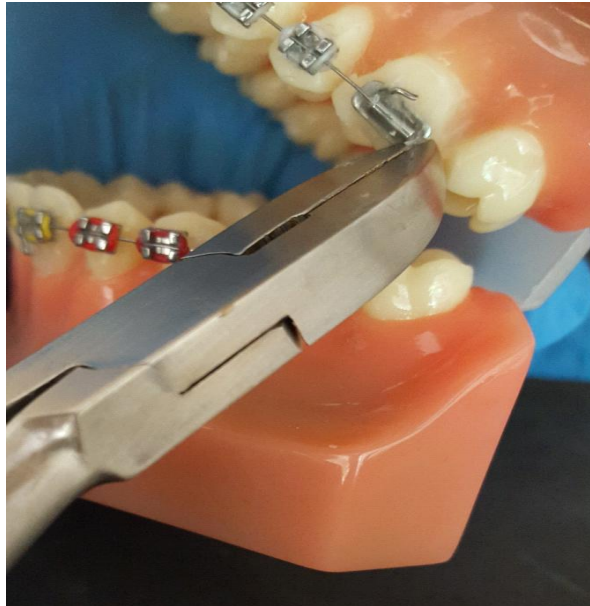


Fig. 1. Cutting the distal tube wire with the help of a cutter/ a nail clipper

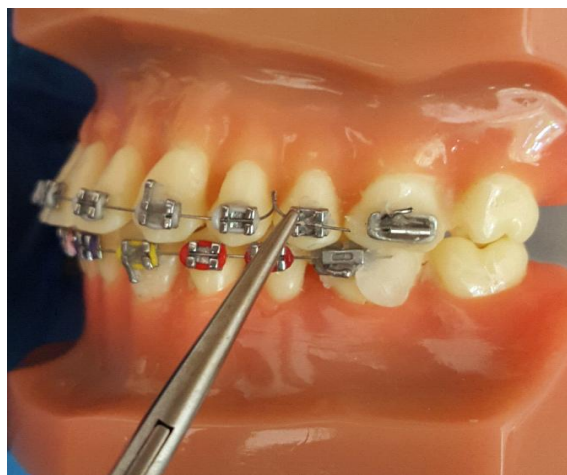

Fig. 2. Positioning the wire in its tube with the help of a dental tweezer

Applying an elastic ligature

If the patient comes to the dental office with a broken or missing ligature, the applying manoeuvre is very simple: with the help of a needle holder/ a probe, the ligature is positioned over the wings of the bracket.

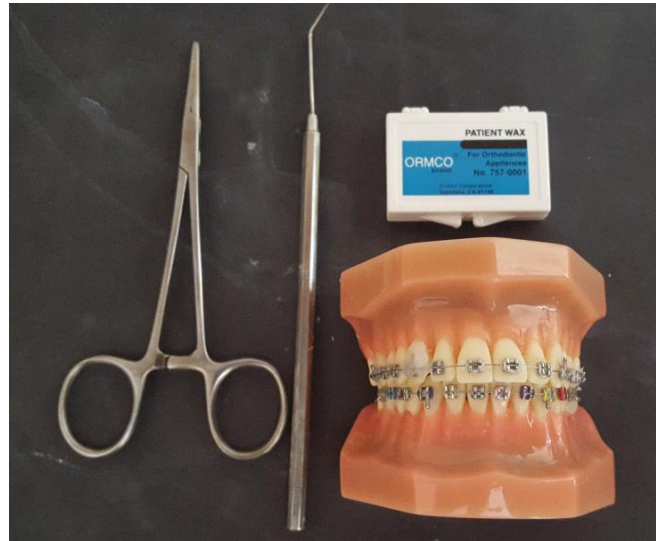


Fig. 3. Mosquito forceps used in applying elastic ligatures at the level of the brackets

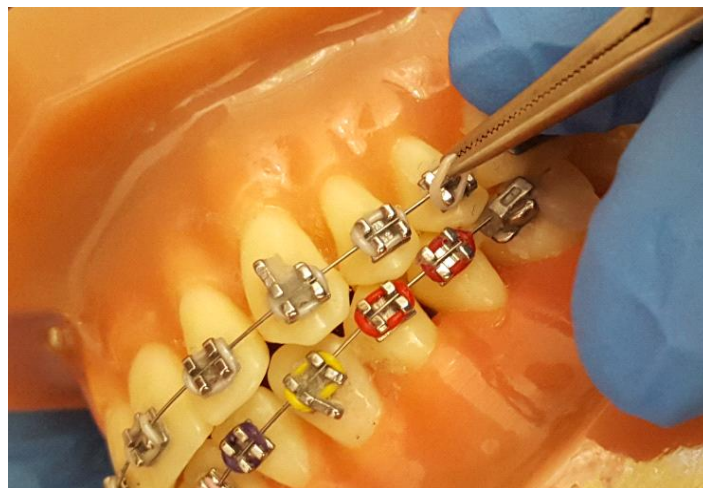

Fig. 4. The technique for applying elastic ligatures

Loose bracket

If the patient comes to the dental office with a loose bracket and (s)he cannot go to an orthodontist, the bracket can be removed in order to avoid discomfort. Using a probe, the elastic ligature is removed from the wings and the bracket is taken out from beneath the wire. The patient must make an appointment to see an orthodontist as soon as possible, in order to avoid unwanted dental effects.

BIBLIOGRAPHY

1. SZUHANEK C.- Courses
2. GLĂVAN F., MOISE M, BRATU C. “Ortodonție și ortopedie dento-facială”, Ed. Eubeea, 2008
3. SOLOW B., SONNESEN L. Head posture and malocclusion, EJO 20 (1998), 685-693
4. DORON H., REDLICH M., MIRI S., HAMUD T., GROSS M. “The effect of mouth breathing versus nasal breathing on dentofacial and craniofacial development în orthodontic patients” The Laryngoscope, Vol. 120, Issue 10, pages 2089–2093, October 2010
5. www.scielo.br (Dental Press Journal of Orthodontics)
6. JA ÎN M., DHAKAR N., “Arch forms- an overview”, URJD, vol.3, Issue 1, p. 16-21, 2013
7. RHATI M., FIDA M. “Applicability of Pont's Index în Orthodontics”, Journal of the College of Physicians and Surgeons Pakistan 2014, Vol. 24 (4): 256-56
8. BASAVARAJ S. An atlas on cephalometric landmarks , Jaypee 2013
9. WALTER F., BRATU ELISABETA., BRATU EMANUEL, Analiza teleradiografiei de profil – ghid practic. Ed.Helicon 1998
10. www.audaxceph.com
11. RUF S et al – TMJ effect of Activator Treatment: A prospective longitudinal Magnetic Resonance Imaging and Clinical Study – The Angle Orthodontist, vol 72, issue 6 , dec 2002
12. BISHARA SE, ZIAJA RR – Functional appliances: a review - Am J Orthod Dentofacial Orthoped 1989, mar, 95 (3): 250-8
13. GRIVU O., PODARIU A., JIANU R. – Tehnica ortodontica, Ed. Mirton Timisoara, 1994
14. GRABER TM, RAKOSI AG, PETROVICI A – Dentofacial orthopedics with functional appliances. The CV Mosby Comp St Louis 1985
15. ADEBIMPE O IBITAO et al - Dentoskeletal effects of functional appliances vs bimaxillary surgery în hiperdivergent class II patiens – The Angle Orthodontist 81(2):304-11, March 2011
16. TAUSCHE E., LUCK O. HARZER W. “Prevalence of malocclusions în the early mixed dentition and orthodontic treatment need”, EJO, June 2004, vol.26, Issue 3, p.237
17. YANEZ R. “1001 Tips în Orthodontics And Its Secrets”, AMOLCA 2008, ISBN 978-958-8328-46-1, p. 260,270-272
18. DAHAN J. “Effects of bite raising and occlusal awareness on tongue thrust în untreated children” , AJODO, Vol. 124, Issue 2, p.165-166
19. SZUHANEK C., GRIGORE A., ONISEI D., SCHILLER E., PODARIU A.C. “Indications Of Vacuum Formed Devices în Orthodontics”, MEDICINE ÎN EVOLUTION, NR. 2/2015,P. 326-329
20. SZUHANEK C., GRIGORE A., SCHILLER E., BRATU C., ONISEI D. “The role of the digital setup in the orthodontic treatment with plastic aligners” -Materiale plastice, vol.52, nr.4, 2015, p. 522-524
21. ARIKAN V. “Using Composite Res în Inclined Plane for the Repositioning of a Laterally Luxated Primary Incisor: A Case Report”, Eur J Dent. 2011 Jan; 5(1): 117–120
22. LAI H.H. E., YAO C.C.” Orthodontic treatment with a series of vacuum-formed removable appliances-case report”, J Dent Sci, 3(3),2008, p 167-173
23. BOYD R. “The Invisalign System în Adult Orthodontics: Mild Crowding and Space Closure Cases”, JCO, Volume 34, no. 4, April 2000, p 203-212
24. ANDREWS LF” The straight-wire appliance” British Journal of Orthodontics 1979;6:125-143

25. MCLAUGHLIN RP, BENNETT JC, TREVISI H. Systemized orthodontic treatment mechanics. London: Mosby; 2001
26. KUSY. R, WHITLEY Q. Friction between different wire-bracket configurations and materials, Elsevier, Vol. 3, Issue 3, 1997, p. 166
27. IONESCU E. „Anomaliile dentare”, Cartea Universitară, București, 2005
28. MUNTEAN A., MESAROS A., FESTILA D., MOLDOVAN M., BOBOIA S., MESAROS M. Comparative in vitro study for orthodontic adhesives relatively to sorption and solubility, PIM, 2015, AIP Publishing, vol.1700, Issue 1
29. TODEA C. Atitudinea de urgență în medicina dentară, Ed. Brumar, 2003
30. SCHILLER E.- Anomalii dentare. Ed.Mirton 2007
31. SZUHANEK C., SCHILLER E., GRIGORE A., POPA A., “Ghid de ortodonție”, Editura „Victor Babeș” Timișoara, 2016

ANNEXES

UMF Victor Babes Timisoara, Departament II, Facultatea de Medicina Dentara, Ortodontie V

MODEL ANALYSIS - ORTODONTICS

Student.....Year.....Group.....Teaching staff.....																																																																													
Patient's name.....Age.....Date of the examination.....																																																																													
Dentition: temporary mixed permanent																																																																													
Teeth chart																																																																													
<table border="1" style="width: 100%; border-collapse: collapse;"> <tr> <td style="text-align: center;">18</td><td style="text-align: center;">17</td><td style="text-align: center;">16</td><td style="text-align: center;">15</td><td style="text-align: center;">14</td><td style="text-align: center;">13</td><td style="text-align: center;">12</td><td style="text-align: center;">11</td> </tr> <tr> <td style="text-align: center;">55</td><td style="text-align: center;">54</td><td style="text-align: center;">53</td><td style="text-align: center;">52</td><td style="text-align: center;">51</td><td colspan="3"></td> </tr> <tr> <td colspan="2"></td><td style="text-align: center;">85</td><td style="text-align: center;">84</td><td style="text-align: center;">83</td><td style="text-align: center;">82</td><td style="text-align: center;">81</td><td colspan="2"></td> </tr> <tr> <td style="text-align: center;">48</td><td style="text-align: center;">47</td><td style="text-align: center;">46</td><td style="text-align: center;">45</td><td style="text-align: center;">44</td><td style="text-align: center;">43</td><td style="text-align: center;">42</td><td style="text-align: center;">41</td> </tr> </table>						18	17	16	15	14	13	12	11	55	54	53	52	51						85	84	83	82	81			48	47	46	45	44	43	42	41	<table border="1" style="width: 100%; border-collapse: collapse;"> <tr> <td style="text-align: center;">21</td><td style="text-align: center;">22</td><td style="text-align: center;">23</td><td style="text-align: center;">24</td><td style="text-align: center;">25</td><td style="text-align: center;">26</td><td style="text-align: center;">27</td><td style="text-align: center;">28</td> </tr> <tr> <td style="text-align: center;">61</td><td style="text-align: center;">62</td><td style="text-align: center;">63</td><td style="text-align: center;">64</td><td style="text-align: center;">65</td><td colspan="3"></td> </tr> <tr> <td colspan="2"></td><td style="text-align: center;">71</td><td style="text-align: center;">72</td><td style="text-align: center;">73</td><td style="text-align: center;">74</td><td style="text-align: center;">75</td><td colspan="2"></td> </tr> <tr> <td style="text-align: center;">31</td><td style="text-align: center;">32</td><td style="text-align: center;">33</td><td style="text-align: center;">34</td><td style="text-align: center;">35</td><td style="text-align: center;">36</td><td style="text-align: center;">37</td><td style="text-align: center;">38</td> </tr> </table>						21	22	23	24	25	26	27	28	61	62	63	64	65						71	72	73	74	75			31	32	33	34	35	36	37	38
18	17	16	15	14	13	12	11																																																																						
55	54	53	52	51																																																																									
		85	84	83	82	81																																																																							
48	47	46	45	44	43	42	41																																																																						
21	22	23	24	25	26	27	28																																																																						
61	62	63	64	65																																																																									
		71	72	73	74	75																																																																							
31	32	33	34	35	36	37	38																																																																						
Dental occlusion examination																																																																													
Area		Sagittal plane				Transversal plane				Vertical plane																																																																			
Frontal		Overjet.....mm				Dental midline: deviated yes/no right/left withmm				Overbite.....mm Open bite/deep bite																																																																			
Lateral		Angle's Cl molar I II III Angle's Cl canine I II III				Lingualized occlusion/lateral cross-bite				Supra occlusion /infra occlusion																																																																			
Upper arch						Lower arch																																																																							
Arch form						Arch form																																																																							
Symmetry						Symmetry																																																																							
Dental malposition						Dental malposition																																																																							
Dental abrasion						Dental abrasion																																																																							
Measured premolar value (MPV) (mm)						Measured premolar value (MPV)(mm)																																																																							
Measured molar value (MMV) (mm)						Measured molar value (MMV)(mm)																																																																							
Sum of incisors(SI)(mm)						Sum of incisors(SI)(mm)																																																																							
Calculated PV = (SIx100)/80 mm						Calculated PV = (SIx100)/80 mm																																																																							
Calculated MV=(SIx100)/64 mm						Calculated MV=(SIx100)/64 mm																																																																							
Pont's Index difference mm						Pont's Index difference mm																																																																							
Space analysis : Perimeter																																																																													
Upper arch (M-D diameter)						Lower arch (M-D diameter)																																																																							
1.6 mm	1.3 mm	2.6 mm	2.3 mm	3.6 mm	3.3 mm	4.6 mm	4.3 mm	1.5 mm	1.2 mm	2.5 mm	2.2 mm	3.5 mm	3.2 mm	4.5 mm	4.2 mm																																																														
1.4 mm	1.1 mm	2.4 mm	2.1 mm	3.4 mm	3.1 mm	4.4 mm	4.1 mm																																																																						
Dental perimeter mm						Dental perimeter mm																																																																							
Alveolar perimeter mm						Alveolar perimeter mm																																																																							
Difference +/- mm						Difference +/- mm																																																																							
Bolton Analysis																																																																													
Frontal Bolton						Total Bolton																																																																							
Sum 1.3-2.3 mm			Sum 3.3-4.3 mm			Sum 1.6-2.6 mm			Sum 3.6-4.6 mm																																																																				
Anterior Bolton ratio (normal value 77.2%)						Overall Bolton ratio (normal value 91.3%)																																																																							
Interpretation						Interpretation																																																																							
Dental cast analysis in mixed dentition(Tanaka and Johnston)																																																																													
Upper arch						Lower arch																																																																							
Sum of lower incisors mm						Sum of lower incisors mm																																																																							
Estimated width of 3,4,5 = sum of lower incisors/2 +11 mm = mm(in one quadrant)						Estimated width of 3,4,5 = sum of lower incisors /2 +10.5mm = mm(in one quadrant)																																																																							
Existing space for 3,4,5 (distal to the lateral incisor and mesial to the first molar)= mm						Existing space for 3,4,5 (distal to the lateral incisor and mesial to the first molar)= mm																																																																							
Left mm		Right mm		Left mm		Right mm		Left mm		Right mm																																																																			
Difference (-/+ mm)						Difference (-/+ mm)																																																																							
Left		right		total		Left		Right		total																																																																			

Extraoral examination			
<i>Facial /cephalic index</i>	brachycephalic	normocephalic.....	dolichocephalous
Frontal view at rest			
<i>Sagittal plane</i>	<i>Vertical plane</i>	<i>Transversal plane</i>	
Tip of the nose <ul style="list-style-type: none"> • Not deviated • Deviated to the left..... • Deviated to the right: Chin <ul style="list-style-type: none"> • Not deviated..... • Deviated to the left: • Deviated to the right: 	Vertical facial proportions <ul style="list-style-type: none"> • equals • larger..... • smaller..... Labial competence <ul style="list-style-type: none"> • present • absent Maxillary incisor display at rest: (medium value: 1.91-3.40)mm	Zy-Zy Distance:mm (medium value: M 137±4.3 ; F 130±5.3) Go-Go Distance :.....mm (medium value : M 97±5.8 ; F 91±5.9) Nasal base width:.....mm (medium value : M 35±2.1 ; F 30±1.9) Mouth width:.....mm (medium value : M 53±3.3 ; F 50±3.2)	
Frontal view during smile			
Interincisal lines deviations: (the facial midline is the landmark) <ul style="list-style-type: none"> ➤ maxillary: deviated left/right.....mm ➤ mandibulary : deviated left/right.....mm (mandibulary versus maxillary) <ul style="list-style-type: none"> • deviated left:.....mm 		Smile analysis: <ol style="list-style-type: none"> 1. Smile Arc (normally it follows the lower lip) 2. Buccal corridor (normal value: 13%) 3. Exposure of upper incisor and 	

<ul style="list-style-type: none"> • deviated right:.....mm <p>Occlusal plane cant: (normal value: $0^{\circ} \pm 2.8^{\circ}$)</p> <ul style="list-style-type: none"> • straight..... • inclined to the left • inclined to the right 	<p>gingival tissue (normal value : 2mm of gingival exposure)</p> <p>4. Gingival heights difference:</p> <ul style="list-style-type: none"> • central incisor –central incisor (ideal: 0 mm) • lateral incisor-central incisor (ideal: 0.4mm)
--	---

Profile

<p>Naso-labial angle (normal value: 102°)</p> <p>Fronto-nasal angle (normal value: 134°)</p> <p>Profile type</p> <ul style="list-style-type: none"> • convex • concave • normal <p>Lip prominence</p> <ul style="list-style-type: none"> • distalized/negative • severely distalized /negative • mezialized/positive 	<p>Labiomental sulcus</p> <ul style="list-style-type: none"> • pronounced • non pronounced..... • normal <p>Lip- E line distance (Pn-soft tissue Pog)</p> <ul style="list-style-type: none"> ➤ upper lip mm (normal value: -4 ± 2 mm) ➤ lower lip mm (normal value: 2 ± 2 mm)
--	--

Palpation

Facial complex integrity.....

Mandibular integrity.....

Emerging points of the trigeminal nerve.....

Ganglionic system.....

Muscles

<i>Group</i>		<i>hypotonic</i>	<i>normotonic</i>	<i>hypertonic</i>	<i>Pain presence</i>
Temporal					
Masseter					
Lateral pterygoid					
Medial pterygoid					
Tongue muscles					
Perioral muscles	buccinator				
	orbicular				
	-upper lip -lower lip				

Alar muscles (narinary compression) : slow comeback rapid comeback.....

TMJ examination:

- sound: - clicks -mouth closing
-opening.....
-reciprocal.....
- crepitus

- pain: absent.... present

- condyle movement : symmetric.... asymmetric....

- Mouth movement:mm
- Me point trajectory in the sagittal plane:
 - deviatedmm left/right
 - bayonet.....

Observations

.....

.....

.....

.....

.....

Patient: First name Family name Age.....

Assistant professor..... **Date**.....

Student **Group**.....

Intraoral examination: clinical parameters

Soft tissues analysis

1. Oral mucosa

Frenum: labial:.....

lingual:.....

Secondary/lateral frenum:.....

Jugal/soft palate/palate/tongue mucosa (pathological aspects) :

2. Periodontal status

Gums : colour:

texture:

gingival: contour

consistency:

Periodontal tissues: gingival pocket.....

recession.....

3. Hard palate

Height: mm :flat mediumhigh/ogival

Torus:pezent absent

Rugae:

Retroincisal papilla:

4. Tongue

Colour:

Shape :

Size :

Frenum insertion :.....

Position :

DENTAL ANALYSIS

1. Teeth numbering(the X-ray completes the medical examination)

- a. dental age:..... ani
- b. absent teeth:.....
- c. supranumerary teeth:.....

2. Dental status

- a. cavities:.....
- b. fillings:.....
- c. decalcification:.....
- d. enamel hypoplasia: ... general
 ... localized:
- e. teeth malformations:.....

3. Oral hygiene

good.... unsatisfactory.....

- plaque accumulations:
.....
- tartar:.... absent
 ... present:

4. Arch form and malpositions		
	<i>Upper</i>	<i>Lower</i>
Arch form		
Symmetry		
Spacing/crowding		
Malpositions	Quadrant 1:	Quadrant 3:
	Quadrant 2 :	Quadrant 4:
5. Dental occlusion		
Plane	<i>Frontal</i>	<i>Lateral</i>
Sagittal	Overjet:.....mm	Angle class:
Transversal	Dental midline: ->coincides ->deviatedmm left/right	Normal..... Lingual position..... Crossbite.....

Vertical	Overbite:.....mm	Supraocclusion: Infraocclusion:
Observations		
Patient: First name Family name Age.....		
Assistant professor..... Date..... Student Group.....		

Dinamic occlusal examination

Movement :

- Propulsion: Guidance
- Interferences: -working side
- passive side.....

- Lateral shift-left : Guidance
- Interferences: -working side
- passive side.....

- Lateral shift-right: Guidance:
- Interferences: -working side
- passive side.....

- Opening/closure:
 - maximum opening of the mouth:mm
 - Me trajectory in the sagittal plane:
 - deviatedmm left/right
 - bayonet movement

Compensatory curvatures of the dental arches (Curved Occlusal Planes) :

VON SPEE curve (sagittal occlusion curve)

- maxillary (ideal: convex downwards) :
- mandibular (ideal - concave upwards) :
- maximum height- inferior 1st molar (1-3 mm) :

WILSON curve (transversal occlusal curve: lingual inclination of the occlusal surfaces of the lower molars and vestibular inclination of the occlusal surfaces of the superior molars - vestibular cusps are higher than lingual cusps)
(ideal –concave upwards)

.....
.....

Oral functions examination

Respiratory function

- Oral breathing:
- Nasal breathing: the mirror test : positive.... negative.....

Respiratory obstacles:.....

Deglutition function

- infantile deglutition:.....
- normal deglutition:.....

Masticatory function

.....
.....

Phonatory function

.....
.....

Esthetic function

.....
.....

Bad oral habits and parafunctional activities

... absent ... present

.....
.....
....

Cephalometric chart			
Student.....Year,Group.....Assistant profesor			
Patient.....Age.....Date.....			
Skeletal Analysis			
Parameter	Normal value	Patient value	Significance
SNA	$82^{\circ} \pm 2^{\circ}$		
SNB	$80^{\circ} \pm 2^{\circ}$		
ANB	$2^{\circ} \pm 2^{\circ}$		
WITS	-3/+3 mm		
IMPA	$88^{\circ} \pm 2^{\circ}$		
FMA	$67^{\circ} \pm 3^{\circ}$		
FMA	$25^{\circ} \pm 3^{\circ}$		
Inter-incisal Angle	130°		
SeGn/PF	60+/-5°		
Ar-Se-N	123°		
Soft tissue Analysis			
Naso-labial angle	102		
Upper lip to E-line (Pn-Pog)	-4 ±2 mm		
Lower lip to E-line (Pn-Pog)	-2±2 mm		

DIAGNOSIS RESULTS

Diagnosis	skeletal	dental	soft tissue
sagittal			
transversal			
vertical			
Mandibular rotation	Anterior (Se Gn / PF < 55°)		Posterior (Se Gn / PF > 65°)

LABORATORY PRESCRIPTION

Patient's name age

Objectives:

.....
.....
.....
.....
.....

Appliance description:

.....
.....
.....
.....
.....

Data

Signature

.....