

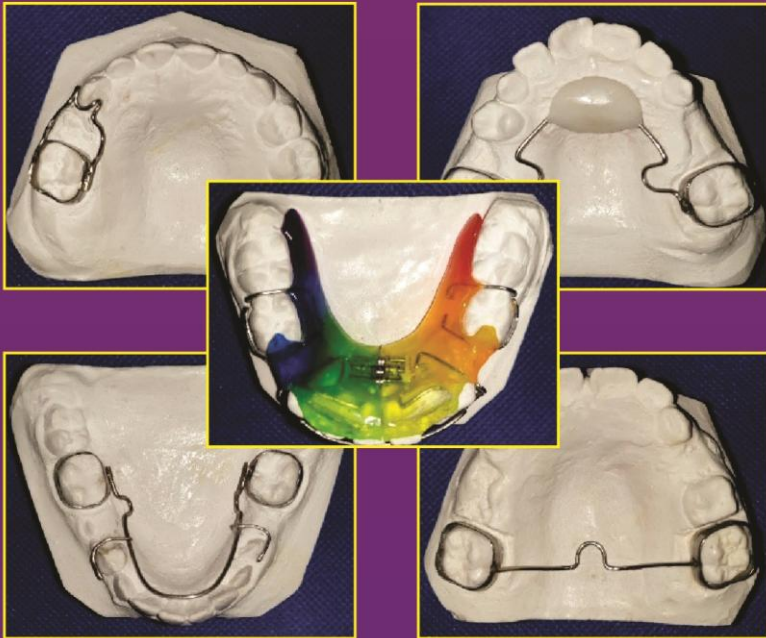

UMFT
Universitatea de
Medicină și Farmacie
„Victor Babeș”
din Timișoara

ALEXANDRU OGODESCU

**MAGDA LUCA EMILIA OGODESCU ADRIANA BĂLAN
ANDREEA IGNA CARMEN SAVIN DARIAN RUSU
ALEXANDRA BÂRCĂ**

SPACE MANAGEMENT IN PRIMARY AND MIXED DENTITION



TIMIȘOARA - 2019



Book authors:

ALEXANDRU OGODESCU

Senior Specialist in Orthodontics and Dentofacial Orthopedics
Senior Specialist in Pediatric Dentistry
Senior Specialist in General Dentistry
Doctor of Dental Medicine - Interdisciplinary Orthodontic Treatment
Competence in Laser Therapy in Dentistry
Professor Dr. Habil., Head of the Pediatric Dentistry Department of
"Victor Babeş" University of Medicine and Pharmacy, Timișoara

MAGDA LUCA

Senior Specialist in Orthodontics and Dentofacial Orthopedics
Specialist in Pediatric Dentistry
Doctor of Dental Medicine
Assistant Lecturer at the Pediatric Dentistry Department of
"Victor Babeş" University of Medicine and Pharmacy, Timișoara

EMILIA OGODESCU

Specialist in Orthodontics and Dentofacial Orthopedics
Specialist in Pediatric Dentistry
Specialist in General Dentistry
Doctor of Dental Medicine
Competence in Oral Implantology
Assistant Lecturer at the Pediatric Dentistry Department of
"Victor Babeş" University of Medicine and Pharmacy, Timișoara

ADRIANA BĂLAN

Senior Specialist in Orthodontics and Dentofacial Orthopedics
Senior Specialist in Pediatric Dentistry
Senior Specialist in General Dentistry
Doctor of Dental Medicine
Professor, Pediatric Dentistry Department of
"Gr. T. Popa" University of Medicine and Pharmacy, Iași

ANDREEA IGNA

PhD Student, Pediatric Dentistry Resident Doctor in the
Pediatric Dentistry Department of
"Victor Babeş" University of Medicine and Pharmacy, Timișoara

CARMEN SAVIN

Senior Specialist in Orthodontics and Dentofacial Orthopedics
Senior Specialist in Pediatric Dentistry
Doctor of Dental Medicine
Associate Professor at the Pediatric Dentistry Department of
"Gr. T. Popa" University of Medicine and Pharmacy, Iași

DARIAN RUSU

Senior Specialist in Periodontology
Specialist in Oral Surgery
Doctor of Dental Medicine
Associate Professor at "Victor Babeş" University of Medicine and
Pharmacy, Timișoara

ALEXANDRA BÂRCĂ

Pediatric Dentistry Resident Doctor in the
Pediatric Dentistry Department of
"Victor Babeş" University of Medicine and Pharmacy, Timișoara

Contributors:

NICOLETA ANDRADA STOICAN

Dentist

LARISA ONET

Dental Laboratory Technician
Laboratory Assistant at the Pediatric Dentistry Department of
"Victor Babeş" University of Medicine and Pharmacy, Timișoara

CRISTIAN MARCU

Dental Laboratory Technician
Dentist

Editura „Victor Babeș”

Piața Eftimie Murgu 2, cam. 316, 300041 Timișoara

Tel./ Fax 0256 495 210

e-mail: *evb@umft.ro*

www.umft.ro/editura

General director: Prof. univ. dr. Dan V. Poenaru

Director: Prof. univ. dr. Andrei Motoc

Collection:



Scientific Referee: Prof. univ. dr. Carmen Todea

Book cover and graphics: Petre Doda

CNCSIS Indicative: 324

© 2019 All rights to this edition are reserved.

Partial or full reproduction of the text, on any medium, without the written consent of the authors is prohibited and will be sanctioned according to the law.

ISBN 978-606-786-144-0

Table of Contents

ABBREVIATIONS	7
PREFACE	8
1. INTRODUCTION.....	9
2. GROWTH AND DEVELOPMENT OF THE STOMATOGNATHIC SYSTEM: THE STAGE OF PRIMARY AND MIXED DENTITION	11
2.1 MORPHOLOGY OF THE DENTAL ARCHES AND DEVELOPMENT OF OCCLUSAL REPORTS DURING GROWTH AND DEVELOPMENT OF THE STOMATOGNATHIC SYSTEM.....	14
2.2 SPACE RELATIONS IN THE CONTEXT OF PRIMARY INCISORS REPLACEMENT.....	19
2.3 SPACE RELATIONS IN THE CONTEXT OF PRIMARY CANINES AND PRIMARY MOLARS REPLACEMENT.....	21
2.4 THE SPACE BALANCE	23
3. CAUSES OF SPACE LOSS IN PRIMARY AND MIXED DENTITION	31
3.1 PERIODONTAL DISEASE THAT LEADS TO LOSS OF PRIMARY AND PERMANENT TEETH	37
4. THE CONSEQUENCES OF EARLY LOSS OF PRIMARY TEETH.....	46
5. SPACE MANAGEMENT IN PRIMARY DENTITION	51
6. SPACE MANAGEMENT IN MIXED DETITION	55
7. CLASSIFICATION OF SPACE MAINTAINERS.....	60

8. THE ROLE AND CONDITIONS WHICH THE SPACE MAINTAINERS HAVE TO FULFILL	65
9. THE MAIN TYPES OF SPACE MAINTAINERS.....	67
9.3 TRANSPALATAL BAR.....	80
9.5 THE LINGUAL ARCH.....	85
9.6. THE LIP-BUMPER.....	90
9.7 DISTAL SHOE INTRA-ALVEOLAR DEVICE	91
9.8. PREFABRICATED SPACE MAINTAINERS	95
9.9. SPACE MAINTAINERS MANUFACTURED IN THE PEDIATRIC DENTISTRY DENTAL OFFICE.....	102
9.10 PEDIATRIC CROWNS	105
9.11 REMOVABLE AND MOBILE SPACE MAINTAINERS	115
10. SPACE MAINTAINERS IN THE DIGITAL ERA ...	133
11. CLINICAL EXAMPLES AND EXERCISES REGARDING SELECTION OF THE APPROPRIATE SPACE MAINTAINERS FOR DIFFERENT CLINICAL SITUATIONS.....	142
REFERENCES.....	152

ABBREVIATIONS

ALP = aggressive localized periodontitis

ANUG = acute necrotizing ulcerative gingivitis

CAD = computer aided design

CAM = computer aided manufacturing

ECC = early childhood caries

GMP = generalized mesial position

SM = space maintainer

SS = stomatognathic system

PREFACE

The space maintainer has become a common therapeutic solution to current pedodontics. By protecting the growth and development of the stomatognathic system it is attempted to reduce both the increased number of dento-maxillary abnormalities and the necessity for orthodontic treatment.

The continuous evolution of materials and technologies used in the practice of pediatric dentistry, the increase in the number of skeletal space maintainers, prefabricated or made by CAD/CAM technology, required the elaboration of an English edition, revised and supplemented with both clinical and technological elements related to dental techniques.

In the meantime, introducing the residency and the specialty of Pediatric Dentistry in Romania, required the development of certain chapters, as well as the broad presentation of the evolution of clinical cases with different types of space maintainers.

We hope that this edition will capture the interest of future English department students, residents, dental technicians and all dentists who passionately care for the oral health of children.

Professor Dr. Habil. Alexandru Ogodescu

1. INTRODUCTION

Space management is one of the most important themes in pediatric dentistry, given its influence on the growth and development of the stomatognathic system. It is a boundary between pedodontics and orthodontics, which dentists need to understand and apply with clinical sense and tactfulness.

Early loss of primary teeth compromises the eruption of permanent teeth, leading to the appearance of dento-maxillary abnormalities that require subsequent complex, long-lasting and expensive orthodontic treatments.

The space maintainer, a relatively simple therapeutic element, but complex as applicability and follow-up, helps us in the limit situations where, due to the pathology of the root furcation, a primary tooth has to be extracted without compromising afterwards the evolution of the dental eruption.

Concerns about pediatric crowns and space maintainers date from the beginning of my teaching career (2000) when, along with two visionary students, passionate about pediatric dentistry, to whom I coordinated their bachelor's degree thesis: Dr. Emilia Augustinov (Ogodescu) and Dr. Varga Imola, we were able to apply the first pre-fabricated pediatric crowns and the first fixed space maintainers as band and loop, therapeutic solutions which at that time, in Pediatric-Orthodontic Clinic in Timisoara had only theoretical resonances.

At present, within the Timisoara Pediatric Dentistry Discipline, the entire teaching staff is currently applying prefabricated pediatric crowns (trying to replace the metal with zirconia, aesthetic crowns) and the entire space-maintaining panoply. The students of the Faculty of Dentistry at the "Victor Babeş" University of Medicine and Pharmacy Timișoara learn, both theoretically and practically, the use of these therapeutic methods, acquiring practical skills that in 2000 we only dreamed about... but taking this dream more further away we can say that today the era of endless sessions of lavation in primary teeth with infected root channels is long forgotten, the primary tooth is treated correctly in a single session, and when restorative therapy fails, an optimal space management is provided for a undisturbed eruption of permanent teeth. We do not monitor the gangrene anymore, but the evolution of space maintainers and the growth and development of the stomatognathic system in today's children...who are more joyful and more confident.

By performing quality and complex pediatric dental treatments, all dental practitioners who treat children contribute to the decrease of the large number of dento-maxillary abnormalities that we see in current generations, thus contributing to the improvement of their oral health.

Modern diagnostic technologies, current therapeutic and technological possibilities, the emergence of prefabricated space-maintaining systems, the accumulated experience led me to synthesize them along with my colleagues in this book, which we hope will be useful for both dental students and detists.

2. GROWTH AND DEVELOPMENT OF THE STOMATOGNATHIC SYSTEM: THE STAGE OF PRIMARY AND MIXED DENTITION

Within the Textbook of Orthodontics, under the editing of Prof. Samir E. Bishara, Robert N. Stanley, a professor at the Iowa Orthodontic Department, human growth is defined as follows: a complex process which cannot be described with a simple definition, it is a game between heredity and the environment, it is dimensional growth and change, which takes place differently and in different rates throughout life (Bishara SE, 2001).

It encompasses human development from a physical, mental, psychological, social and moral point of view (Krogman WM, 1972). Physical growth is a disturbing sequence of events, which converts a cell into an infinitely complex individual (Bishara SE, 2001).

From a biological point of view, growth occurs in both hard and soft tissues, and the interaction between them lies in the center of attention in the research that is being done at present, as well as in the monographs written on this topic, internationally.

In most medical papers, the term "*growth*" is always accompanied by the term "*development*". In the OFX 98, the verb "*to grow*" means to increase gradually, to become larger as a result of the vital processes within the body, to develop (in

humans, animals and plants or parts of them). The verb "*to develop*" (about beings) means to evolve, to gradually increase (in a physical sense), to increase (about human beings), to evolve gradually (as regards intellect). The first synonym of the verb "to develop" is the verb "to evolve", followed by the verb "to grow".

These terms are indeed linked to each other, but *they are not synonymous*, especially when we refer to them from a biological point of view. *Through growth we understand dimensional enlargement and through development we understand evolution*, which does not necessarily imply dimensional growth in every sense.

Professor William Proffit, in 2012, states that the term „growth” is most often used to express dimensional growth or number, while development is an increase in complexity. This may even reflect a dimensional reduction or the disappearance of some tissues in the body. It is well known that a specialization of tissues in performing functions can be done in parallel with dimensional reduction or loss of other functions (reduction of potential at other levels). Thus, we can say that *while growth is an anatomical phenomenon, development is a physiological or behavioral phenomenon*.

Interesting is Enlow's explanation regarding the terminology. From his point of view, *growth* is the equivalent of magnitude changes, but it does not imply knowing how the phenomena are occurring. It is in fact a more general term, easy to use by clinicians. But if we ask questions about what is happening and how it is taking place, we need to add the

descriptive term "*development*" through which we explain the phenomena. This term has connotations on maturation processes, involving a progressive cellular and tissue differentiation, emphasizing the *biological mechanisms that take place during growth* (Enlow D et al., 1996).

In the intrauterine life and during the first months of postnatal life, the rate of growth and development is very high. By the fourth month of extrauterine life, the weight recorded at birth doubles (the first *postnatal growth peak* is recorded). If the growth process would continue at the same rate, at the age of 50 years old, a man would weigh 450 kg and would be 15 meters tall. During childhood, there are other periods of acceleration of growth (*peri-pubertal growth peak*).

When we attempt to characterize growth, there are three basic concepts which are to be used: *the growth pattern* (refers to how the proportions change over time; for example: the normal growth pattern of the body respects the cranio-caudal gradient of growth, and various tissues of the body have a different rate of growth), *the variability* (it reflects the individuality of each human being; it is important to delimit the normal range of variation, by statistical methods; in this sense it is important to determine the standards for a certain age; the deviation at a given time in the pattern of growth had previously may have pathological significance) and the *timing of growth* (the same event can take place at different times in each individual, each person has his own "biological clock"). Although we are accustomed to our age being chronologically measured, we all have a *biological age*, and the inter-individual

variability in the growth calendar could be greatly reduced if we take into account the latter (Proffit WR et al., 2012).

The factors influencing growth and development are: genetic, neuroendocrine, nutritional, secular tendencies, the seasons and the circadian rhythm, disease and cultural factors (Bishara SE, 2001).

Only a few decades have made great progress in this area. If we ask ourselves about what to do in the future, it is worthy today to remember the words of Professor Moyers, who expressed his support at the end of his career (1990) for future research in this field: "We have still have important research to accomplish and we face so many challenges in front of us, if we think about the expectations of patients, colleagues and society. I would have liked to be able to take it right from the beginning. "(Mc Namara JA, 2004).

2.1 MORPHOLOGY OF THE DENTAL ARCHES AND DEVELOPMENT OF OCCLUSAL REPORTS DURING GROWTH AND DEVELOPMENT OF THE STOMATOGNATHIC SYSTEM

Dental eruption, dental arches development, and occlusal plane development are processes that are closely related to each other, which are carried out simultaneously during the growth and development of the stomatognathic system. Therefore, the morphology of dental arches and the development of occlusal plane may be theoretically subdivided and studied in the three stages through which dentition passes:

primary, mixed and permanent. These two processes are also called the dynamics of intra- and inter- dental reports.

The morphology data of the primary and permanent teeth, the morphology data of the dental arch, constantly changing during the growth and the eruption of the teeth, and the evolution of the occlusal reports from the eruption of the first primary tooth to the end of the eruption of the permanent teeth, are particularly important for each dentist.

The dental arch dimensions change with growth; therefore, it is necessary to distinguish between the changes induced due to treatment with orthodontic appliances and those that result from natural growth. Changes that occur naturally in children that are not orthodontically treated should be characterized by the standard values, which can be used in the assessment of the changes that occur during orthodontic treatment.

Stillman analyzed the growth of the *intercanine distance* both in the upper and lower jaw until the age of 25, and has found that this distance continued to grow in the maxillary arch to up to 13 years of age, and in the mandible to up to 12 years of age, remaining stable afterwards. Boys had wider arches compared with girls (Stillman JH, 1964). Bishara also found the existence of larger transverse dimensions of the boys' arches compared to the girls'. This has led to a significant increase in the maxillary inter-canine distance to boys and girls aged between 3 years and 13 years. Between 13 years and 45 years there has been registered a slight decrease in this distance, but this was only significant for girls aged between 26

years and 45 years. As regards the *mandibular inter-canine distance*, this has increased significantly in girls up the age of 13 years and in boys up to the age of 8 years. Afterwards, there was a decrease in this distance, which was significant between 26 and 45 years for both sexes (Bishara SE et al., 1997).

The changes occurring in the dimensions of dental arches between 6 and 18 years were illustrated by Moores in an article published in *Am J Orthod* in 1969 and have been reproduced by Bishara in the 2001 edition of the *Textbook of Orthodontics* (Fig. 2.1).

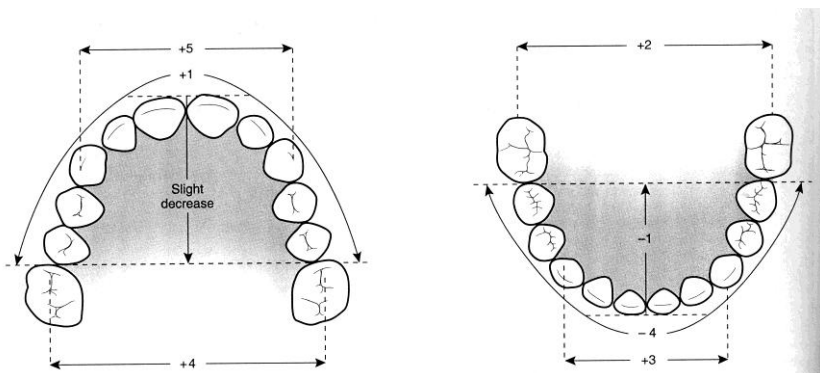


Fig. 2.1 The average changes (in mm) that take place at the dental arches between 6 years and 18 years (Bishara SE, 2001)

These modifications, after Moores, have been also presented in the national literature. Thus, Irina Zetu and Mariana Păcurar describe these changes in the first volume of the book „The Straight Arrow Technique, Necessary Analyzes” between 5 and 18 years, the dental arch length is decreasing with 2 mm in the upper jaw and 3 mm in the lower jaw, and the perimeter of the maxillary arch increases on average with 1.3

mm in boys and 0.5 mm in girls and decreases in the mandibular arch by approximately 3.4 mm in boys and 4.5 mm in girls; between 5 and 8 years the anterior width between the canine points increases by approximately 4 mm in the upper jaw and 3 mm in the lower jaw (Zetu I, Păcurar M, 2003).

The achievement of the occlusal reports begins in intrauterine life by establishment of the sagittal reports between the maxilla and the mandible. Subsequently, the *postnatal preeruptive stage* is characterized by the presence of an anterior open bite and contact of the lateral edentulous ridges. In most cases, the maxillary alveolar ridge circumscribes the mandibular ridge (Bishara S, 2001). Between 6 and 30 months, primary teeth eruption occurs and the first occlusal reports are established. Starting from the age of 30 months, the functional phase of the dental arches and occlusal reports begins, which extends until the age of 6, and is subdivided into the primary morphology stage of primary dental arches (up to 4 years) and stage of secondary morphology (ranging from 4 years to 6 years) (Bratu E et al., 2005).

From the abundance of parameters that characterize the development of dental arches and occlusal reports in these stages (the morphology of the arches, occlusal surfaces, overbite, overjet, spacing, clogging, primate spacing) and which may be described and investigated through extensive studies, we stopped of the *flush terminal plane*, which is of particular importance in the establishment of the first permanent molar relationships.

The flush terminal plane can have three forms, clinically: *straight*, *in mesial step* and *in distal step*. Anderson determined the following percentages in Caucasian children: 60% have a flush terminal plane in mesial step (40% of the children have a flush terminal plane in mesial step under 2 mm and 20% of them have a flush terminal plane of over 2 mm); 30% shall present a straight flush terminal plane and 10% a flush terminal plane in a distal step (English JD et al., 2009).

Mixed dentition is one of the most dynamic periods, dominated by both the development of dental arches and the occlusal reports. From the multitude of aspects that can be researched, we will stop on the possibilities of solving the existing space deficiency due to the dimensional differences between the primary and permanent teeth and *the establishment of the occlusal reports of the first permanent molars*.

After Baume, detailed rules for the establishment of a neutral relation of the first permanent molars are: closure of the primates spaces (the lower diastema is wider than the upper one) with mesial migration of the two primary molars and the first permanent molar and thus shortening of the lower dental arch; use of the space stock (leeway space), which makes it possible for the permanent molars to migrate mesially; the distal eruption of the first permanent molars, when the maxillary is well developed (Bratu E et al., 2005).

2.2 SPACE RELATIONS IN THE CONTEXT OF PRIMARY INCISORS REPLACEMENT

The dimensional differences between the permanent incisors and the primary incisors are highlighted especially in the early stages of mixed dentition (Fig. 2.2).

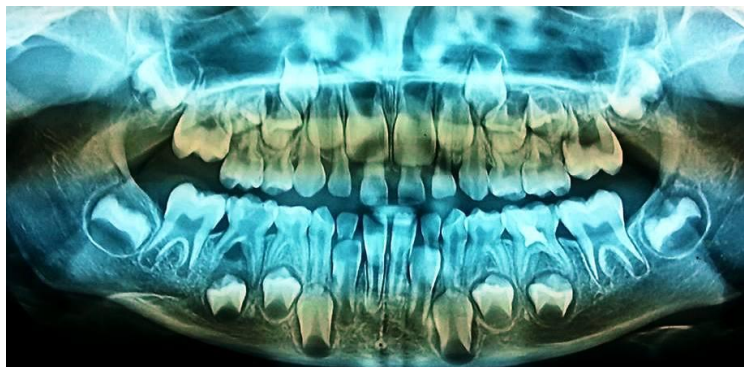


Fig. 2.2 The orthopantomography of a 6 year old patient, in which we can notice the dimensional reports between the permanent and primary incisors (Collection of the Department of Pediatric Dentistry)

The sum of the mesio-distal dimensions of the permanent superior incisors is 8 mm higher (the size is equivalent to a permanent upper lateral incisor) than the sum of the mesio-distal dimensions of the primary superior incisors. The mandibular difference is smaller (5-6 mm), which is equivalent to the mesio-distal size of a permanent inferior lateral incisor (English JD et al., 2009).

Regarding the upper jaw, there are some *natural compensatory mechanisms* for this space deficiency, that occurs during their eruption: the permanent incisors have a more vestibular axis of eruption, and they erupt on a larger

circumference compared to the primary incisors (this is the most effective mechanism); during their eruption, they exert pressure on the adjacent teeth (it is known as the „pushing effect”), resulting in the gradual closure of the existing spaces between the primary teeth (e.g.: the permanent central incisors exert pushing effects on the primary lateral incisors, and the permanent lateral incisors exert pushing effects on the primary canines); the transverse growth of the maxilla due to the mid-palatal suture. These compensations usually occur and generate a *dento-alveolar disharmony with physiological spacing* (the well-known „ugly duckling stage”).

When these compensations cannot occur, we encounter dental crowding or crossbite, especially in the maxillary lateral incisors, due to the more palatal localization of the germs of these teeth (English JD et al., 2009).

In the mandible, *the compensatory mechanisms are deficient*. Only one of the mechanisms presented for the upper jaw is also preserved in the mandible: the pushing effect. The eruption of the inferior incisors does not occur on a more vestibular axis compared to the primary incisors and the transversal growth does not occur at the mandible due to the early closure of the sutures at this level.

When spacing between primary teeth is insufficient (spaces should exceed 5-6 mm), dental crowding is frequently present at this level and is called "*dento-alveolar disharmony with physiological crowding*" (English JD et al., 2009).

2.3 SPACE RELATIONS IN THE CONTEXT OF PRIMARY CANINES AND PRIMARY MOLARS REPLACEMENT

The space for permanent teeth that do not have primary predecessors (6-year molars, 12-year molars and third molars) is obtained through the growth mechanisms that occur in the jaw bones: in the upper arch there is a posterior growth in the maxillary tuberosity, and at the mandible there is a bone apposition on the posterior edge of the mandibular ramus and resorption on the anterior edge of the mandibular ramus. These are accompanied by another mechanism: the mesial migration of the first permanent molars, due to the space excess (the well-known leeway space).

Leeway space has a size of 2-2.5 mm in the mandible and 1-1.5 mm in the maxilla. This is mainly due to the dimensional difference between the second primary molars and the permanent premolars, which is 2.7 mm in the mandible (also known as *E-space*) and 2 mm in the maxilla. To this is added the dimensional difference between the first primary molars and the first permanent premolars, which is 0.9 mm in the mandible and 0 mm in the maxilla and the dimensional difference of the primary and permanent canines that is -1 mm in both arches (Fig. 2.3). The mandibular space stock is about 1.5 mm larger than the maxillary space stock (van Waes H, Stöckli P, 2001).

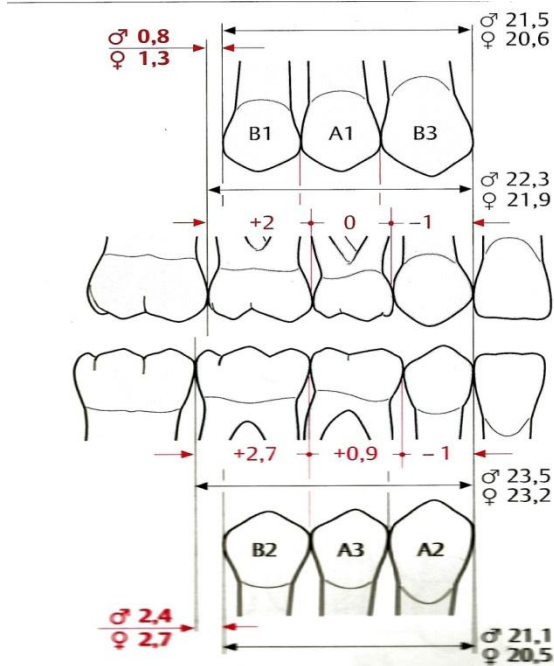


Fig. 2.3 The average mesio-distal dimensional reports between the primary molars and canines and the permanent premolars and canines (van Waes H, Stöckli P, 2001)

During normal occlusal development, the anterior migration of the molars, which is more pronounced at the mandible, uses 2 mm of the leeway space. Physiological crowding in the anterior segment can also be reduced on the basis of leeway space, by distal migration of permanent canines (English JD et al., 2009).

The changes that take place at the dental arches are due to bone growth and dental eruption, but are also due to the occlusal evolution. The eruption of the central and lateral incisors results in an increase in the length of the dental arch,

and the mesial migration of the molars causes it to decrease. At the maxillary the total length of the dental arch is constant between 3 and 15 years and at the mandible is slightly higher at 3 years compared to its length determined at 15 years (English JD et al., 2009).

2.4 THE SPACE BALANCE

The first step in achieving the optimal space management in primary or mixed dentition is represented by the realization of a correct study model and its analysis. Elements of analysis include: dental and alveolar morphology, the sequence of eruption and dental age analysis, occlusal reports analysis and occlusal development, achievement of the space balance and to highlight the emergence of possible malocclusions.

The study models are made, especially during the critical period of 6-12 years, at intervals of 1 year. One of the important purposes of conducting study models is to analyze the space in mixed dentition and to highlight the evolution of intra- and inter-arch reports.

Most frequently, orthodontic problems occur where there is an inadequate space for the eruption of permanent teeth.

Early assessment of the available space as well as space required, allows early intervention to prevent the development

of malocclusion, with no need for subsequent orthodontic treatments, long-lasting, expensive, and with uncertain results.

The objective of space analysis is to answer the following question: is there enough space for the permanent tooth to erupt? Determining the size of the canines and the premolars that have not yet erupted, is an important factor in assessing the child's occlusion.

Performing this space analysis is often indicated in the following situations: premature loss of primary canines; rotation or obstruction of lateral incisors due to space loss; ectopic eruption of the first permanent molars; the existence of a cross-bite occlusion, or the existence of a flush terminal plane in distal step.

According to Fields and Proffit (1998), the basic principles of spatial analysis in mixed dentition are as follows:

1. The presence of the first permanent molars and permanent incisors on the dental arch
2. The permanent successors teeth are in the process of formation;
3. There is a relationship / dimensional formula between the permanent teeth that have not yet erupted and the primary teeth;
4. There is a difference in size between canines, primary molars and the permanent successors. The mesio-distal size of canines and primary molars is greater than that of the permanents that will erupt in their place. Nance

called this space difference "leeway space", which he estimated at 0.9 mm for half the maxillary arch and 1.7 mm for half the mandibular arch.

Nance also proposes in 1947 a conventional space analysis, which compares the amount of the *available space* (at alveolar level) for the alignment of the teeth with the required space for proper alignment.

$$\textit{The space balance} = \textit{Available space} - \textit{Required space}$$

The available space is obtained by measuring the perimeter of the alveolar process, from the mesial side of the first permanent molars from one side of the arch to the mesial side of the other (for example from 1.6 to 2.6).

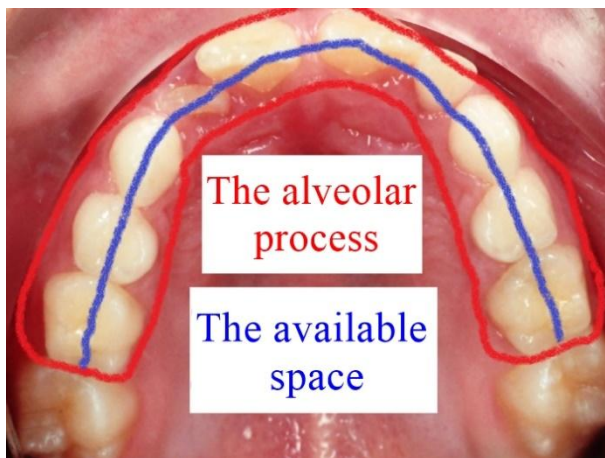


Fig. 2.4 The available space (blue) always refers to the alveolar process (red) and it is measured midway between the vestibular-oral distance of the alveolar process, mesial of the two 6-year-old molars

(Collection of the Department of Pediatric Dentistry)

This can be achieved by dividing the dental arch into segments, which can be measured as linear approximations of the alveolar process, or with a piece of pre-curved wire, corresponding to the middle (in vestibular-oral direction) of the alveolar process between the two molars (Fig. 2.4).

The required space is the sum of the mesio-distal dimension of the erupted mandibular or maxillary permanent incisors and the mesio-distal dimension of canines and non-erupted premolars.

The size of the non-erupted teeth can be obtained using one of the following methods:

- Tooth measurement on radiography (retro-alveolar, orthopantomography), calculating the magnification coefficient using of the rule of three;
- Using a prediction table (e.g., Moyers);
- Combining the two methods.

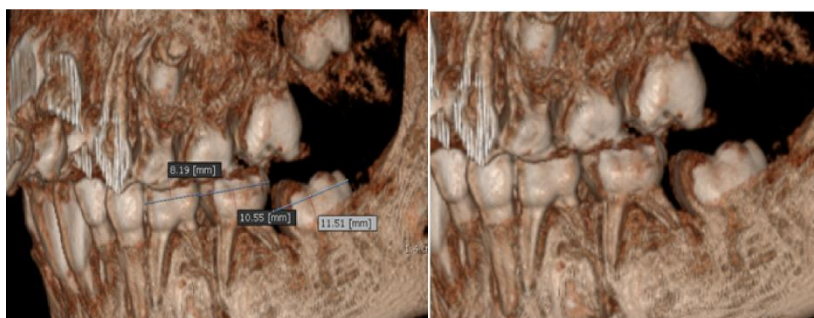


Fig. 2.5 Three-dimensional images obtained with CBCT highlight the reports between primary teeth and their permanent successors (Collection of the Department of Pediatric Dentistry)

The latest imagery technology, such as cone beam computed tomography (CBCT), allows a three-dimensional view of the scanned areas, allowing for an extremely accurate dimensional measurement of the teeth to be used in the space balance, as well as an accurate reporting between the dimensions of the primary teeth and those of the permanent successors (Fig. 2.5-6).

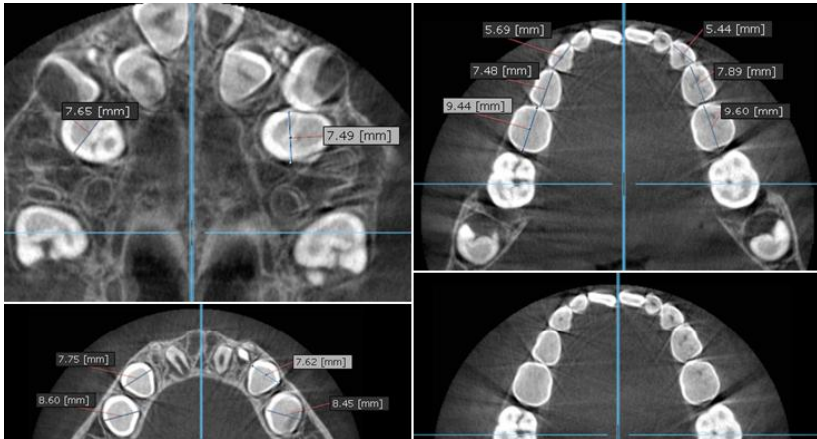


Fig. 2.6 The CBCT technology allows a precise dimensional assessment of the teeth to facilitating the achievement of the spatial balance (Collection of the Department of Pediatric Dentistry)

In the majority of cases, achieving the space balance is based on *Tanaka and Johnston's analysis*. It is recommended as a predictable technique because it has an acceptable accuracy, does not require radiography, or prediction tables with average values and predicts the average size of canine and non-erupted premolars.

At the mandible, the sum of the estimated size of the canine and of the two premolars for a mandibular quadrant is calculated by dividing the lower incisive sum (sum of the mesio-distal dimensions of the four lower permanent incisors) into two, plus 10.5 mm.

At the maxillary, the space balance is also calculated using the lower incisors, adding to the half of the incisive lower sum 11 mm.

Mandible: $C + PM1 + PM2 = \text{lower incisive sum} / 2 + 10.5 \text{ mm}$

Maxillary: $C + PM1 + PM2 = \text{lower incisive sum} / 2 + 11 \text{ mm}$

The space balance may be negative, indicating a space deficiency, or positive, indicating an excess of space.

Negative space balance indicates the presence of dento-alveolar disharmony with crowding, classified by gravity as follows (Bratu E et al., 2005):

Space deficiency less than 2 mm = slight crowding;

Space deficiency of 2-4 mm = moderate crowding;

Space deficiency of 5-9 mm = serious crowding;

Space deficiency of 10 mm or more = severe crowding.

Applying a *passive* space maintainer is only indicated in the case of a space deficiency of maximum 2 mm, while in other cases it is necessary to regain the space. If the space balance is positive, indicating an excess of space in the dental arch, the application of a space maintainer is no longer mandatory.

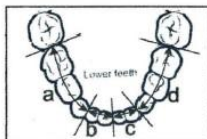
However, it should be emphasized that neither the conventional analysis nor the Tanaka and Johnston's method take into account the axial inclination of the lower front teeth, the effects of curve of Spee, the facial profile, the inclination or the facial profile of the different ethnic groups, any of which may affect the crowding value and the necessary space obtained during the analysis, a more thorough assessment of the space and the completion of the specific medical file (Picture 2.7).



The space balance in Mixed Dentition

Patient's Name:.....CNP:..... Examination Date:.....
 F.O. No:..... Model No:..... Medic:..... Student:.....

The space Analysis of Mandible



Available spaces:

- a).....mm
- b).....mm
- c).....mm
- d).....mm
- Total :.....mm

Necessary spaces:

- 1. Total length of Lower Incisors:.....mm
- 2. Sum of D(m-d) and c+pm1+pm2 left.....mm
- 3. Sum of D(m-d) and c+pm1+pm2 Right.....mm
- Total :.....mm

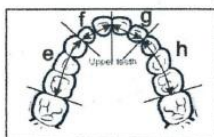
(TLI) Total length of Lower Incisors (Mesio-distal diameter of the 4 lower Incisors)mm (1)
 1.2.....mm 1.1.....mm 3.1.....mm 3.2.....mm

Tanaka & Johnston Space Analysis: (2) = (3) = 1/2 of Lower Incisors' total Length (TLI) + 10.5 mm

Space Balance in the mandibular level:.....mm (Available-Necessary)

Conclusion:.....

The space Analysis of Maxilla



Available spaces:

- e).....mm
- f).....mm
- g).....mm
- h).....mm
- Total :.....mm

Necessary spaces:

- 1. Total length of Upper Incisors:.....mm
- 2. Sum of D(m-d) and c+pm1+pm2 left.....mm
- 3. Sum of D(m-d) and c+pm1+pm2 Right.....mm
- Total :.....mm

(TLU) Total length of Upper Incisors (Mesio-distal diameter of the 4 upper Incisors)mm (1)
 1.2.....mm 1.1.....mm 2.1.....mm 2.2.....mm

Normal Dentition Macrodonτία Microdonτία

Tanaka & Johnston Space Analysis: (2) = (3) = 1/2 of Lower Incisors' total Length (TLI) + 11 mm

Space Balance in the maxillary level:.....mm (Available-Necessary)

Conclusion:.....

Reduction of the support area through temporary tooth loss:.....

Occlusion at the level of permanent primates:

- Right Hemiarch: Angle's Class I Angle's Class II Angle's Class III
- Left Hemiarch : Angle's Class I Angle's Class II Angle's Class III

Diagnostic:.....

Treatment :.....

Picture 2.7 The space balance file for mixed dentition designed and used in the Department of Pediatric Dentistry, Timișoara

3. CAUSES OF SPACE LOSS IN PRIMARY AND MIXED DENTITION

Space loss in primary or mixed teeth is due either to general causes or to local causes.

Thus, among the **general causes** we can list:

- endocrine disorders
- the underdevelopment of maxillary tuberosity due to bone formation delays

The **local causes** are:

- the proximal extended caries
- occlusal and vestibular, untreated caries
- nursing bottle caries
- periodontal diseases leading to loss of primary and permanent teeth: localized and generalized aggressive periodontitis
- dento-alveolar trauma

Endocrine disorders (e.g.: hyperthyroidism) cause premature exfoliating of primary teeth, accelerated eruption of permanent teeth, eruption disorders, disturbance of the eruption sequence.

The underdevelopment of maxillary tuberosity due to bone formation delays is associated with a high position of the tooth bud of the first permanent molar, its occlusal surface facing forward.

From its high position, the permanent molar seeks to reestablish its direction, exerting pressure on the roots of the

second primary molar, which results in a faster root resorption with its loss and the mesial eruption of the first permanent molar.

This phenomenon has been named by Schwarz, Hotz and Reichenbach: *undermining resorption*, a clinical entity that we can define as *pathological resorption by undermining* (Fig. 3.1).

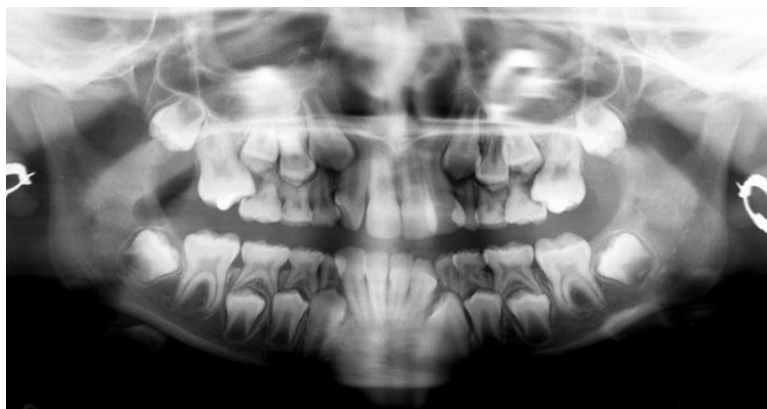


Fig. 3.1 Pathological resorption, by undermining of the distal roots of the upper second primary molars (5.5, 6.5), due to the pressure exerted by the upper first permanent molars (1.6, 2.6)
(Orthopantomography - Collection of the Department of Pediatric Dentistry)

Pathological resorption, by undermining, is an extremely complex clinical entity that requires a careful approach to avoid a loss of space at this level.

Another situation that may lead to early loss of the two primary upper molars is represented by a normally developed tuberosity, in parallel with an early development of the permanent second and third permanent molar, which exert pressure on the first permanent molar and move it mesially, finally causing the early root resorption of primary molars (Picture 3.2).

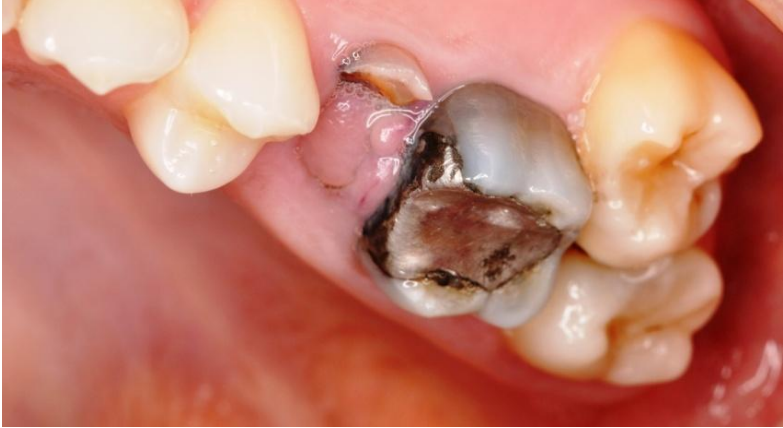

Fig. 3.2 The underdevelopment of maxillary tuberosity with ectopic eruption of the second permanent molar and the eruption of the third permanent molar (Collection of the Department of Pediatric Dentistry)

The proximal, evolutive, extended, untreated caries leads to reduction of the mesiodistal dimension of the primary tooth, thus shortening the arcade and reducing the space required for permanent successors. The proximal caries of a primary first molar with the collapse of the proximal edge and destruction of the distal surface, leads to the mesial migration of the second primary molar and the first permanent molar (Fig. 3.3).

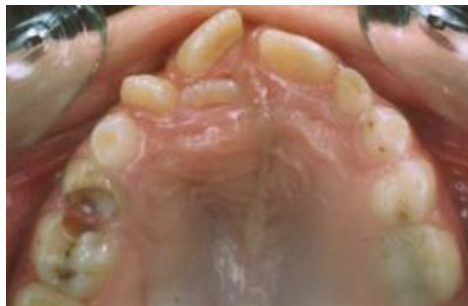

Fig. 3.3 Proximal afront caries in primary molars from quadrant 5 (Collection of the Department of Pediatric Dentistry)

Proximal caries develop without symptomatology, and the lesion becomes painful only when the marginal edge collapses, allowing the dental papilla to be compressed under masticatory pressures. The child complains of an acute pain, accentuated after meals.

This form of cavity is rapidly spreading in depth, reaching the tooth pulp temporarily. Progression to the pulp may be asymptomatic, leading to necrosis and eventually installing cellulite. Only systematic radiological detection allows the early treatment and preservation of the vital dental pulp of these primary teeth. In this case, at the debut of the lesion, the tooth has a normal coloration, but the dental tissues are deteriorated and dentinal sensitivity is perceptible. The highlighting of the pulp horn is frequent, especially in the first primary molar.

The stationary caries, located on the occlusal, vestibular or oral surfaces, if left untreated, can lead to pulp complications (gangrene, abscess, furcation pathology). The occurrence of furcation pathology, confirmed by radiological examination, is an absolute indication for primary tooth extraction due to the risk of damaging of the underlying permanent dental bud (Fig. 3.4).

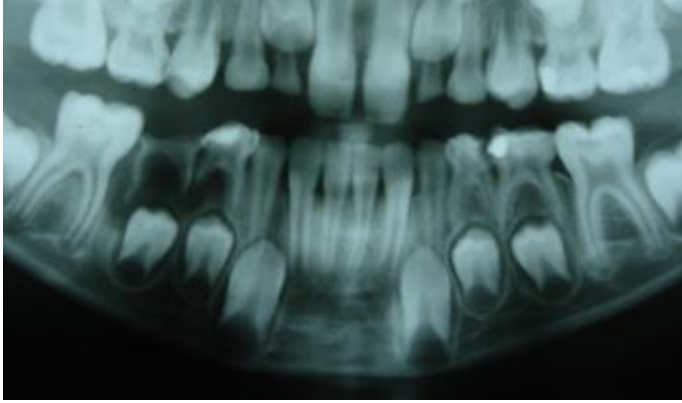


Fig. 3.4 Accentuated radiolucent areas at the level of the furcation of right mandibular primary molars: the furcation pathology, Orthopantomography (Collection of the Department of Pediatric Dentistry)

Uncomplicated pulp disorders should be treated by conservative methods to keep the primary tooth on the arch, as this is the best space maintainer. Pre-fabricated pediatric crowns are an excellent way of restoring primary teeth with large carious destructions, bulky obturations, or with or pulpotomy or pulpectomy.

Nursing bottle caries and rampant caries are two common forms of early childhood caries - ECC (Fig. 3.5, Fig. 3.6). They expand rapidly into the surface and in depth, often involving all teeth, with the unfavorable consequences outlined above. Tooth damage is precocious and occurs right after teeth eruption. The most affected areas are the vestibular and palatal area of the superior incisors, but they can spread to all erupted teeth at a certain time. Thus, the first affected group is that of upper incisors, followed by the first molars, canines and second primary molars. Due to the protection of the soft parts and the vicinity of the submandibular and sublingual glands,

mandibular incisors are less affected. There are situations where inferior teeth are also affected and the term used in this case is "rampant caries".

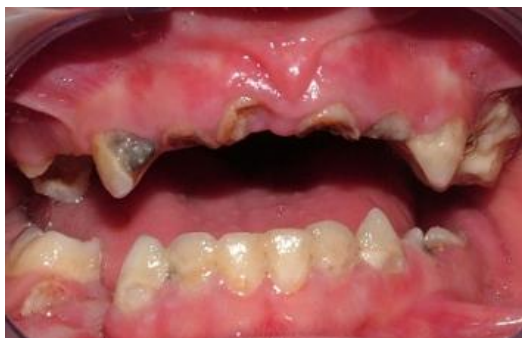

Fig. 3.5 Nursing bottle caries with precocious destruction of the primary upper frontal group (Collection of the Department of Pediatric Dentistry)

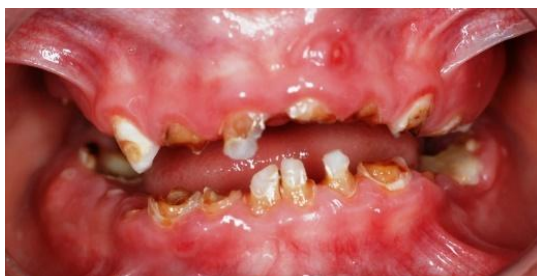

Fig. 3.6 Rampant caries with massive coronary destructions involving all primary teeth (Collection of the Department of Pediatric Dentistry)

Trauma of primary and permanent young teeth occurs primarily on frontal teeth. In young children, due to the resilience of the alveolar bone, the most common forms of trauma are intrusion, partial and total luxation, crown and root fractures being less common.

Intrusion is the result of a shock directing the tooth in apical direction. The upper front group is most affected.

Immediate replacement, or expectancy attitude until spontaneous repositioning of the tooth, are the two therapeutic alternatives.

Partial luxation is the result of an antero-posterior shock with frequent interposition of an object. The spontaneous recovery of the tooth is observed in most cases. *Total luxation* (=avulsion) is the loss of the tooth from the alveolus. However, the success of its repositioning depends on the time elapsed from the moment of the trauma, and in some cases there are failures.

The crown, root, and the crown-root fractures are treated by conservative methods, but often the extraction of the compromised tooth is needed. In all cases, clinical and radiological monitoring is required to diagnose possible pulp complications or pathological root resorptions.

Regardless of the affected tooth or teeth, dental or dental-periodontal traumas can result in crown or crown-root destruction and even edentations, requiring a prosthetic treatment or an interdisciplinary approach.

3.1 PERIODONTAL DISEASE THAT LEADS TO LOSS OF PRIMARY AND PERMANENT TEETH

Early loss of primary or permanent teeth does not occur only because of dental caries, but sometimes occurs through the destruction of periodontal support in serious disorders which debut in primary or mixed dentition.

Although it is more characteristic to adulthood period, damage of the marginal periodontium was also found in

children and adolescents. Thus, Bimstein et al. (1988) showed the abnormal presence of alveolar bone resorption associated with the presence of caries, in proportion of 7.6% for children aged 4 and 5.9% for children aged 5. Delaney et al. (1995) also signals the presence of manifestations such as periodontitis, recessions, gingival erythema and edema in pre-school children with neurotrophic systemic disorders.

Clinically, there are some differences between the characteristics of the gums and the periodontal tissue of the child in comparison with the adult tissue. These physiological differences should be taken into account when conducting a clinical examination. If, in the case of adult gum, the normal gum color is pink, the color considered normal is more reddish in children. After Ralph et al. (2011) the adult gingival edge has a "knife edge" aspect, while in the case of children, the gingival edge is much more rounded, an aspect that can be considered pathological in the adult. As for the consistency of adult gingival tissue, it is firm and resilient, while in children it is much softer due to the low density of connective tissue and lack of organization of collagen fibers. In terms of texture of the gingival surface, the appearance of "orange peel" present in adult is absent in children. As regards depth of survey and attachment level, if the physiological value of the gingival sulcus of 1-2 mm is kept constant for the adult throughout life (under physiological conditions), in children, the depth of the gingival sulcus evolves from greater depths corresponding to the time of replacement of the primary teeth with the permanent ones, to the physiological value of the adult, concomitant with the increase of the attachment area, which is initially more reduced than in the adult. All these differences

are the expression of changes that take place until puberty. Periodontal tissue, as their entire body, is found in constant changes in child development. Thus, these changes make it difficult to describe the normal aspects and differentiate them from the pathological ones (Benjamin et al., 1967).

Aggressive periodontitis that debuts in childhood or adolescence can be *localized* or *generalized*. Aggressive periodontitis can affect both primary dentition (therefore, in earlier classifications, these are recorded as "localized prepubertal periodontitis") and permanent dentition (formerly classified as "localized juvenile periodontitis").

According to Merchant et al. (2014), the clinical characteristics of aggressive periodontitis located in the two dentitions are similar: there are no consistently large deposits of tartar (reduced at early ages anyway), in the clinical exam the tissues do not appear to be excessively sore and the isolated bone defects are vertical or in a characteristic shape, arched or "U" (Fig. 3.1.1-2), encompassing only one root, or more, with extension up to the apex, predominantly in the lower molars. In primary dentition, the disease is localized predominantly at the level of the molars, whereas in permanent dentition can occur only at the level of the molars, only at incisors or at the level of molars and also incisors.

According to Casamassimo et al. (2013), aggressive localized periodontitis (ALP) from primary dentition can progress into permanent dentition. It is assumed that ALP in primary dentition is due to an association of bacterial infection with specific, but minor immunological deficiencies. Tetracyclines, commonly used for ALP therapy in permanent

dentition, are contraindicated in primary dentition due to the risk of developing dental discoloration. Metronidazole is the drug of choice in ALP in primary dentition.

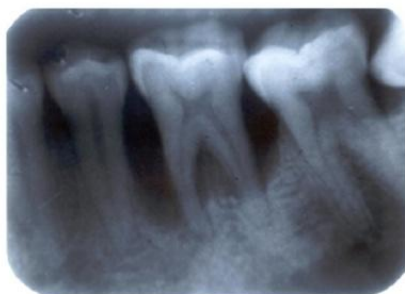

Fig. 3.1.1. The specific arcuate shape or "U-shape" of isolated bone defect in tooth 3.6. in aggressive periodontitis, here affecting both roots in different proportions (after Roshna & Nandakumar, 2012)

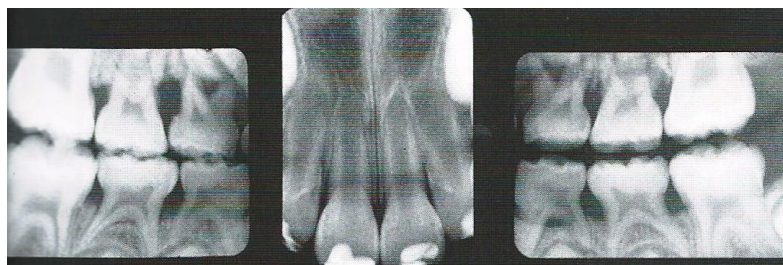

Fig. 3.1.2. Radiological aspect of localized aggressive periodontitis in primary dentition with alveolar bone damage around primary molars (after Casamassimo et al., 2013).

According to the same author, aggressive localized periodontitis in permanent dentition is characterized by loss of alveolar bone predominantly around first permanent molars and permanent incisors. The loss of attachment is quick - at a rate of about 3 times higher than for a chronic condition.

Localized aggressive periodontitis may evolve to a generalized aggressive periodontitis or may remain localized. There is an accumulation of bacterial plaque and slight signs of inflammation, but more pronounced than generally in adolescents (Fig. 3.1.3-5). Treatment is achieved by associating local therapeutic measures with systemic antibiotic therapy and microbiological monitoring.

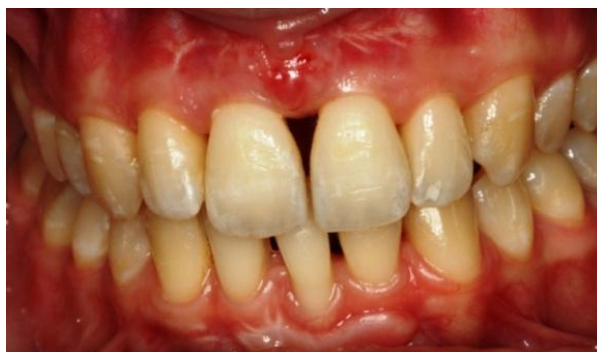

Fig. 3.1.3. Clinical aspect of a 17-year-old patient with localized aggressive periodontitis, with the loss of the papilla in the incisor region and the appearance of "black triangles" (case of Prof.Dr.Dr. Ștefan-Ioan Stratul)

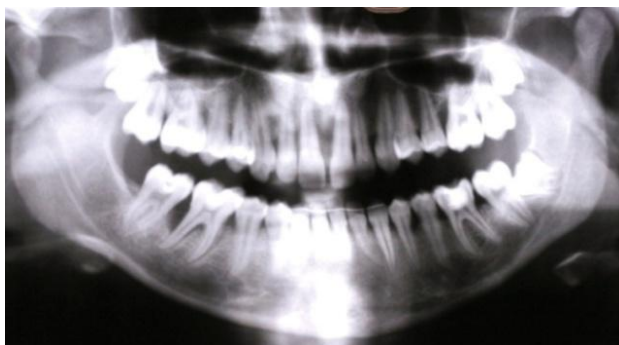

Fig. 3.1.4. The Orthopantomography of the patient from the previous figure, with evidence of bone defects in the first mandibular molars and permanent central incisors (case of Prof. Dr.Dr. Ștefan Ștefan-Ioan Stratul)

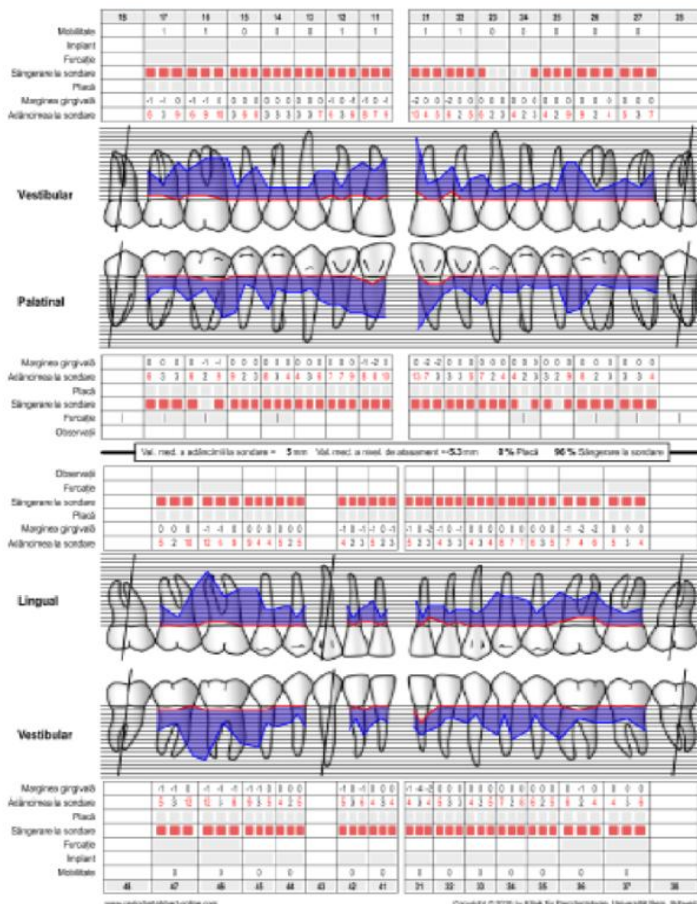


Fig. 3.1.5 Periodontal chart of the patient with localized aggressive periodontitis - from the periodontal chart the characteristic affecting of the area of the permanent molars and incisors is revealed (case of Prof.Dr.Dr. Ștefan-Ioan Stratul)

Generalized aggressive periodontitis (formerly known as the "rapid progressive periodontitis") can affect the whole dentition and does not self-diminish. There is an important accumulation of bacterial plaque and tartar, and the inflammation is severe. An aggressive therapeutic attitude is required with the association of local therapy with systemic antibiotic therapy. Generalized form affects all types of dentition, primary or permanent, being frequently associated with systemic diseases (Down's Syndrome, Papillon-Lefevre Syndrome), sometimes appearing as a buccal manifestation of serious general conditions such as neutropenia. (Fig. 3.1.6).

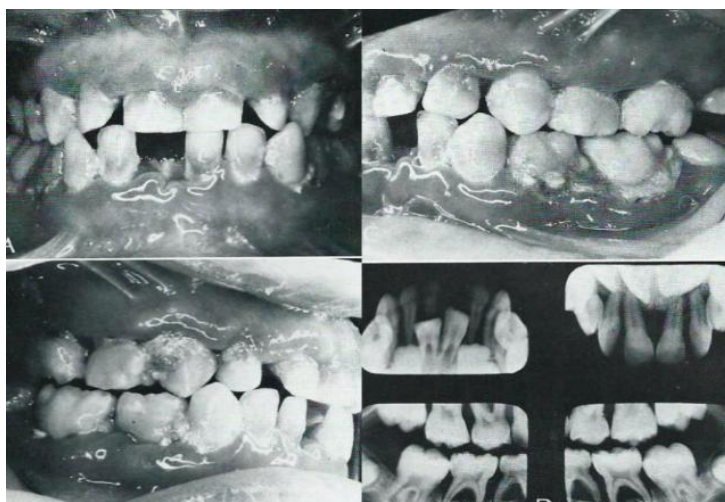


Fig. 3.1.6. Clinical and radiological aspect of a 7-year-old patient with congenital agranulocytosis, with massive tartar deposits, gingival ulceration areas and necrosis. Radiography of the patient reveals alveolar bone loss around primary teeth that are clinically extremely mobile (after Baer & Benjamin, 1974).

Chronic periodontitis, although known to be adult-specific, may also occur in children and adolescents. Specialty literature is rather poor on this clinical entity, especially

because the chronic periodontitis of children and adolescents has long been studied along with the aggressive form of periodontitis encountered in these age groups.

The Research, Science and Therapy Committee of the American Academy of Periodontology AAP emphasizes in a 2003 position paper that, as in the case of adults, also in pediatric patients chronic periodontitis can be localized or generalized, subdivision into the two forms respecting the same principles as for adults: *localized form* when less than 30% of the dento-periodontal units are affected by loss of attachment, or *generalized* when the damage is more than 30% of the teeth (Califano JV 2003). In both situations, the disease is characterized by a low rate of progression, but alternation with rapid destruction periods is not excluded. From the point of view of the extent of severity of the disease, there are three distinct forms: *incipient* (when attachment loss is up to 2 mm), *medium* (with attachment loss of 3-4 mm) and *severe* (when attachment loss is higher than 5 mm).

Although the prevalence of destructive periodontal disease is much lower in children and adolescents than in adults, however, children may develop various forms of periodontitis (Løe et al., 1991). Particularly, certain forms of periodontal disease encountered in young subjects are the expression of a known systemic disorder; in other situations, this systemic condition remains unknown. When the basic affection is family linked, it suggests a genetic predisposition for an aggressive form. Disease management is based on an anti-infectious therapy (non-surgical therapy), which may be accompanied by systemic antibiotherapy. Neither surgical therapy is excluded from the general therapeutic protocol.

Independent of the periodontal disease form, the successful therapeutic principle based on early diagnosis of the disease remains valid, so it is recommended that the complete periodontal examination should be an integral part of pediatric routine pediatric visits (Novak et al., 1992).

Gingival manifestations of systemic diseases in children are also described, which can lead to the loss of primary and permanent teeth (Law, Silva, Duperon, Carranza 2015). Many of these diseases manifest themselves differently in children than adults (Albandar & Rams 2002). These include: ANUG (deeply underfed children under marked stress, under immunosuppressive treatment), endocrine disorders such as diabetes (both insulin-dependent, more commonly in children and also type 2), hormonal changes, haematological disorders such as leukemia (acute lymphocytic leukemia is today the major form of cancer in children aged under 7), leukocytosis (genetic - neutropenia, Chediak-Higashi and Papillon-Lefevre Syndrome, leukocyte adhesion deficiency syndrome, etc.).

As noted above, congenital diseases such as the Down's Syndrome are associated with a high prevalence of severe aggressive periodontitis in early adulthood. According to Cichon et al. (1998) and Amano et al. (2000, 2001), the aggressive form of periodontal disease in young individuals with Down's Syndrome would be caused not by the reaction to a particular periopathogen but rather by a higher individual susceptibility leading to an immune inflammatory response.

4. THE CONSEQUENCES OF EARLY LOSS OF PRIMARY TEETH

Early loss of primary teeth may be the cause of a pattern of dento-maxillary abnormalities that equally concern primary, mixed and permanent occlusion.

The loss of frontal teeth is relatively without consequences, while changes in the lateral area are significant, but also differentiated in relation to the tooth involved, namely the loss of the canine and the second primary molar is more severe than that of the first primary molar.

The main consequences of early tooth loss are: modifying the eruption of permanent teeth (accelerating or delaying the eruption), changing the space for the permanent teeth eruption, and occlusal imbalance.

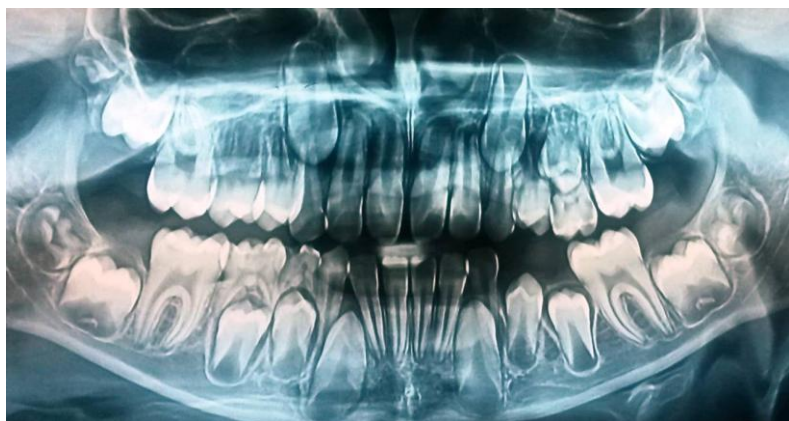The eruption of permanent teeth that replace the early lost primary teeth can take two different ways:

a) Eruption can be **accelerated**, and the modification concerns mainly the premolars and almost never the canines. The factor that causes the acceleration of eruption is the periapical osteitis process that simultaneously causes early loss of the primary predecessor. Thus, the eruption of the permanent tooth on the dental arch can also occur 4 years ahead of term and therefore with a high degree of root immaturity, with the following consequences: the post-eruptive development of such roots takes place very slowly, accompanied by limited apposition of alveolar bone and often complicated with occupying abnormal arch positions; the eruption sequence may deviate from the normal formula,

and the most disadvantageous alternative is the early eruption of the second premolars, which most frequently causes the loss of available space for teeth alignment.

b) Eruption may be more rarely **delayed** by the formation of a fibrous cap that blocks the vertical migration of the permanent tooth, a complication that occurs when the loss of the primary tooth appears very early.

The early loss of primary teeth is followed by the reduction of the remaining space, by sagittal movement of the adjacent teeth. (Fig. 4.1).



*Fig. 4.1 The early loss of the left mandibular primary molars resulted in 3.6 bending mesially and the reduction of the space available for the eruption of the premolars; Orthopantomography
(Collection of the Department of Pediatric Dentistry)*

Space loss, if not treated properly, may have immediate or long run consequences, preventing the eruption of the last successor teeth (superior canines or inferior second premolars).

In the maxilla, the canine does either not erupt, remaining included, or erupts to an ectopic position (Fig. 4.2).

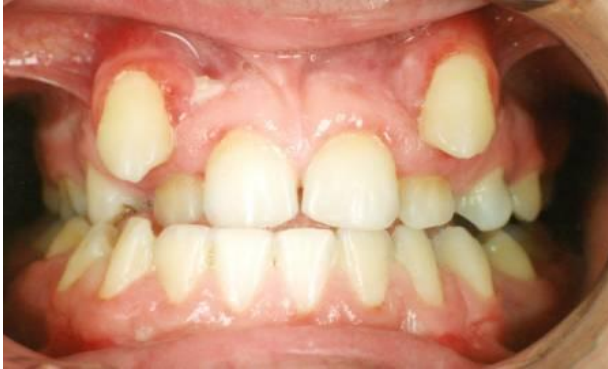
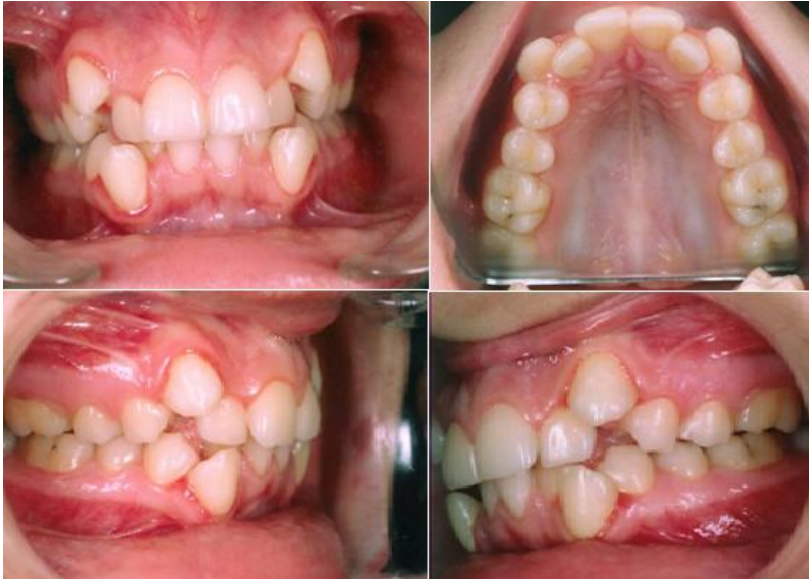
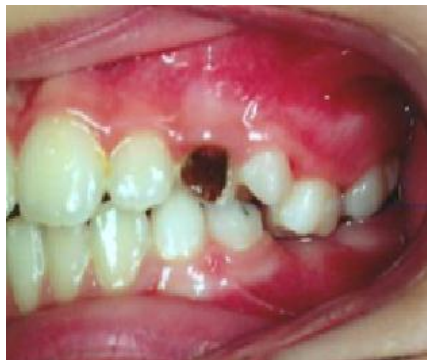Fig. 4.2 Ectopic eruption of 1.3 and 2.3 in a patient with early loss of upper primary molars and a poor sagittal development of the maxilla (Pediatric Discipline Collection)

Early loss of several primary molars in all hemi-arches leads to a complicated clinical entity called GMP = generalized mesial position (Fig. 4.3). By mesial migration of the permanent first molars, the space required for the eruption of the successors is reduced and serious dento-maxillary abnormalities with crowding and large space deficiency are installed. The orthodontic therapy in such cases involves the sacrifice of all the four premolars, which will have to be extracted in order to correct the space deficiency.

Occasionally, in parallel with the loss of space, the extrusion of the antagonists takes place, which in the primary occlusion is typically accompanied by the alveolar process. This modification may result in blocking the sagittal movement of the teeth limiting the breach created by loss of the primary tooth and may have a favorable effect, especially on the position of the 6-year molars (Fig. 4.4).



***Fig. 4.3 Generalized mesial position with ectopic canines in all four quadrants and maintenance of neutral molar reports
(Collection of the Department of Pediatric Dentistry)***



***Fig. 4.4 The vertical migration of 6.5 produced the occlusal blocking and prevented the mesial migration of 3.6
(Collection of the Department of Pediatric Dentistry)***

Occlusal imbalance is the most serious of the consequences of early tooth loss, disturbing the occlusal

relationships and producing malocclusion, as a result of early eruption and dental movements around the early tooth loss outbreaks (Fig. 4.5). Thus, the early eruption determines the installation of occlusal immaturity outbreaks in disparity with the rest of the occlusal development, and the displacement of the limiting and antagonistic teeth creates interference and changes the dynamics of the bimaxillary relationships. From this point of view, the existence of unequal situations between the two arches or between the two hemi-arches of each jaw dictates the tightness and severity of the changes.

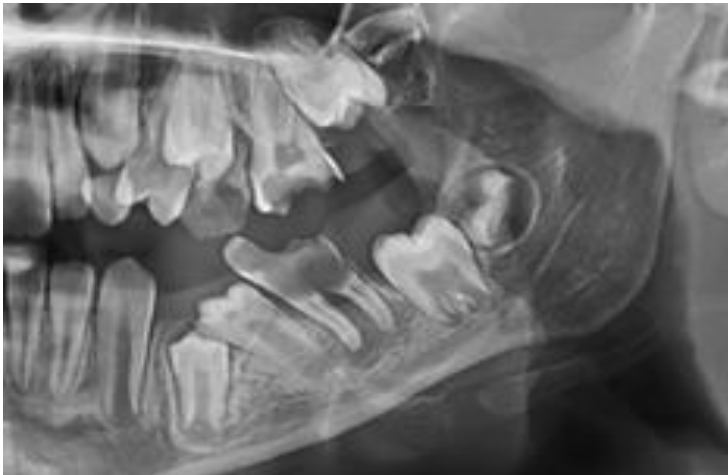

Fig. 4.5 Early loss of 7.4 and 7.5, with the mesioversion of 3.6 and 3.5 (intraosseous), preventing the eruption of 3.4 and the vertical migration of the antagonists (Collection of the Department of Pediatric Dentistry)

The effects over time are difficult to predict because the changes may be primary or can be transferred into permanent occlusion, they may be minor in the primary occlusion stage and may worsen over time or, on the contrary, some serious aspects may improve or even disappear with time.

5. SPACE MANAGEMENT IN PRIMARY DENTITION

Space management in primary dentition is extremely important because early loss of primary teeth can influence dental eruption, growth and optimal development of the stomatognathic system.

The key in controlling the space in primary dentition is to know what issues should be treated (Proffit WR et al., 2012).

Early loss of teeth at this age is approached by regions: anterior (incisors and canines) and posterior (molars). The causes and treatment of early dental loss differ between the two regions (Casamassimo S.P. et al., 2013).

In the anterior area, the premature loss of incisors and primary canines is mainly due to dental trauma and dental caries. In the lateral area, premature loss of primary molars is mainly due to carious lesions.

Although the consequences of early tooth loss are revealed late, with the eruption of permanent teeth, space maintenance should be done as soon as possible after the loss of primary teeth in order to prevent space loss.

Early lost primary incisors are usually replaced for 4 reasons: space maintenance, functionality, phonation and aesthetics (Casamassimo S.P. et al., 2013).

Tooth loss in the anterior area is usually solved by applying removable devices (functional/myofunctional) provided with teeth or fixed appliances soldered at molar level, which replace the lost teeth from the anterior area (Fig. 5.1-3).

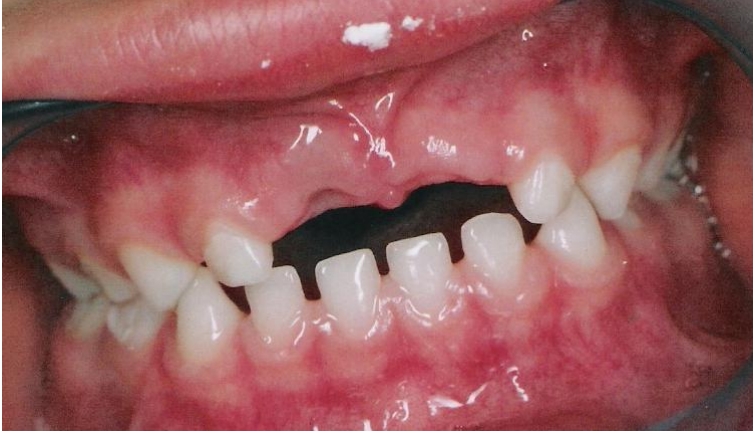

Fig. 5.1 Clinical situation of a 4 year old child with trauma loss of the two central upper primary incisors (Collection of the Department of Pediatric Dentistry)

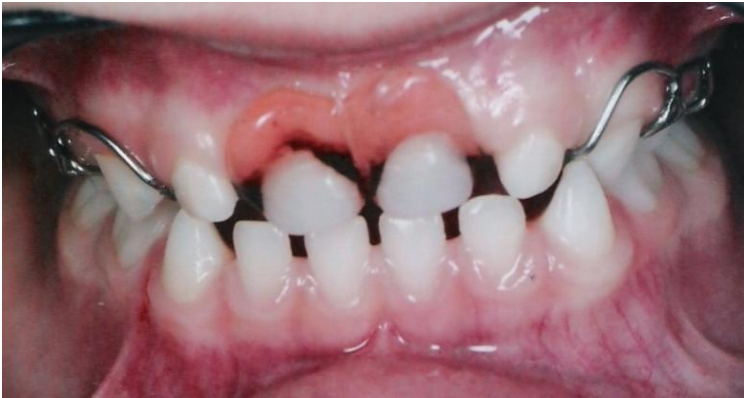

Fig. 5.2 Rehabilitation of the aesthetic function and phonation, by applying a palatal plate provided in the lateral area with anchoring elements (Collection of the Department of Pediatric Dentistry)

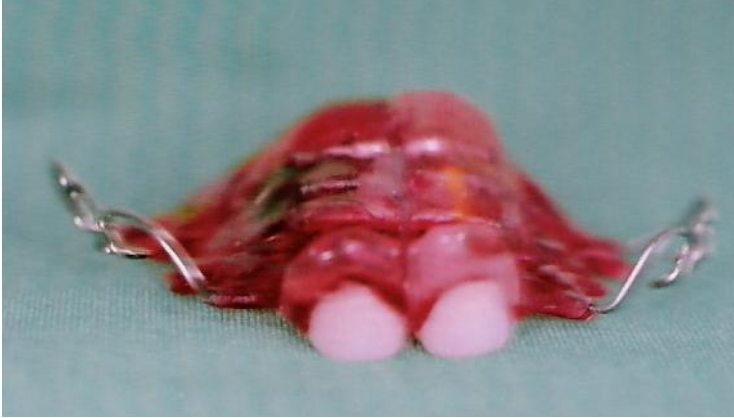

Fig. 5.3 Palatal plate provided in the anterior area with prosthetic teeth, saddle and artificial gums to restore the aesthetic function (Collection of the Department of Pediatric Dentistry)

In the lateral area, we have to ensure the space maintenance resulting from the early loss of primary molars. For this purpose, 5 space maintainers are generally used:

- the pediatric crown: maintains the mesiodistal dimension of endodontically treated primary teeth;
- band and loop space maintainer: ensures maintenance of the space resulted from the early loss of one or both primary molars (Fig. 5.4);

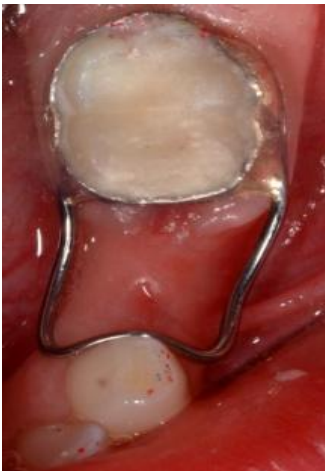

Fig. 5.4 Band and loop space maintainer fixed on a primary temporal molar (Collection of the Department of Pediatric Dentistry)

- the lingual arch: it is not recommended in the mandible due to the risk of interfering with the eruption of the permanent lower incisors. In the maxilla, in clinical situations when a unilateral loss of one primary molar occurs, a Goshgarian transpalatal arch can be applied and in situations with bilateral loss of first primary molars, a Nance device can be applied.
- the distal-shoe space maintainer: used in cases where there is an early loss of the second primary molar prior to the eruption of the first permanent molar. The device is soldered to the first primary molar and serves as a guide for the eruption of the first permanent molars in the correct position.
- removable partial dentures: useful when several primary teeth are lost and the remaining teeth cannot provide sufficient support for the application of devices (Fig. 5.5).

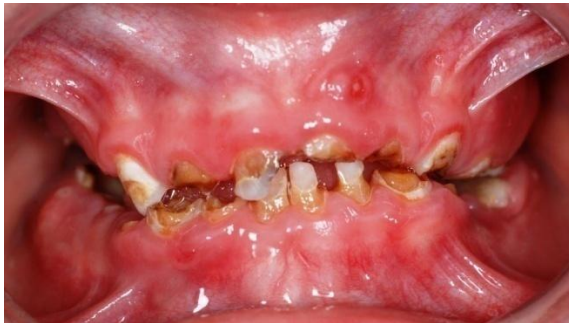

Fig. 5.5 Various degrees of coronal destruction of all primary teeth will require the application of an appliance as an activator (Collection of the Department of Pediatric Dentistry)

6. SPACE MANAGEMENT IN MIXED DENTITION

Controlling or management of space in mixed dentition is essential and can prevent unwanted loss of arch length. It is the crossroad between paedodontics and orthodontics, where every mistake made by those who treat children leads to the development of dento-maxillary abnormalities that will later require complicated, long-lasting and expensive orthodontic therapy. It is the duty and liability of each dentist to evaluate each child patient not only from a restorative point of view, but from all aspects, keeping in mind that his therapeutic conduct can significantly influence the growth and normal development of the stomatognathic system.

In order to be able to issue a correct diagnosis and to make an optimal therapeutic decision, the dentist must know the elements to be assessed in order to achieve a favorable space management in the mixed dentition. These are: dental age, eruption sequence, time elapsed from tooth loss, delayed eruption of permanent teeth, bone overlying the dental bud, and available space.

Bratu E. et al., 2005, states that the space resulting from the early loss of a primary tooth closes within six months, so the space maintainer should be placed as soon as possible after extraction.

It is important to have an understanding of the patient's eruption sequence because sometimes disturbances in the normal eruption (eruption of the second permanent molar before the second premolar) can lead to a decrease in length of the dental arch.

Primary teeth that persist on the dental arch (due to ankylosis or reinclusion) or permanent teeth in inclusion may cause delayed eruption (Fig. 6.1). Their extraction, followed by maintaining or regaining space, will ensure the eruption of the permanent teeth.

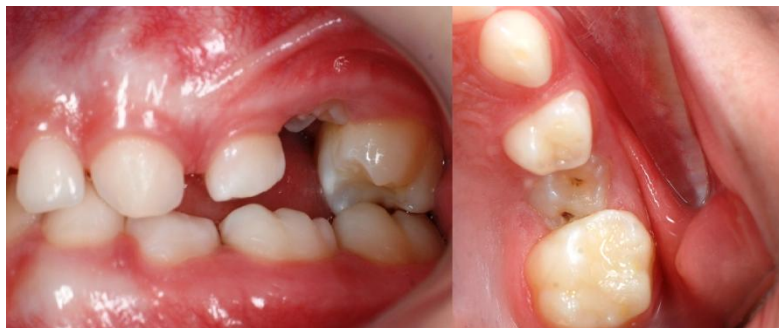

Fig. 6.1 Reinclusion of 6.5 has led to the loss of space required for the eruption of 2.5 as a consequence of the bending of adjacent teeth towards the ankylosis outbreak. The therapy of this case involves extraction of the ankylosed primary tooth, application of an active space maintainer and monitoring the eruption of 2.5 (Collection of the Department of Pediatric Dentistry)

If the permanent tooth is intraosseous, in order to assess how long it will take until it erupts, the thickness of the overlying bone can be measured, and it will be taken into account that for each millimeter of bone, approximately 6 months are expected.

To illustrate space control during mixed dentition, we present the case of a 7-year-old patient with loss of the permanent incisors by avulsion following a traumatic incident happened in school, enamel fractures of the lower permanent incisors, with aesthetic, speech, and masticatory functions affected (Fig. 6.2-3).

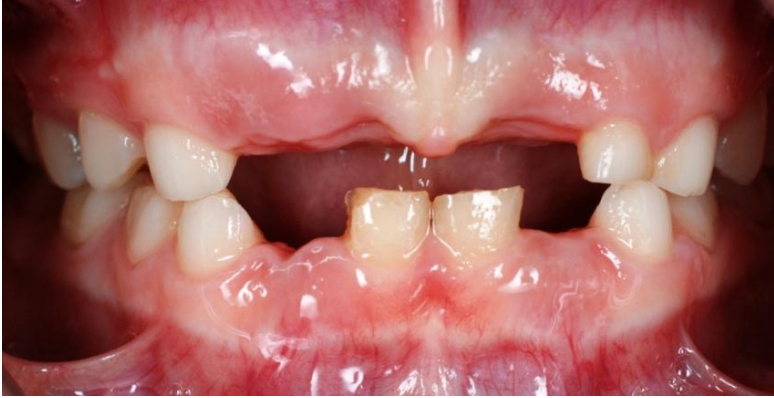

Fig. 6.2 The loss of 1.1 and 2.1 by trauma in mixed dentition in a 7-year-old patient rises the problem of space management (Collection of the Department of Pediatric Dentistry)

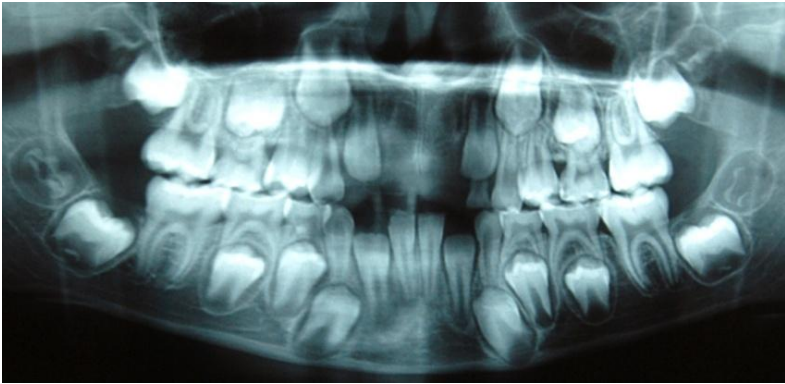


Fig. 6.3 Orthopantomography of the case in the previous figure with confirmation of diagnosis (Collection of the Department of Pediatric Dentistry)

Restoring the aesthetic function, ensuring an optimal phonation, and space maintenance were made using a removable space maintainer such as a palatal plate with partial denture in the anterior area and Stahl clasps in the lateral area (Fig. 6.4-5).

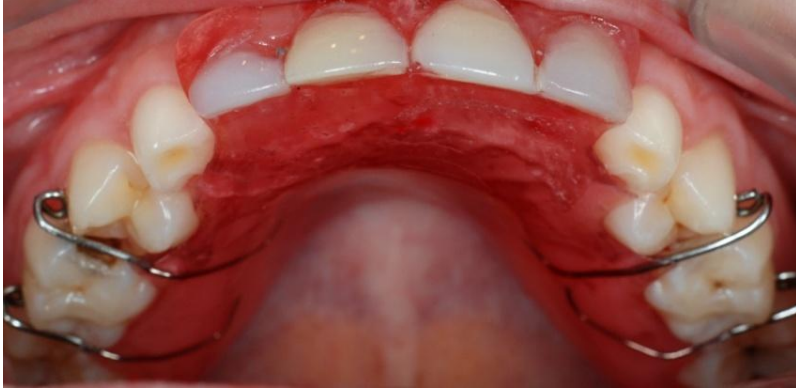

Fig. 6.4 Removable palatal plate space maintainer with partial denture in the anterior area (Collection of the Department of Pediatric Dentistry)

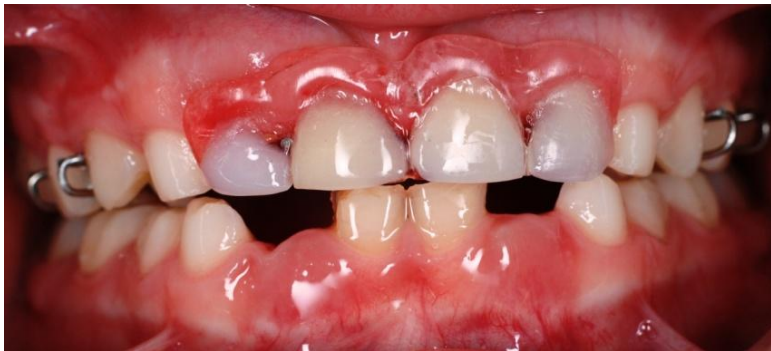

Fig. 6.5 Spacer maintainer applied in the maxillary arch, clinical aspect (Collection of the Department of Pediatric Dentistry)

To ensure optimum space management, the patient was kept under clinical observation. The prosthetic lateral incisors were progressively reduced to form a guiding plan, with the aid of which the permanent lateral incisors erupted to the correct positions (Fig. 6.6).

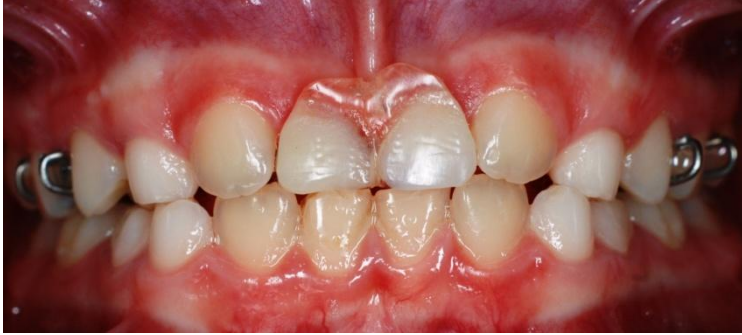

Fig. 6.6 The correct eruption of 1.2 and 2.2 with the help of the space maintainer and the concomitant eruption of the entire lower front group (Collection of the Department of Pediatric Dentistry)

After the "assisted" eruption of the upper lateral incisors, the aesthetic function can be assured either by means of a removable space maintainer, or by a fixed device applied on the molars, or by other modern prosthetic methods (Fig. 6.7).

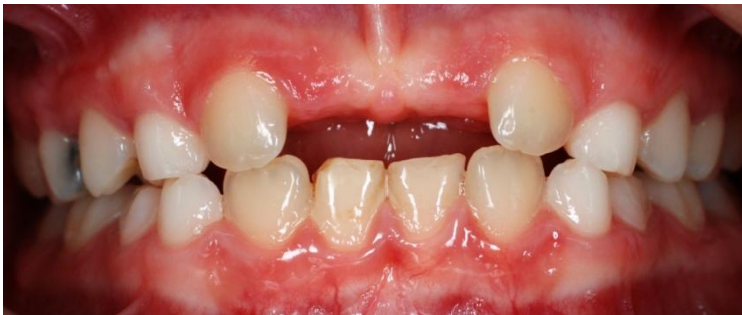

Fig. 6.7 The final aspect, after the treatment with the removable space maintainer (Collection of the Department of Pediatric Dentistry)

7. CLASSIFICATION OF SPACE MAINTAINERS

In the literature, there are a series of criteria for classifying space maintainers:

- aggregation mode (fixed, semi-fixed or removable);
- their function (active/passive, functional/non-functional);
- application area (monomaxillary or bimaxillary, unilateral or bilateral).

Recent developments in the field of dental materials and technologies have led to the emergence of alternative types of space maintainers, prefabricated, versatile, that can be applied in a large variety of clinical situations, being either passive or active.

R.J.Andlaw and W.P.Rock (1987) quoted by Bratu E et al. (2005), classifies them in the following way:

1. Band / crown and loop
2. Palatal arch
3. Lingual arch
4. Stainless steel wire and composite
5. Removable space maintainers

Graber (1994) quoted by Bratu E et al. (2005) divides them into two major classes, with several subclasses:

1. Fixed space maintainers:
 - a. Functional
 - b. Non-functional

- c. Space maintainer with extension
 - d. Fixed lingual arch
 - e. Semi-fixed lingual arch
2. Removable space maintainers

After *Primosch* (1995) quoted by Bratu E et al. (2005), space maintainers are of five types:

- 1. Band and loop
- 2. Nance palatal arch
- 3. Fixed lingual arch
- 4. Distal shoe
- 5. Removable space maintainers

The classification proposed by the team of Pediatric-Orthodontics Clinic in Timișoara in 1998 (Bratu E et al., 2008) is:

- 1. Fixed space maintainers
 - a. Unilateral:
 - two steel bands reinforced with wire
 - two pediatric crowns with a polymeric intermediate
 - a band and pediatric crown soldered with wire
 - distal shoe
 - band and loop
 - active space maintainer
 - b. Bilateral
 - two pediatric bands/crowns combined with a lingual thread and provided with distal extension bars.
 - adhesive bridges of Ist and IInd generations

2. Removable Space Maintainers

The classification given by *J.R.Christensen and H.W.Fields, jr* (1999) quoted by Bratu E et al. (2005) is as follows:

6. Band/crown and loop
7. The distal shoe space maintainer
8. The lingual arch
9. The Nance palatal arch
10. The transpalatal bar
11. Removable space maintainers

After *R.D.Terlaje and K.J.Donly* (2001) quoted by Bratu E et al. (2005) space maintainers can be:

12. Band/crown and loop.
13. Distal shoe space maintainer
14. Lower lingual holding arch (LLHA)
15. The transpalatal bar
16. The Nance palatal holding arch
17. Removable acrylic saddle appliance

We consider useful and practical the classification of space maintainers *according to how they are manufactured*. Thus, the space maintainers (SM) can be:

18. made in the dental laboratory
19. made in the dental office
20. prefabricated

The space maintainers (SM) made in the dental laboratory can be: **fixed** (band and loop, crown and loop - a

clinical phase is needed in the dental office, for adjustment of the pediatric crown, Goshgarian transpalatal bar, Nance device, lingual arch, lip-bumper, adhesive bridges), **removable** (palatal plate, lingual plate) or **mobile** (activator).

SM made in the dental office are various orthodontic wires, shaped according to the clinical situation, attached to the teeth using current adhesive systems. In 2002 *A.I.Karaman and S.Belli* quoted by Bratu E et al. (2005) propose an alternative solution for fixed space maintainers. They use *polyethylene fibers* that are attached to the teeth adjacent to the breach with a high consistency composite. Although easily adaptable and applied, polyethylene fibers have not proven adequate mechanical strength over time, so we recommend the use of metallic devices.

Prefabricated SM can be, for example: Kinderdent's DENOVO system, EZ SPACE MAINTAINER of Ortho Technology or pediatric crowns.

At present, SM can be made using digital technology in association with CAD/CAM systems. This involves taking an optical impression, resulting in a digital model, on which, the sketch of the future SM is modeled, using a dedicated software. A 3D mock-up is then printed, tested intraorally and then the final sketch is made (see chapter 10).

In the orthodontic therapy performed by specialists in orthodontics and dento-facial orthopedics, appliances can be provided with different elements which have the role of passive or active space maintainers. Thus, removable or mobile orthodontic appliances may contain a series of passive or active space maintaining elements such as: an acrylic extension of the plate resting on the proximal edges of the teeth that delimitate

the edentulous space (passive SM), 2 arches in "C" or a "bow/club" arch (passive or active SM). Fixed orthodontic appliances can work as space maintainers if they include in their construction either a utility arch in "two by four" type therapy, a closed coil spring, (passive) or an open coil spring, which has an active role in regaining the lost space.

Adhesive bridges, used as primary long-term prosthetic treatment in infants and youngsters both in the anterior and posterior areas, also perform a function of maintaining the space required for permanent tooth eruption or preservation of space until alveolar bone maturation allows the insertion of a dental implant.

In the past two years, with the development and diversification of pediatric dentistry materials, *prefabricated space maintainers* have emerged. Kinderdent sells prefabricated space-maintaining elements (*Denovo System*, 2002), which are presented in kits in various shapes and sizes, together with the tools needed to adapt them to different clinical situations. The major benefit of these systems is to reduce the time required to achieve and implement them, which sometimes included laboratory phases in classical techniques.

Of course, within this classification of space control means, we must also mention the method of choice for the prevention of space loss, which is represented by **the natural space maintainer: the primary tooth**. We emphasize on this occasion the essential importance of **complete maintenance** of the coronal integrity of the of the primary tooth, sometimes with the aid of pediatric crowns, in order to preserve every millimeter to achieve optimal space management in primary or mixed dentition.

8. THE ROLE AND CONDITIONS WHICH THE SPACE MAINTAINERS HAVE TO FULFILL

In order to be able to perform its functions, without destroying the structures on which it relies or disturbing the normal growth and development of the stomatognathic system, a space maintainer of any kind must fulfill a number of conditions. These were synthesized by *Graber* quoted by Bratu E et al. (2005) as follows:

- a) to maintain the mesiodistal dimension of the lost teeth;
- b) as far as possible, to be functional and to prevent overeruption (vertical migration) of the antagonist tooth/teeth;
- c) be as simple and as resistant as possible;
- d) not to exert excessive or pathological forces on the present teeth, endangering their health;
- e) to be easily sanitized and not retentive for the bacterial plaque;
- f) not to limit, by their design, the normal growth and development processes or to interfere with masticatory, deglutition or speech functions.

Besides these essential conditions, we consider it useful for dentists to take into account, while designing and applying a space maintainer (SM), the following aspects:

- The SM should be easily applied and removed to allow periodic evaluation (6 months) of the support structures;
- SM to improve aesthetics;
- SM to contribute to phonation (in the anterior area);
- SM to prevent the setting of oral habits;
- SM can help to regain lost space by moving the adjacent teeth (active space maintainers);
- SM can be easily repaired if damaged;
- SM should have a moderate production cost in order not to unnecessarily increase the costs of space maintaining therapy;
- SM not to detach during the normal functioning of the stomatognathic system, to avoid the risk of swallowing;
- SM should not be applied to patients who do not understand the importance of dispensarization and periodic checks; if the patient does not show up for appointments, the dentist is absolved from the responsibility of completing the treatment;
- SM should not be applied to patients who do not know or understand to follow the guidelines for maintaining an impeccable oral hygiene during space maintaining therapy.

9. THE MAIN TYPES OF SPACE MAINTAINERS

Space maintainers are medical devices that have the main role of preventing loss of the space required for the eruption of permanent teeth, by preventing the mesial migration of the first permanent molars.

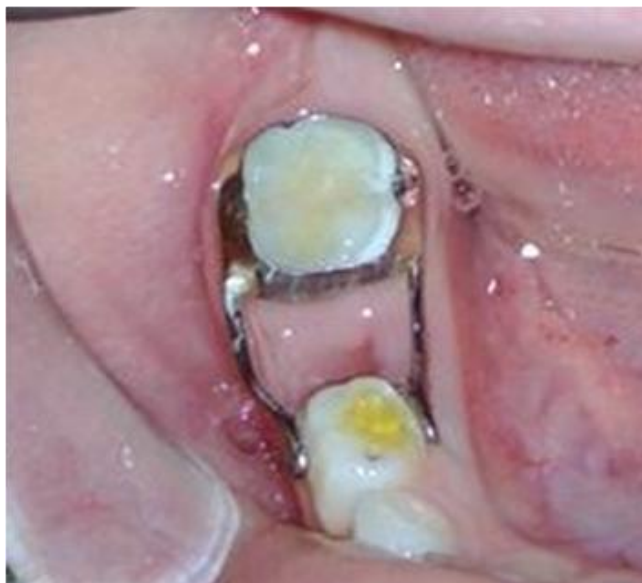Depending on the patient's biological age, on his dental age, on the present teeth or teeth requiring pedodontic therapy, on the technological possibilities and clinical situation, there are a large variety of therapeutic options: Orthodontic band/pediatric crown and loop, Goshgarian transpalatal bar, Nance palatal arch, lingual arch, lip-bumper, distal-shoe intra alveolar space maintainer device, pre-fabricated space maintainers, space maintainers made in the dental office, pediatric crowns or removable space maintainers.

9.1. BAND AND LOOP

It consists of an orthodontic band and a wire extension that is soldered to the band with both ends and extends to the adjacent tooth of the missing one; it has the role to maintain the space resulted from the early loss of a primary tooth (Fig. 9.1).

Generally, the orthodontic band version is used in cases where the abutment tooth is a permanent tooth (usually the first permanent molar), or a primary tooth with a complete crown or covered by a pediatric crown. In the case of a pediatric crown, the clinical situation should be analyzed: if the space is

maintained by a pediatric crown and loop, or if on top of the pediatric crown an orthodontic band with loop should be applied. The inclusion of a pediatric crown in the construction of the device is sometimes justified by a non-retentive morphology of the primary abutment tooth, in which case setting the band is difficult and with poor retention.



*Fig. 9.1. Orthodontic band with loop applied on the primary second molar
(Collection of the Department of Pediatric Dentistry)*

Indications:

- premature loss of the first primary molar in primary dentition both in the upper and lower jaw;
- premature loss of the first primary molar in maxillary mixed dentition (not in the mandible, where the exfoliation of the primary canine leads to the loss of mesial support);

- premature loss of the primary second molar in mixed dentition during the clinical eruption of the permanent first molar. In this situation, after the complete eruption of the first permanent molar, the space maintainer should be replaced with a new space maintainer adapted to the clinical situation;
- premature loss of the second primary molar after the complete eruption of the first permanent molar, the band being applied on the permanent molar;
- bilateral loss of the primary second mandibular molars before incisors' eruption.

Contraindications:

- increased carious activity in a patient with poor oral hygiene;
- in the clinical situation where there is significant space deficiency;
- in patients who do not follow the guidelines for periodic appointments to monitor progress.

Technological aspects:

The device is easy to make and inexpensive.

1. The dentist will send the impression of the dental arch to the dental laboratory, with the selected band in the impression.
2. The dental technician will make the study cast and the working cast.
3. On the working cast, the dentist will mark for the dental technician the contour of the space maintainer (Fig. 9.2).

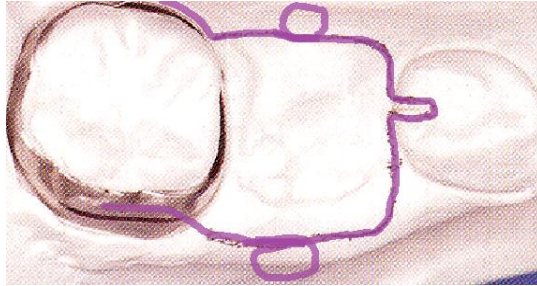


Fig. 9.2 Marking the contour of the loop on the working cast by the dentist

4. If the compromised tooth has not yet been extracted, it would be cut from the cast.
5. The dental technician will shape the wire loop. Stainless steel wire of 0.9 or 1 mm diameter is used. This should be shaped so that it is in contact with the band in its middle third area and parallel to the edentulous ridge without being in contact with it (Fig. 9.3).

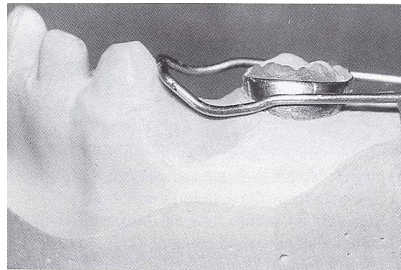


Fig. 9.3 Wire loop modeling on the cast by the dental technician (Varga, 2003)

The wire must lean on the tooth adjacent to the edentulous ridge, at its contact point (Fig. 9.4).

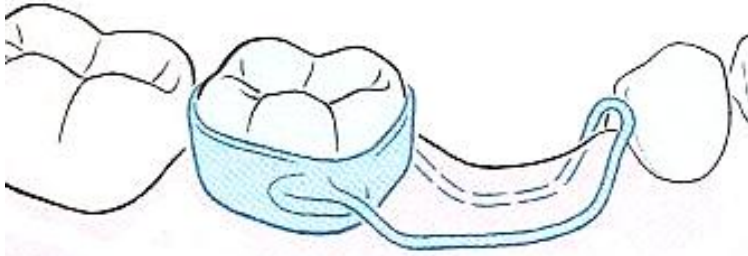

Fig. 9.4 Band and loop space maintainer scheme, that rests on the contact point of the adjacent tooth (van Waes and Stöckli, 2001)

There are many patterns of wire loop modeling depending on the clinical situation, the technological possibilities of the dental technician, or therapeutic objectives. Thus, some authors recommend bending the loop end so that it rests on the occlusal surface of the adjacent tooth without disturbing occlusal relationships (Fig. 9.5).



Fig. 9.5 The scheme of the band and loop space maintainer with occlusal step (van Waes H, Stöckli P, 2001)

Usually, this alternative further stabilizes the space maintainer and prevents the mesial migration of the first permanent molar. It may be indicated in the case where the distal crest of the adjacent tooth has a carious lesion or filling, which allows minimal preparation of an orifice for the occlusal step.

The buccal-lingual dimension of the loop should be about 8 mm, so that it allows the permanent tooth to erupt on the dental arch, without being deviated to buccal or lingual/palatal. Repeated bending of the wire should be avoided.

Mainly, the classic modeling of the band and loop makes this space maintainer a passive one, with the single role of maintaining the space resulted from the extraction of the primary compromised molar.

However, patients often decide to see the dentist long after the primary tooth has been extracted, when the consequences of early tooth loss are already present. In this clinical situation, a passive space maintainer is no longer sufficient, so that an active space maintainer is needed.

For clinical situations that require regaining of the space lost by migration of the adjacent teeth, we introduced in the wire model two helical loops (buccal and oral) that can be activated, transforming this space-maintainer from passive into active (Fig. 9.6).



Fig. 9.6 Band and loop maintainers for which we have provided two additional helical loops to enable the activation and regaining of the lost space (Collection of the Department of Pediatric Dentistry)

Thus, by compressing the loops, orthodontic forces develop, that will lead to the displacement of the adjacent teeth to their initial position and regaining the space required for the premolar eruption. Activation of these loops can also be done intraorally, with care not to detach the space maintainer and also to avoid generating too much traumatic forces.

In situations where there is anodontia with loss of the primary tooth before the optimal age for applying a prosthesis, or if a six year molar is prematurely lost, in order to avoid the “six year molar syndrome”, a space maintainer other than those described above is required. Space maintenance in this situation is not necessary to facilitate the eruption of a permanent tooth, but only to delay prosthetic application in situations where there is an anodontia, or an early loss of the permanent molar. (Fig. 9.7).

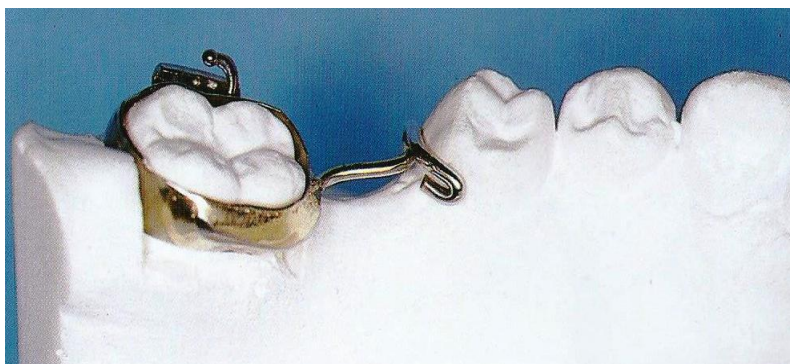
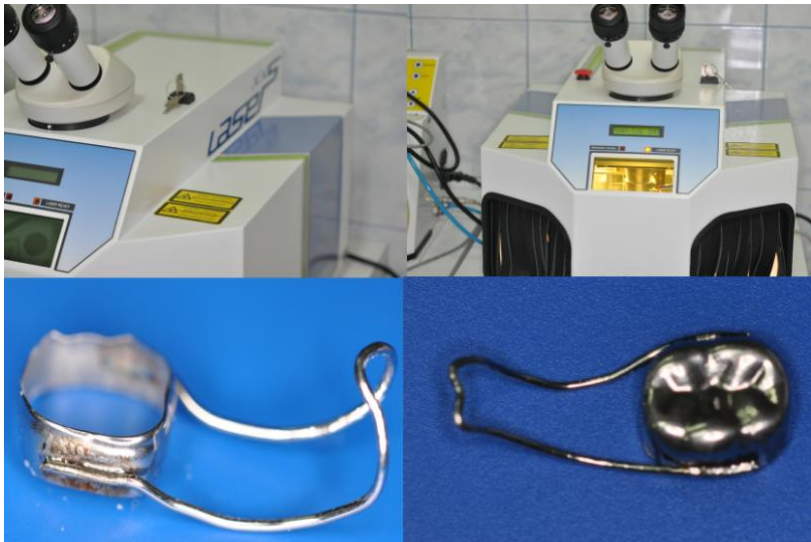

Fig. 9.7 Space maintainer applied to temporize prosthetic therapy and not to facilitate the eruption of a permanent tooth (Comparelli U, 1999)

6. The wire is soldered to the orthodontic band by means of a welding machine. Welding can be done either with a batch or in an electric arch, or, more recently, with a laser (Fig. 9.8).

7. Processing the space maintainer: the excess wire sections are cut out, the inside of the band is sandblasted to increase adhesion, then finishing and polishing are carried out. The device is then sent to the dental office on cast, taking care that no deformation occurs during transport.



*Fig. 9.8 Laser welding of the space maintainer
(Collection of the Department of Pediatric Dentistry)*

Clinical aspects:

This space maintainer is effective in preventing the mesial migration of the first permanent molar, is easily tolerated, does not restore the occlusal function of the lost tooth, but it prevents the vertical migration of the antagonists and its effectiveness is not conditioned by the child's acceptance, being a fixed device.

1. A suitable band size is chosen and placed on the abutment tooth using a pusher tool. The correct position is at 1 mm from the mesial and distal marginal ridges. Adaptation and correct placement is essential to prevent detachment or secondary caries.
2. The impression of the orthodontic band - will be done with alginate or elastomers, taking care that the impression extends 5-6 mm distally from the abutment tooth. The band is then removed from the mouth and repositioned in the impression, which is disinfected and sent to the dental technician.
3. On the working cast received from the technician the morphology of the space maintainer will be drawn.
4. After receiving the device from the technician, it is verified in the oral cavity, the occlusal relationships and the relationship of the wire loop with the soft tissues are checked.
5. Prior to cementing, the appliance is washed and dried. The oral cavity is isolated. The cement is being prepared. It is possible to use glass ionomer cement or zinc phosphate cement. The maintainer is applied by digital pressure on the abutment tooth, then a band positioning tool removes excess cement.
6. Continuous monitoring is required. The patient should be recalled every 6 months to check the correct adaptation of the device, if the abutment teeth are firm, if the cement has washed out or not. The loop's relationship to soft

tissues will be also checked, so that it does not pressurize or sink into the oral mucosa.

It is recommended that any device of this type should be removed once a year to be checked, cleaned, and to fluoridate the tooth. Maintaining good oral hygiene is essential; the child is educated in this way and parents are advised over the importance of it. Topical fluoride applications are performed in each control session.

The degree of development of the successor tooth is also verified. The space maintainer can be removed when, radiographically, the root of the permanent tooth appears to be mineralized to more than $\frac{1}{2}$ of its length, and the crown is immediately under the gum, with no bone on top preventing the normal eruption. Consideration will also be given to how the homologous and antagonist teeth are evolving, as well as to the age of the child.

As any medical device, the space maintainer can cause a series of complications. Continuous monitoring is designed to prevent them from occurring. Thus:

- the space maintainer can interfere with the normal eruption of the permanent tooth. In this case, the maintainer is removed and adjusted. If the design was incorrect, the entire construction needs to be remade correctly.
- the loop may sink in the gingival mucosa, generating irritation that will sustain a chronic inflammation. Additionally, the space is modified by the mesial migration of the first permanent molar, so the space maintainer will no longer perform its function properly.

- secondary caries may affect the abutment tooth, leading to loss of coronal integrity and the possibility of device detachment;
- the device may deteriorate, causing damage to adjacent tissues. this situation represents an emergency and involves immediate removal of the entire therapeutic assembly.

9.2. CROWN AND LOOP

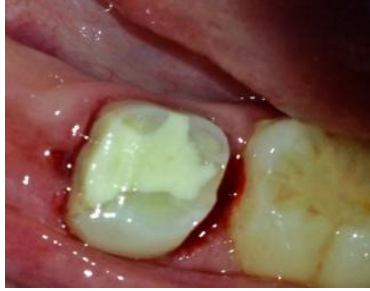Similar to the band and loop, the crown and loop space maintainer consists of a pre-fabricated pediatric crown, to which a wire loop is soldered. The wire extends to the adjacent tooth of the edentulous space resulted from the early loss of the primary tooth.

It is used when the abutment tooth of the space maintainer is a primary tooth with morphology and retention that make it difficult for an orthodontic band to be applied.

It is indicated in situations where one second primary molar is lost and the first primary molar needs to be covered with a pediatric crown, or if a first primary molar is early lost and the pediatric crown will be applied to the second primary molar.

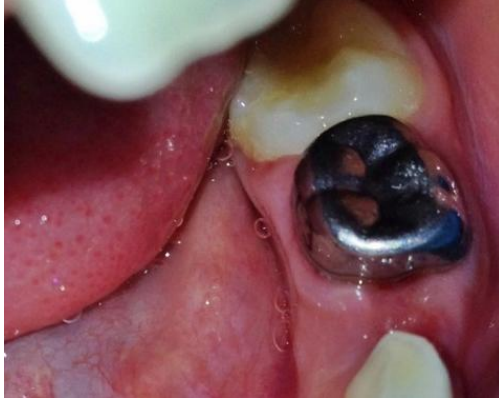The working steps are as follows:

1. Preparation of the future abutment tooth of the space maintainer for setting of the pediatric crown (Fig. 9.9).



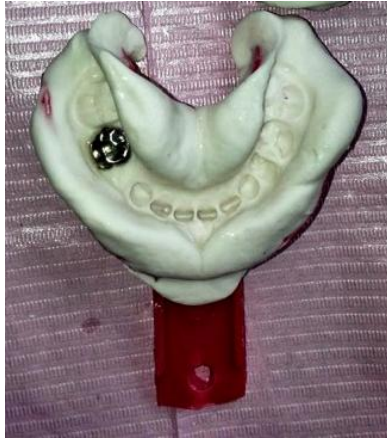*Fig. 9.9 Preparation of the primary tooth for setting of a pediatric crown
(Collection of the Department of Pediatric Dentistry)*

2. Adaptation and try-on of the pediatric crown, application of vaseline to the inside of the crown to facilitate detachment at the time of impression (Fig. 9.10).



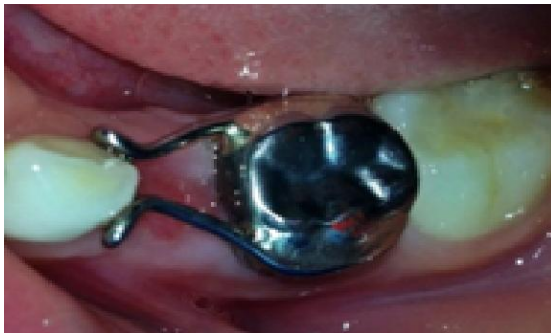*Fig. 9.10 Adaptation of the pediatric crown and setting on the abutment tooth
(Collection of the Department of Pediatric Dentistry)*

3. Impression of the dental arch with alginate or silicone; if the pediatric crown detaches itself from the impression, it will be repositioned in the impression (Fig. 9.11).



*Fig. 9.11 Pediatric crown impression prepared to be sent to the dental laboratory
(Collection of the Department of Pediatric Dentistry)*

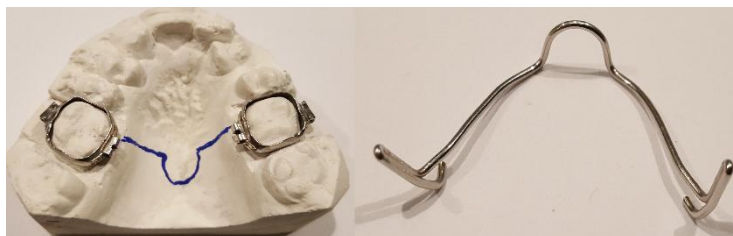4. Drawing, by the dentist, on the pediatric crown working cast, the contour of the SM's loop.
5. Manufacturing of the space maintainer by the dental technician.
6. Sending the SM to the dental office, preparing it for cementation.
7. Cementation of the pediatric crown and loop SM (Fig. 9.12).



*Fig. 9.12 Pediatric crown with loop applied on the second primary molar
(Collection of the Department of Pediatric Dentistry)*

9.3 TRANSPALATAL BAR

It is a bilateral fixed space maintainer, applied to the maxillary arch. It is made up of a bar/arch soldered to the palatal surfaces of two orthodontic bands fixed on the first permanent molars. Starting from the molar to which it is anchored, the arch, which can be either elastic or rigid, follows the path of the palatal mucosa at a distance of about 0.5-1 mm from it, up to the palatal raphe, where, in the middle of the arch, there is a U-shaped loop, then continues its route in the same manner until the anchorage on the opposite side (Fig. 9.13).



*Fig. 9.13 Goshgarian transpalatal bar: drawing on the working cast (left) which is prepared with orthodontic bands, palatal tubes, and the Goshgarian transpalatal bar (right) adapted in order to be inserted into the palatal tubes
(Collection of the Department of Pediatric Dentistry)*

Depending on the desired effect besides maintaining space (mesial or distal movement of the molar, torque movement, dental arch expansion), the loop is positioned either with the opening towards the anterior or the posterior. When the loop stays inactive, the role of the arch is to maintain the existing molar relationships and to guide the eruption of the permanent teeth when an early tooth loss occurs.

It is indicated in cases where there is a unilateral loss of a primary molar, on the condition that the opposite maxillary hemiarch has a second primary molar. It is more hygienic and easier to wear than the Nance device, but in some cases it allows mesial migration of the abutment teeth, resulting in loss of space. However, in pediatric dentistry, in some clinical cases, the Goshgarian arch may be considered as an alternative to the Nance device, due to the following advantages:

- low rate of inflammation of the palatal mucosa;
- comfortable;
- does not interfere with phonation;
- it has the role of controlling vertical migration of the molars, preventing extrusion or egression of the molars through the muscles of the tongue during its functions that involve pressure on the arch.

As a space maintainer, the transpalatal bar acts as follows: when there are one or more teeth lost, mesially from the molar dental group, the first permanent molar tends to migrate mesially and at the same time to rotate around its palatal root, tilting in distal-buccal direction. The solidarization of the two first molars from the first and second quadrants through the Goshgarian arch reduces the anterior movement of the molars and thereby prevents their rotation.

It is indicated to use the Goshgarian transpalatal arch as a unilateral space maintainer when one of the dental arches is less or not at all affected by tooth loss.

Other uses:

- Maintaining space within the dental arch;
- Derotation of unilateral or bilateral rotated molars;
- Control of upper molar eruption;
- Correction of unilateral crossbite;
- Correction of mesiodistal asymmetries;
- Used as anchorage.

Work technique:

1. Selection and adaptation of orthodontic bands;
2. Band positioning and impression;
3. Impression is being sent to the dental laboratory with the bands repositioned in the impression;
4. We set the position of the bar. Generally, the bar must be close to the hard and soft tissues, but not to exert pressure on them. It must be placed in such a way that it does not interfere with occlusion, with the tongue or with permanent teeth in eruption;
5. The bar is welded to the palatal surfaces of the bands placed at the level of the first permanent molars;
6. Processing of space maintainer;
7. Space maintainer verification;
8. Cementation.

9.4 THE NANCE DEVICE

It is a fixed space maintainer, similar to the lingual arch, but it is applied to the maxillary arch. The essential difference is that the arch does not rest on the palatal surface of the front teeth, but on the palatal mucosa at the level of palatine rugae (Fig. 9.14).

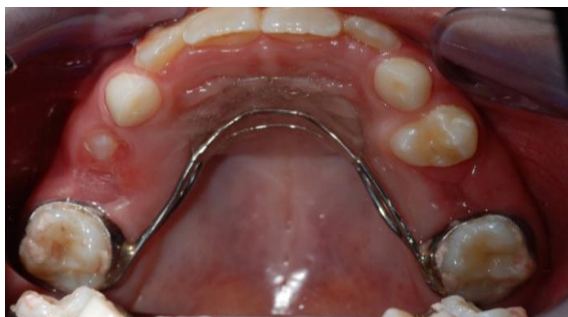

Fig. 9.14 The Nance device with the acrylic button that rests on the palatal fibromucosa (Collection of the Department of Pediatric Dentistry)

It is indicated in both primary and mixed dentition in clinical cases with unilateral or bilateral second primary molar loss. Does not interfere with occlusion. Requires frequent medical check-ups, since the acrylic button may cause irritation of the mucosa. Particular attention should be paid to the proper hygiene of the appliance as well as an eventual allergy to acrylate, as cases of chronic mucosal hyperplasia have been reported.

It is applied to cemented orthodontic bands either on primary molars, or on permanent first molars. There is an alternative of the appliance that is fixed by insertion in the Goshgarian tubes on the palatal surface of the orthodontic bands and allows easy removal for hygiene (Fig. 9.15).

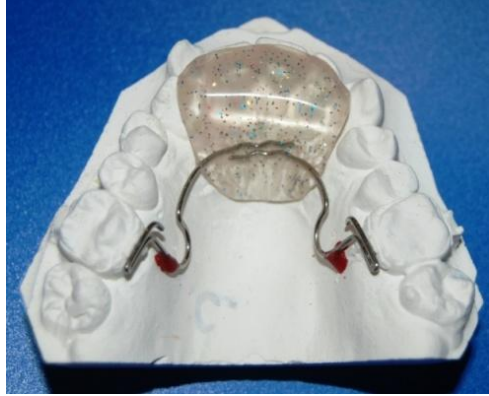

Fig. 9.15 Nance device that can be removed without the need for the orthodontic bands (Collection of the Department of Pediatric Dentistry)

The welded alternative consists of two bands cemented on primary molars, or on the permanent first molar, and an arch whose frontal part is embedded in an acrylic button and by which it rests on the palatal fibromucosa at the level of the palatal rugae (Fig. 9.16).

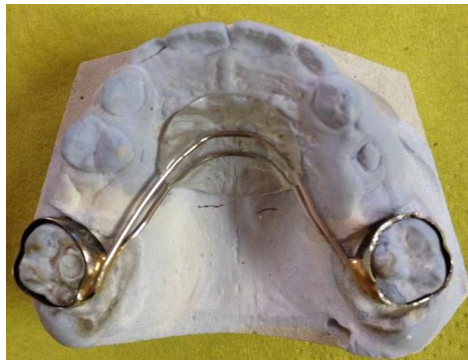

Fig. 9.16 Welded Nance device at the level of molar bands (Collection of the Department of Pediatric Dentistry)

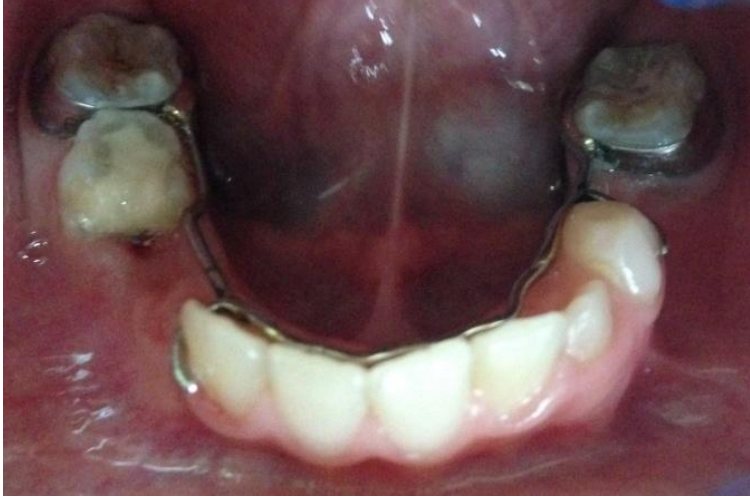9.5 THE LINGUAL ARCH

It is a fixed bilateral space maintainer, non-interfering with the occlusion, along with the Nance device and the transpalatal bar. It is used in the lower arch, preferred instead of the band and loop in all the clinical situations in which the six-year molar and permanent incisors have erupted completely.

Because permanent incisors erupt slightly lingual than primary ones, such an arch used in primary dentition interferes with the eruption of permanent incisors, so it is not recommended to be used in primary dentition, but only in the late mixed (after all lower permanent incisors have erupted).

It consists of a passive arch, soldered by two bands on the two permanent molars, being in contact with the lingual surfaces of the permanent mandibular incisors.

There are two variants of the lingual arch: one welded by the molar bands attached to the mandibular molars (Fig. 9.17-9.19) and a lingual arch in which the ends are inserted into the lingual tubes of the bands and can be removed for hygiene and adjustment (Fig. 9.20).



*Fig. 9.17 Welded lingual arch - clinical aspect
(Collection of the Department of Pediatric Dentistry)*

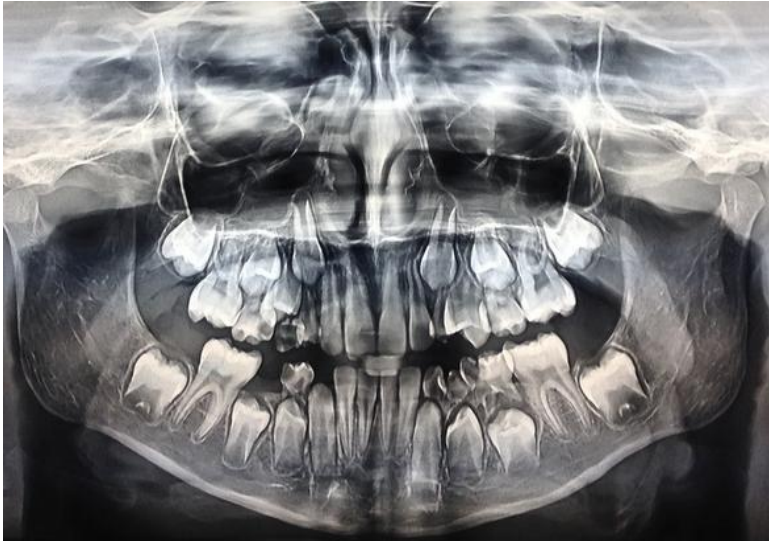

Fig. 9.18 Clinical case - Orthopantomography of Picture 9.17

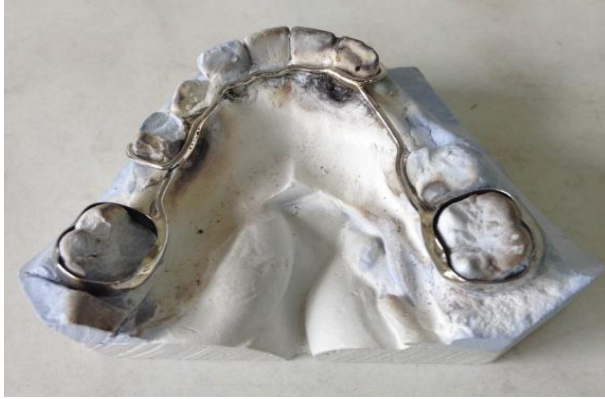

Fig. 9.19 Welded lingual arch at the level of molar bands
(Collection of the Department of Pediatric Dentistry)

The detachable lingual arches are more prone to breakage and loss in contrast to the cemented springs.

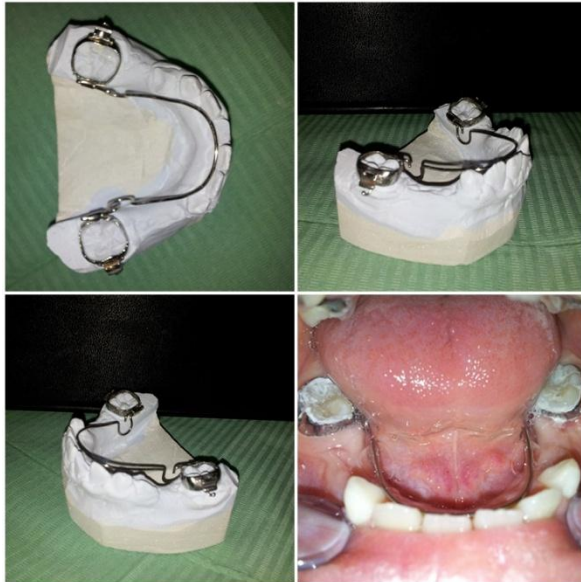

Fig. 9.20 Removable lingual arch
(Collection of the Department of Pediatric Dentistry)

If dental hygiene of the patient is poor, this type of maintainer is contraindicated.

Work technique:

1. The first step to be run is the choice and adaptation of the orthodontic bands.
2. Positioning the bands on the molars and impressing with alginate. The bands are repositioned in the impression and stabilized with a piece of wire or wax.
3. Molding of the hard gypsum working cast.
4. Determining the position of the arch; On the model we draw the sketch of the future lingual arch. Whether it is detachable or fixed, the arch starts from the middle third of the bands, passes to the cervical third of the primary molars, and rests on the permanent lower incisors at the cingulum about 1-1.5 mm slightly above the interdental papillae and creates a lingual step at the canine level to avoid coming into contact with primary molars or unerrupted premolars. Generally, the arch should be close to the hard and soft tissues, but should not exert pressures on them. It should be placed so that it does not interfere with occlusion, tongue or permanent teeth in eruption.
5. Conformation of the stainless steel wire arch with a diameter of 0.9 or 1 mm. Prior to welding, the arch should be checked whether it is active or passive, in order not to cause unwanted dental migrations.

6. Conjunction of the band arch is done by welding. Afterwards, the arch is subjected to heat treatment by means of the pointing device to reduce any stress accumulated during welding.
7. Processing and finishing the space maintainer.
8. Verification in the oral cavity.
9. Cementation.

Advantages:

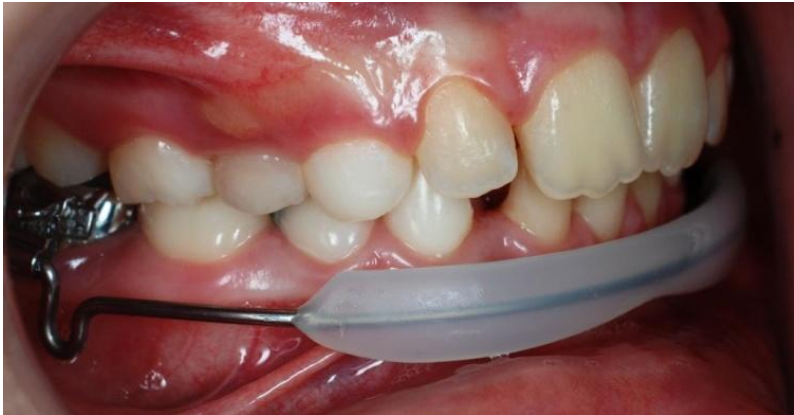- Maintains the lost space and the leeway-space;
- It does not depend on patient cooperation;
- Prevents dental arch reduction and mesial migration of the teeth on which bands are cemented.

Disadvantages:

- Cannot be used before full eruption of permanent mandibular incisors;
- Possibility of breakage, deformation of the arch due to occlusal forces;
- There is a risk of cavities and demineralizations;
- May interfere with the normal eruption of permanent teeth;
- Clogging of the loop in the gingival mucosa.

9.6. THE LIP-BUMPER

It is a fixed, bilateral space maintainer, similar to the lingual arch, but located buccally from the dental arches. It requires the application of 2 orthodontic bands on the first mandibular or maxillary molars (rare), provided with buccal tubes. It consists of a wire, which, in front of the molars, has a stop, and before the activation loops and in the anterior area that comes in contact with the lip, a plastic or acrylic element (Fig. 9.21). It is indicated in cases of bilateral loss of primary molars and can also act as an active space maintainer with the help of tonicity of the orbicular lower or upper lip.

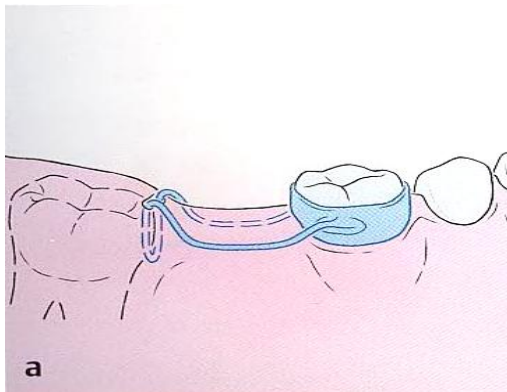


*Fig. 9.21 Lip-bumper on the mandibular arch
(Collection of the Department of Pediatric Dentistry)*

9.7 DISTAL SHOE INTRA-ALVEOLAR DEVICE

It is a fixed, unilateral space maintainer, with the main role of guiding the eruption of the first permanent molar in situations where the primary second molar is early lost, before the eruption of the first permanent molar.

The device is made up of an orthodontic band or a pediatric crown that is applied to the primary first molar and a distal extension similar to that of the band and loop type SM. The difference resides in the intraalveolar vertical extension that is soldered at the free end of the loop (Fig. 9.22).



*Fig. 9.22 Scheme of the distal shoe device
(van Waes H, Stöckli P, 2001)*

The extension can also be made from one "L"-shaped piece. It will be positioned in the post-extractional alveolus, 1 mm below the edge of the mesial septal bone, in contact with the mesial surface of the permanent molar, acting as a guide plan for its eruption (Fig. 9.23).

The impression can be taken before or after extracting the second molar. In the first case, the tooth to be extracted is cut off from the working cast, and the device will be applied with care, immediately after extraction. In the second case, an incision of the gum would be necessary in order to place the SM in the right position.

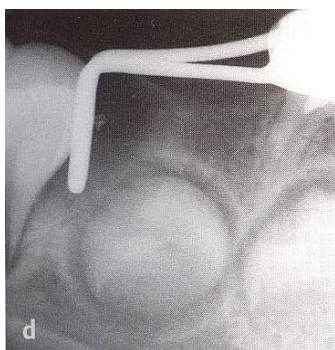


Fig. 9.23 Radiological image with the position of the free end of the vertical extension - acts as a guide plane for the permanent first molar (van Waes H, Stöckli P, 2001)

After the eruption of the first permanent molar, the vertical extension can be cut off or removed and a new crown and loop device will be built.

To verify the correct position of the vertical extension, it is recommended to perform a periapical radiograph before cementation.

There are some problems with this device. Due to the extension design and the fact that it is anchored only by the crown that covers the first primary molar, it can only replace one tooth, being fairly fragile. It does not restore occlusal function in all cases, precisely because of this lack of resistance.

It is necessary to pay special attention to the measurement and application of the space maintainer to ensure that it guides the eruption of the permanent molar correctly. The biggest problem with this maintainer is the wrong positioning.

Secondly, histological examinations have shown that complete epithelization does not occur after application of the device. For this reason, it is contraindicated in patients with weakened immune system and in those with acute bacterial endocarditis.

It is very important to have **the patient checked every 3 months** to examine the device: its position, its condition, or whether it may need to be replaced by another type of space maintainer. Used in appropriate situations in cooperative patients, potential orthodontic problems can be prevented.

Indications: Maintaining the space resulted from the early loss of the second primary molar and guiding the eruption of the first permanent molar in its correct position.

Contraindications:

1. Poor health, diabetes, fever, or acute bacterial endocarditis;
2. The absence of the first and the second primary molar, since this type of maintainer is not sufficiently resistant;
3. Congenital lack of the first permanent molars.

Work technique:

a. Direct technique

1. Preparing the first primary molar and adapting a pediatric crown.
2. A bar is cut and adapted on the distal surface of the crown, then is welded to it. Instead of a bar, a wire loop can be used. It is processed with finishing stones and gums.
3. Clinical and radiographic measurements of the distance from the distal surface of the primary molar to the distal wall of the primary molar alveolus, or to the mesial surface of the first permanent molar are performed. This value is marked on the extension bar and a bend is done at this level.
4. If it has not yet been removed, the second primary molar is extracted. Hemostasis is performed. The device is applied into the oral cavity. A periapical radiography is performed to check the position of the extension. If the bar is too short, the permanent molar will erupt next to it. If it is too long, it will interfere with the developing second premolar.
5. Fixing the device.

b. Indirect technique

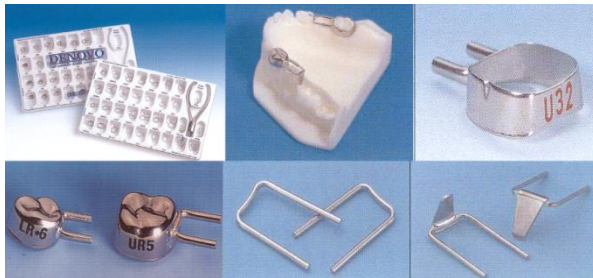
It is used when the primary second molar has been absent for a long time. The difference from direct technique consists in taking an impression of the adjusted crown and on the working cast it is adapted and the extension is welded (Bratu et al., 2005).

9.8. PREFABRICATED SPACE MAINTAINERS

The current development of technology allowed the introduction of prefabricated space maintainers, that eliminated the dental laboratory stage. They are very easy to adapt and apply and are also convenient for the patient.

There are several prefabricated space maintenance systems; we used two Denovo systems from Kinderdent and the EZ Space Maintainer system from Ortho Technology.

The Denovo system allows the clinician to apply a space maintainer in about 15 minutes without the need of an impression, laboratory or welding the components. It does not require a second session for oral cavity application since it can be inserted immediately after the primary molar extraction (Fig. 9.24).



*Fig. 9.24 Denovo Prefabricated Space Maintaining System
(Kinderdentshop, 2002)*

The EZ Space Maintainer System from Ortho Technology does not require the choice of an orthodontic band or pediatric crown according to the size of the teeth, but has a wide applicability, being fixed to the teeth similar to a bracket. It was developed by Dr. Enis Güray, and it is fully adjustable in

the dental office. It does not require an impression and can function either as a passive space maintainer or as an active one (Fig. 9.25).

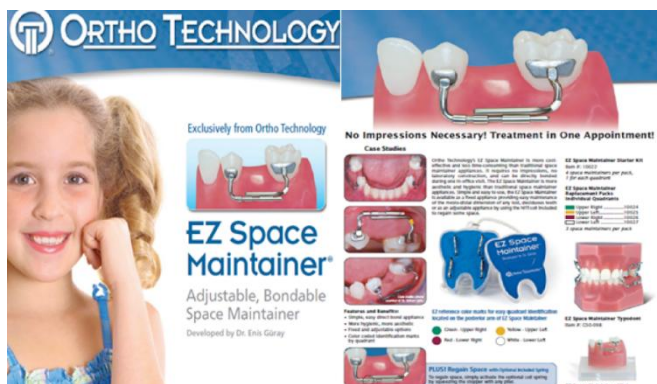

Fig. 9.25 EZ Space Maintainer System (by www.orthotechnology.com)

To demonstrate versatility, efficiency and the clinical stages of application of an EZ Space Maintainer, we will introduce you to the case of a 8-year-old girl who was referred to the Pediatric Dentistry Department in Timisoara due to the reinclusion of 6.5, with the consecutive migration of the adjacent teeth and loss of space required for the eruption of 2.5 (Fig. 9.26, 9.27).

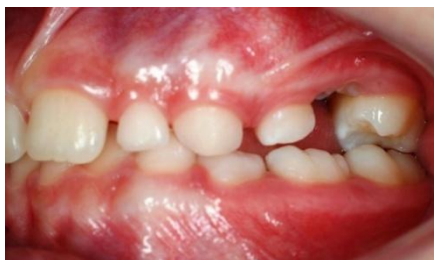
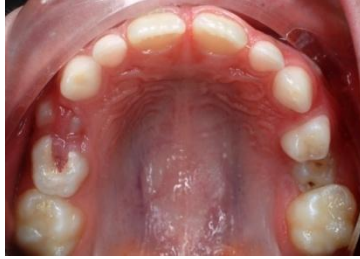
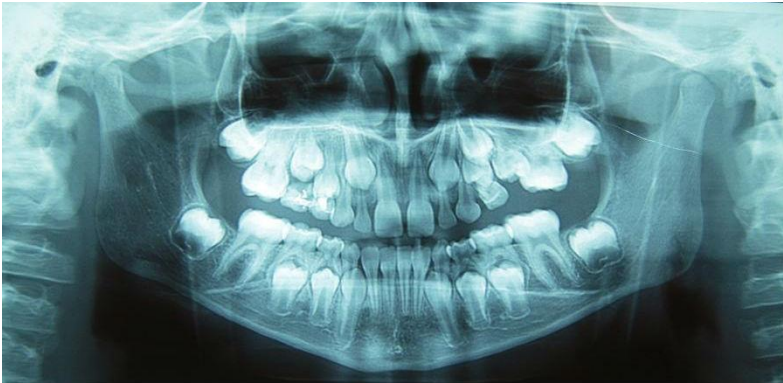Fig. 9.26 Clinical aspect of the migration of adjacent teeth and reduction of space required for the eruption of 2.5 (Collection of the Department of Pediatric Dentistry)



*Fig. 9.27 Clinical aspect of the maxillary arch with evidence of reinclusion of 6.5
(Collection of the Department of Pediatric Dentistry)*

The orthopantomographic examination confirms the reinclusion of the second primary upper left molar (6.5), the high intraosseous position of 2.5 compared to the position of 1.5, and the upper lateral incisor anodontia (Fig. 9.28).



*Fig. 9.28 Orthopantomography of the patient with clocked eruption of 2.5 by
reinclusion of 6.5 and loss of required space
(Collection of the Department of Pediatric Dentistry)*

In the first step we have achieved the removal of the obstacle represented by the second primary molar (6.5), which was extracted. The limited space, the intraosseous position, and the care not to traumatize the adjacent teeth, have made the extraction of this primary molar very difficult. Subsequently, in

the cases with primary molars in reinclusion, we initially opened the space and only afterwards we were able to realize an easier extraction.

Considering the space between 6.4 and 2.6 being too small, we decided to apply the prefabricated space maintainer between 6.3 and 2.6 (Fig. 9.29).

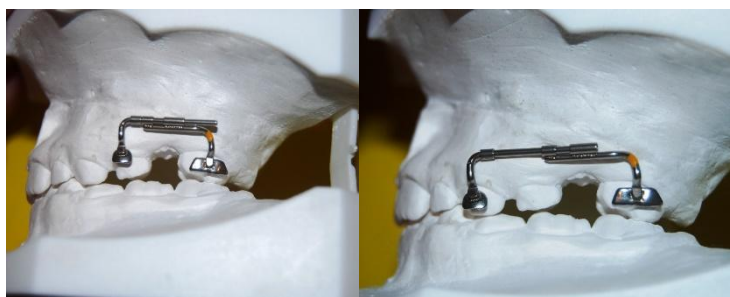


Fig. 9.29 Applying the EZ Space Maintainer between 6.4 and 2.6 (left) and 6.3 and 2.6 (right) on the study cast (Collection of the Department of Pediatric Dentistry)

Using orthodontic pliers, we adapted the prefabricated anterior and posterior arm of the space maintainer, similar to the base of the orthodontic brackets, in order to be in an optimal relation to the buccal surfaces which are to be stitched on.

EZ Space Maintainer can function both as a passive space maintainer, where after adjusting the proper length, the sliding arms are fixed and afterwards glued, and as an active space maintainer. Considering the great amount of space we needed to regain, we chose the active space maintainer. For this, we inserted a nickel-titanium dumper at the level of the anterior sliding arm. Thus prepared, the device becomes passive by approaching and connecting the two arms with a wire ligature (Fig. 9.30).



Fig. 9.30 "Passivation" of the active space maintainer in order to be stitched in the oral cavity (Collection of the Department of Pediatric Dentistry)

Once again, the adaptation of the device on the study cast is verified and then it is glued by adhesive method, similar to the technology used for fixed orthodontic appliances (Fig. 9.31, 9.32).

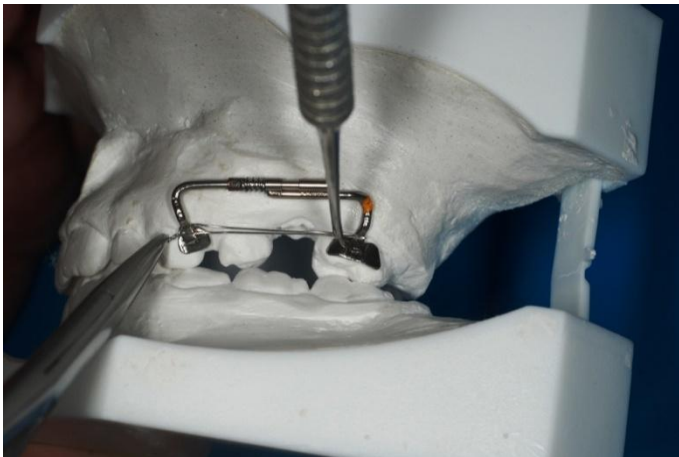
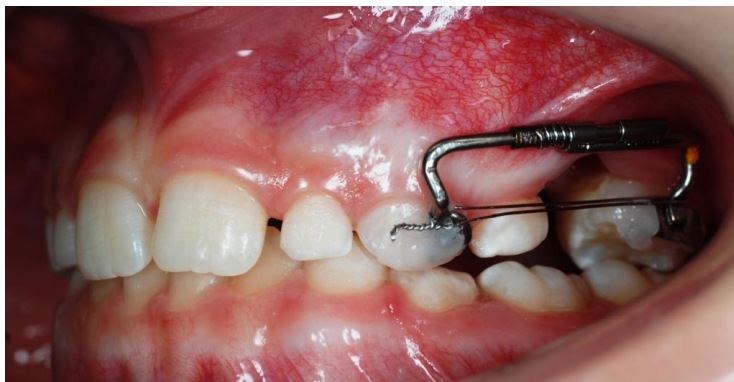

Fig. 9.31 Verification of passive adaptation on study cast (Collection of the Department of Pediatric Dentistry)



*Fig. 9.32 Intraoral adhesive cementation of the space maintainer
(Collection of the Department of Pediatric Dentistry)*

After cementing the EZ Space Maintainer, we need to cut the wire ligature and so that the prefabricated space maintainer becomes active (Fig. 9.33).

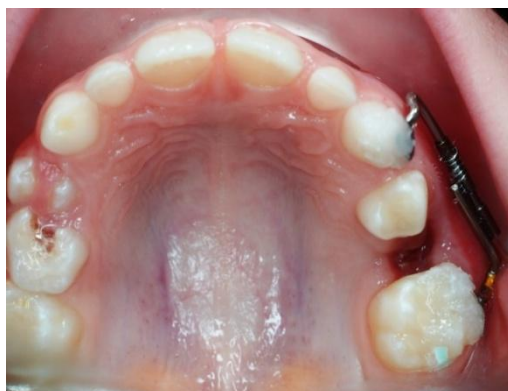

Fig. 9.33 Intraoral occlusal aspect with prefabricated SM, after removal of the wire ligature which assures passivity of the device, required for the adhesive stitching process (Collection of the Department of Pediatric Dentistry)

The initial radiological image confirms the clinical situation described above: 6.5 is in reclusion, the adjacent teeth are tilted to the apparent edentulous area, 2.5 has a vicious high position, a sign that 6.5 has prevented the physiological eruption of 2.5 (Fig. 9.34).

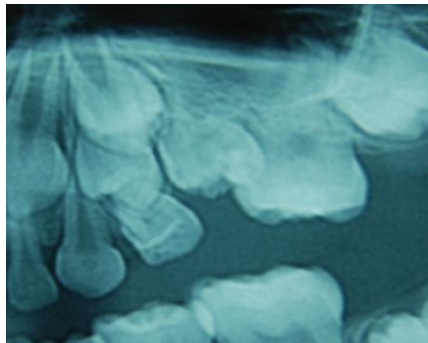


Fig. 9.34 The radiological image confirms the clinical diagnosis (Collection of the Department of Pediatric Dentistry)

The situation is different from a radiological point of view after 4 months of treatment, with 2.5 being found on its natural eruption trajectory (Fig. 9.35).

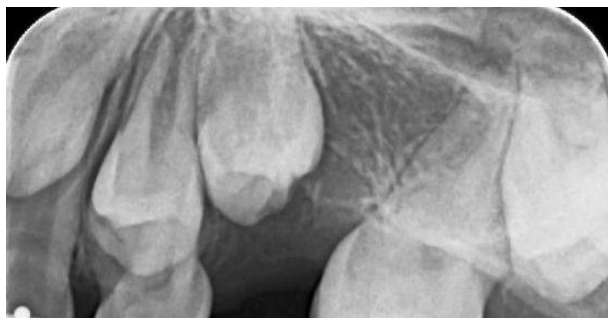

Fig. 9.35 Radiological examination after 4 months of treatment with an active MS - EZ Space Maintainer, shows the favorable evolution of 2.5 (Collection of the Department of Pediatric Dentistry)

9.9. SPACE MAINTAINERS MANUFACTURED IN THE PEDIATRIC DENTISTRY DENTAL OFFICE

This type of unilateral fixed space maintainers are an emergency alternative, in which an orthodontic wire is properly bent and fixed on the abutment teeth using composite resin (Fig. 9.36).

It is a fast method, but it has a number of disadvantages such as: the resin-tooth bond does not last long under the action of the occlusal forces, it breaks out and there is a risk of aspiration of the wire. Additionally, if the child is not brought back in the dental office to reattach the wire loop, the space may be reduced.

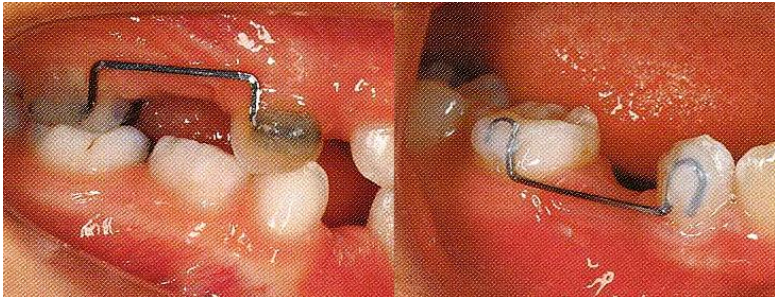
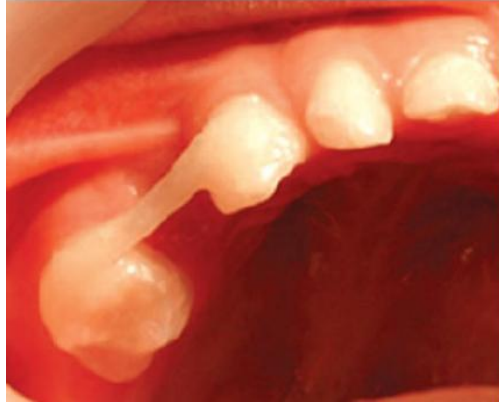


Fig. 9.36 Fixed space maintainer by the adhesive technique, made in the dental office (van Waes H, Stöckli P, 2001)

Another type of fixed space maintainer that can be made by direct technique in the dental office, is by using a reinforced fiber glass band that is fixed onto the abutment teeth using composite resin (Fig. 9.37).



*Fig. 9.37 Space maintainer made of fiber glass and composite resin
(Kirzioglu Z. et al., 2017)*

Advantages (Kirzioglu Z. et al., 2017):

- superior aesthetics (compared to metallic devices);
- ease and rapidity in manufacturing (in the dental office, by the dentist in one session);
- flexibility.

Disadvantages (Kirzioglu Z. et al., 2017):

- bacterial plaque retention in the absence of a thoroughly polished surface;
- reduced adhesion of fiber glass filaments to the composite resin matrix.

Work Technique:

- professional brushing with non-fluoridated abrasive paste;
- measuring the gap and calibrating the fiber glass strip to the appropriate length (so as to enclose both vestibular surfaces of the teeth adjacent to the edentulous gap);

- rubber dam isolation, with/without anesthesia;
- etching of vestibular enamel with orthophosphoric acid 37% (30 seconds - primary teeth, 15 seconds - permanent teeth);
- washing with water jet and drying of dental surfaces;
- application of the adhesive agent (by brushing for 20 seconds) and light curing (10 seconds), it is recommended to repeat the application of the adhesive (2-3 times) to prevent the formation of gaps during the polymerization contraction;
- applying a thin layer of composite resin to the vestibular surfaces;
- adapting and fixing the ends of the fiber glass strip to the dental surfaces;
- light curing for 40 seconds at each end of the strip;
- applying a new layer of composite covering the entire fiber glass band;
- light curing for 40 seconds;
- brushing a layer of adhesive over the entire surface of the maintainer;
- final light curing for 20-40 seconds;
- checking the gingival margin and the occlusion;
- polishing the maintainer using composite burs (Kirzioglu Z. et al., 2017, Subramaniam P. et al., 2008)

Checkups should take place within 3 months, or even earlier if the patient/parent discovers the degradation or even disappearance of the space maintainer.

9.10 PEDIATRIC CROWNS

Each primary tooth with extended coronary destruction, that needs pulpotomy or pulpectomy, should be immediately covered with a pediatric crown in order to maintain the integrity of the primary tooth crown, since the primary tooth is known to be the best space maintainer (Fig. 9.38).

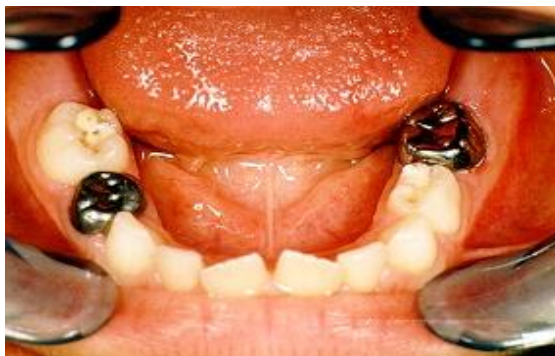

Fig. 9.38 Mandibular pediatric crowns that maintain the mesio-distal dimension of the primary teeth (Collection of the Department of Pediatric Dentistry)

Clinical steps for the preparation of teeth in order to apply pediatric metal crowns:

1. Preoperative occlusion analysis

Before the tooth preparation begins, an overview of the occlusal relationships is required, as follows: the presence of egression/extrusion caused by old carious lesions, the mesial/distal migration of the adjacent teeth due to the proximal carious processes, the presence of crowding or spacing, relationships of upper and lower incisors, canines and molars, which can be observed both intraorally and on study casts.

2. Anesthesia

To eliminate pain caused by preparation of the tooth and possible soft tissue trauma during crown adjustment, a good anesthesia is required. Anesthesia will be performed, in the mandible for the lower dental nerve and the buccal nerve, and in the maxilla buccal and palatal infiltrations.

3. Isolation

The use of the rubber dam system is indicated because it helps protect the surrounding tissues, improves visibility and efficiency, and prevents ingestion or suction of the crown during crown adaptation.

4. Removal of carious lesions and realization of pulpotomy/ pulpectomy with surface restoration using glass ionomer cement.

5. Placing a wood wedge for teeth separation, offers better access prevents iatrogeny over the adjacent teeth.

6. Tooth preparation

- *Reducing the occlusal surface*

The occlusal surface should be reduced by 1-1.5 mm, respecting the occlusal morphology that needs to be maintained. Excessive occlusive reduction can lead to deviation of the occlusion plan, low crown retention or clogging. Insufficient reduction may lead to bite opening (Fig. 9.38).

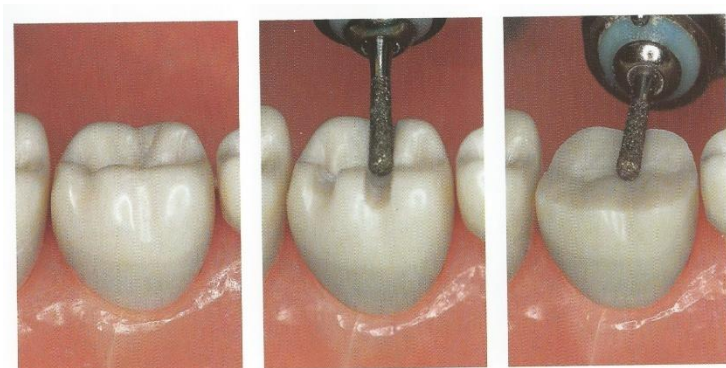

Fig. 9.38 Reduction of the occlusal surface (van Waes H, Stöckli P, 2001)

- *Proximal reduction*

The preparation should be 1 mm subgingival, in knife-edge shape. The proximal separation is done with a thin diamond-shaped instrument, with buccal-lingual movements, avoiding the enamel damage of adjacent teeth. Bleeding of the interdental papillae may occur during preparation and should not discourage the dentist from extending the preparation subgingivally to remove the threshold. Verification of the preparation will be done with a probe to check if there are thresholds and if there is enough space for crown placement. Distal reduction is recommended even if there is no adjacent tooth, in the case of the primary second molar, in order not to interfere with the eruption of the first permanent molar (Fig. 9.39).

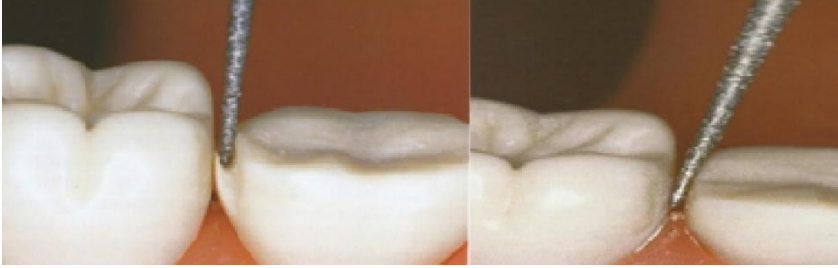


Fig. 9.39 Reduction of proximal surfaces in the knife-edge shape (van Waes H, Stöckli P, 2001)

- *Rounding of the preparation angles*

For the preparation to match the contour of the crown, all edges must be rounded with a diamond burr (Fig. 9.40). If angles are not rounded, displacement of the metal crowns may occur.

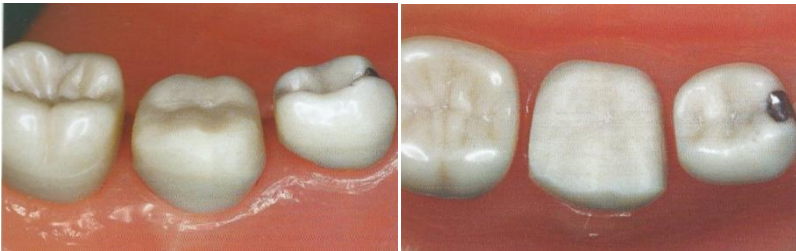

Fig. 9.40 Rounding of preparation angles - buccal and occlusal sight (van Waes H, Stöckli P, 2001)

7. Placing the dental crown

Choosing the crown is done by measuring, with the aid of a compass, the mesiodistal diameter that the pediatric crown will occupy between the two adjacent teeth of the preparation. After selecting the right size, the crown will be tested by placing it from the lingual surface, with a rotation movement towards buccal.

Shaping and adjusting the crown begins by shortening it using large-grained diamond burs and finishing with carborundum stones to avoid gum damage or using special scissors. The edge of the crown will be beveled in knife-edge shape with a stone, in order to facilitate contouring. After shortening the crown, it is necessary to check intraorally its preliminary adaptation, with the help of a probe and dental floss.

Contouring is made at the level of the last millimeter of the crown, circumferentially, to ensure good marginal adaptation, retention and, last but not least, to prevent the accumulation of a bacterial plaque. All surfaces are contoured with a "donkey-back shape" pliers, followed by a final bend with special pliers. After contouring, when placing the metal crown on the tooth, the dentist has to face a slight resistance and adaptation should occur by a slight "click".

Prior to cementing the crown, a final occlusion check is performed after removing the rubber dam. If there is an occlusal interference, there may be insufficient tooth preparation, insufficient shortening of the crown or the presence of sharp edges of the preparation. The occlusion is checked by means of the articulating paper, first without the crown and then with the crown placed on the dental field. The occlusal adaptation, if necessary, is made at the tooth level and less on the crown, since the crown is thin and there is a risk of perforation. Proximal contacts are checked with dental floss.

Previous to cementing, the final finishing of the metal crown edges with carborundous stones, abrasive discs and finishing gums is performed.

8. Setting the crown

Cementation of the metal crown begins by cleaning, washing and drying the tooth and the crown. The most commonly used material for fixing the crown is simple or resin-modified glass ionomer cement. The cementation steps can be systematized as follows:

- after selecting the material, it is prepared and applied inside the crown covering about $2/3$ of the surface;
- placing the crown on the prepared tooth is made from lingual to buccal. An orthodontic pusher can be used to position the crown;
- a cotton roll is placed between the dental arches, the patient is asked to bite on the roll, so the pressure is continuous and uniform;
- excess cement is eliminated after the time required for the material hardening using a probe and ultrasounds;
- occlusion is checked and small adjustments made.

We present you the evolution of a clinical case in which you can see the importance of applying pediatric crowns in order to protect the growth and development of the stomatognathic system (Fig. 9.41-9.43).

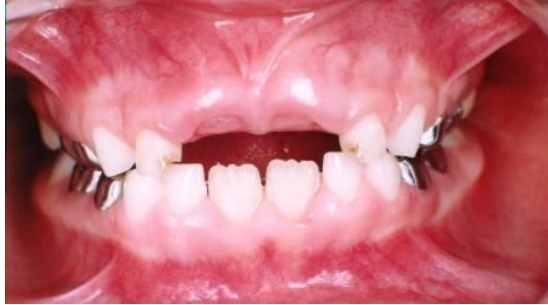

Fig. 9.41 Intraoral image of a 6-year-old patient with 8 pediatric metallic crowns on all primary molars with significant coronary destruction (Collection of the Department of Pediatric Dentistry)

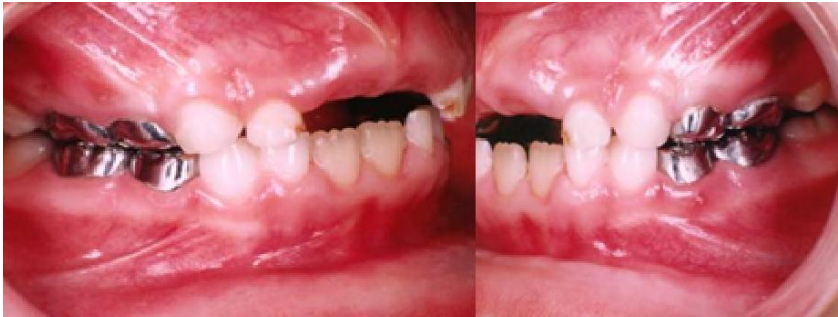

Fig. 9.42 Intraoral right and left side image showing the 8 pediatric metallic crowns (Collection of the Department of Pediatric Dentistry)

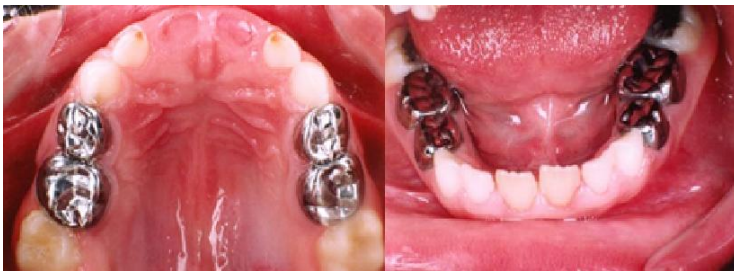

Fig. 9.43 Maxillary and mandibular occlusal image with metallic crowns covering all primary molars (Collection of the Department of Pediatric Dentistry)

After 4 years, a favorable evolution of the case is observed, with the maintenance of the pediatric crowns on the molars, exfoliation taking place along with the metal crowns, normal growth and development of the stomatognathic system with the development of correct occlusal relationships (Fig. 9.44-9.45).

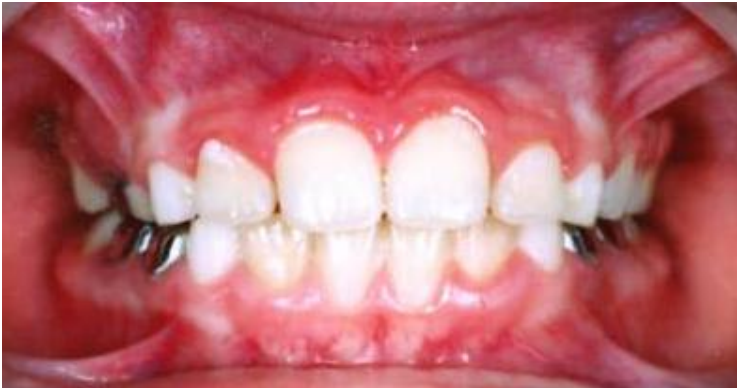

Fig. 9.44 Establishing normal occlusal reports in the frontal and lateral area of the patient from Picture 9.41 (Collection of the Department of Pediatric Dentistry)

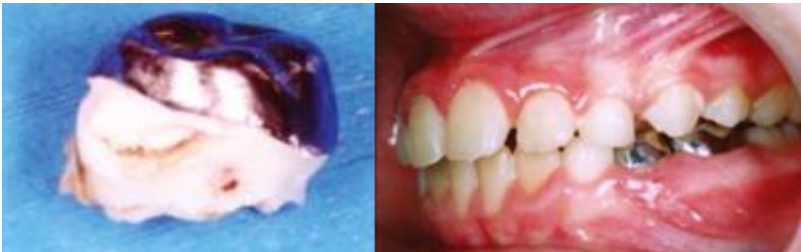

Fig. 9.45 Exfoliation of the primary molar with the pediatric metal crown and the right intraoral aspect while preserving the space needed for the eruption of the teeth in the lateral area (Collection of the Department of Pediatric Dentistry)

At present, in order to follow the increasing aesthetic requirements, metal crowns are replaced with zirconia. In the Pediatric Dentistry Department we use zirconia crowns from NuSmile USA (www.nusmilecrowns.com), which come together with pink try-in crowns that can be resterilised. This possibility makes it much easier to choose and order the right crown (Fig. 9.46-9.48).

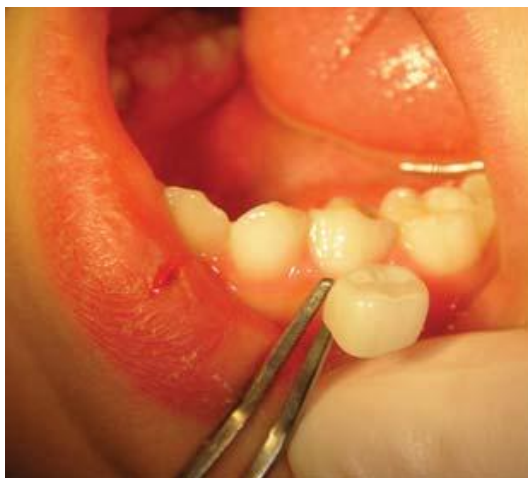

Fig. 9.46 Choosing the right zirconium NuSmile according to the space between the adjacent teeth (Collection of the Department of Pediatric Dentistry)

In addition, the zirconia crowns made by this company have the most similar morphology and color to the natural primary teeth, and also offer the adhesive system for fixing zirconia crowns - Biocem - bioactive universal cement.

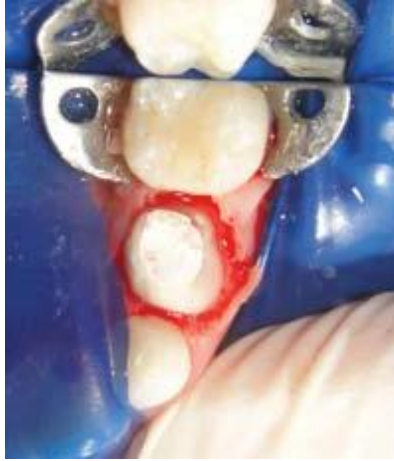

Fig. 9.47 Preparing the tooth for the application of a pediatric zirconia crown respects the manufacturer's specifications, different from those for the application of metal pediatric crowns (Collection of the Department of Pediatric Dentistry)

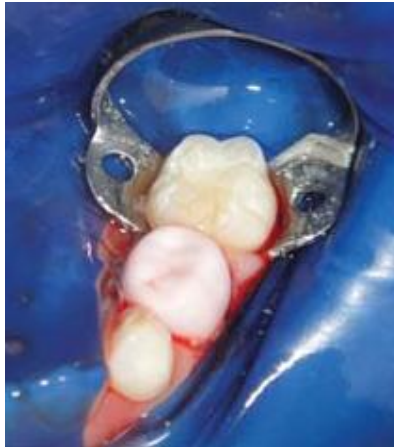

Fig. 9.48 Applying and fixing NuSmile zirconia with Biocem universal bioactive cement (Collection of the Department of Pediatric Dentistry)

Zirconia crowns fulfill the same goal of maintaining the mesiodistal and vertical dimensions, achieving also the current high aesthetic demands.

9.11 REMOVABLE AND MOBILE SPACE MAINTAINERS

They can be used both in primary and mixed dentition in extreme situations where there are no abutment teeth, either due to the loss of more primary teeth or in situations where permanent molars and/or permanent incisors have not erupted yet. They are similar to orthodontic appliances or acrylic partial removable dentures, their retention being mainly provided by wire clasps (Fig. 9.49).

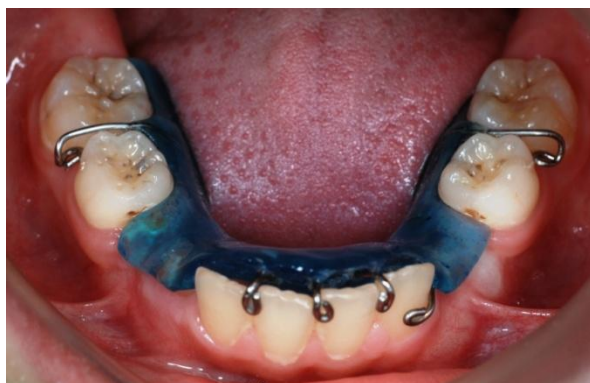

Fig. 9.49 Removable space maintainer anchored to the mandibular arch by means of clasps (Collection of the Department of Pediatric Dentistry)

It is often the only therapeutic alternative. However, retention is low, and therefore acceptance issues also appear. Children of three to six years will not tolerate a device with low retention and will not use it. The space maintainer part is provided by the acrylic elements covering the gaps, or by the wire elements which delimit the edentulous area.

The removable space maintainers can be removed and reapplied in the oral cavity by the patient. This type of

maintainer is used to preserve the mesiodistal space and vertical space. This type of maintainer also tries to improve the aesthetic and phonation functions, while the masticatory function is not functional.

Situations in which we use removable maintainers:

- When we have bilateral loss of primary molars;
- When we have a loss in the front area, to improve aesthetic and phonation functions;
- For patients who are very cooperative;
- The space maintainer is only required for a shorter period of time.

Situations in which we do not use the removable maintainers:

- Cannot be used for patients who are allergic to acrylate;
- It cannot be used for uncooperative patients;
- It cannot be used for patients who have epilepsy;

Clinical situations where removable space maintainers can be used in primary, mixed or permanent dentition are:

- Unilateral posterior maxillary loss;
- Unilateral posterior mandibular loss;
- Bilateral posterior maxillary loss;
- Bilateral posterior mandibular loss;
- Bilateral posterior and anterior maxillary loss;

- Anterior loss in primary and permanent dentition;
- Teeth loss in permanent dentition.

The removable SM have extensions at the level of the edentulous ridge, that act as a space maintainer in the form of:

- Flat acrylic sections of appropriate height in order to keep the vertical dimension, not allowing displacements such as extrusion or egression;
- Artificial teeth, especially in the case of frontal edentulous gaps (Fig. 9.50-9.51).

The component parts of a space maintainer, sometimes similar to a lingual or palatal plate, are as follows:

1. The base of the appliance
2. Anchorage elements
3. Active elements

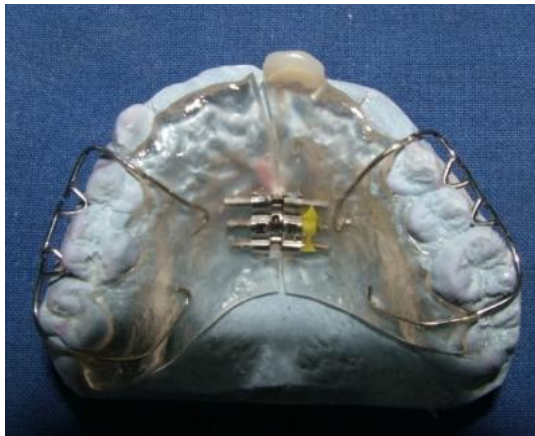


Fig. 9.50 Removable space maintainer anchored to the upper jaw arcade with clasps and prosthetic tooth replacing 21 (Collection of the Department of Pediatric Dentistry)

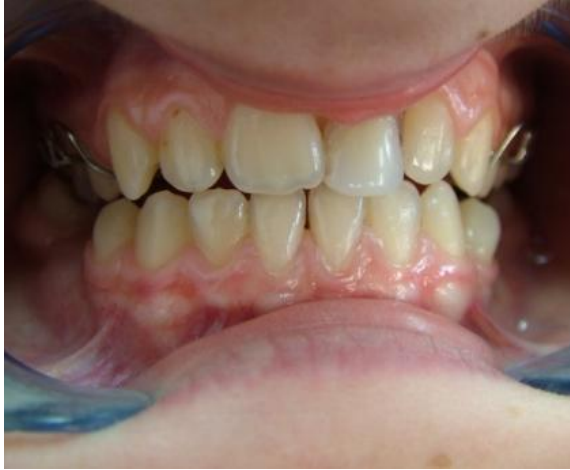

Fig. 9.51 Frontal intraoral clinical aspect of the SM from Picture 9.50 (Collection of the Department of Pediatric Dentistry)

The base of the space maintainer is made of a palatal or lingual plate. The base extends sagittal to the upper jaw, on the median line, from the frontal teeth to the intersection with the median line, with a tangent to the mesial surface of the 6-year molars. Along the arch, the plate extends from one side to the other up to the last tooth present on the arch. In a vertical plan, in the frontal area, the shape and contact of the plate to the teeth vary, depending on the therapeutic purpose followed and written by the physician in the laboratory sheet, the base of the device extending up to the incisal edge. In the lateral area, the plate extends on the palatal surface of the teeth up to the union of the middle third of the surface with the 1/3 incisal third. In the mandible, the plate is limited by the motion of the lingual frenulum, which it should not interfere with.

The characteristics and importance of the base plate are as follows:

- participates in the stability of the space maintainer;
- participates in the maintenance of the main and auxiliary wire springs;
- participates in the transmission of orthodontic forces;
- can be cut into two or more fragments, joined together by means of action elements (springs or screws);
- must be strong enough but not too thick to ensure patient comfort (2-3 mm thick, both superior and inferior);
- the edges are slightly thickened and rounded to prevent lesions;
- the mucosal surface comes in intimate and uniform contact with the maxillary mucosa; the shiny opposite surface should be as smooth, flat and polished as possible to avoid adherence, not to create additional lingual difficulties and to allow good maintenance;
- the acrylic base will be extended to edentulous gaps, serving as a space maintainer.

Manufacturing the base of the mobile appliance is made using thermal polymerized resin. In order to obtain a good quality orthodontic space maintainer/appliance, the dental technician must follow a sequence of phases. The base must be designed to be attractive to the child and to stimulate his interest and joy of wearing it. The acrylic used in making the

device has an infinite range of colors and combinations, and can also incorporate glowing elements as well as various images that give the device individuality.

The stages are:

1. Preparing the model. It should be saturated with water for 30 minutes and isolated with an acrylic mass isolator.
2. Realization of the base of the appliance by two techniques: powder and liquid technique or paste technique.

The powder and liquid technique. The powder is applied to the surface of the cast and the liquid is added until saturation, keeping the material deposited on the cast in excess liquid. On the surface of the cast, in the mass of acrylate, white dry areas may appear if the proportion of the material is not respected. The amount of liquid is deposited very slowly, until the aspect becomes from translucent, opaque. At this point, the model is placed in a pressure vessel at a temperature of 40 ° C and 2,12.5 atm for 20 minutes.

The paste technique. The paste is obtained by mixing 2.5/3 powder with liquid, then the mixture has to be drawn into a fiber-like aspect after 2-3 minutes so that its consistency allows stretching it on the surface of the cast. Consideration should be given to the retaining areas of the screw or hooks in order to avoid air inclusions. After stretching the material on the surface of the cast at the desired thickness, it should be polished with a quantity of monomer. The appliance is introduced into the expansion vessel as in the prior technique.

Of the two techniques, the pasta technique is more advantageous because it achieves a more compact structure with superior quality.

The base of autopolymerized acrylate has an inconvenience due to the quality of the acrylic material, being more prone to repairs. Making the base of thermo polymerized acrylate involves the realization of a wax-up of the future appliance, packaging, making a pattern, stuffing and polymerization of the acrylate, unpacking and processing the plate.

If the base of the appliance is made of thermal polymerized or light-curing acrylate on the working cast, it should be applied the "dust and liquid" technique slowly, until we have a saturated mixture.

3. The thermal polymerization is carried out in a special enclosure at 40-50 ° C and 2.5 atm for 20-30 minutes;
4. Finishing and polishing;
5. Cutting the plates is done either with a Horico metallic disc, either with a thin cylindrical burr or with a saw with a narrow cloth.

Anchorage elements - orthodontic clasps

Clasps use for anchorage to the dental arches the interdental triangle (papillae space) or the anatomical particularities of the teeth (divergence of the proximal dental crown surfaces, subequatorial retention or retention of the entire dental contour).

The ball clasp, delta, arrowhead, and semi arrowhead are used for anchoring in the retention of the interdental triangle.

Adams clasp and straight clasp are used for anchoring in the retention of the anatomical crown.

An orthodontic clasp has three portions:

- The portion in contact with the retention area, called *the retentive arm*;
- The elastic portion that allows the retentive arm to overcome the retention area when inserting and removing the appliance, called *the loop*;
- A portion usually made up of 2-3 folds, which the clasp is fixed on the base of the appliance with, called *the retention area*.

Of the anchoring elements, the most commonly used are:

- C clasp;
- ball end clasp;
- delta clasp;
- Jackson clasp;
- Adams clasp;
- Schwarz clasp;
- semi Schwarz clasp/half arrow;
- the interdental Alt clasp;

C clasp

It is used to stabilize orthodontic appliances, as well as to prevent migration of the adjacent teeth towards edentulous areas. Due to the fact that it does not prevent

clogging of the devices, but only their detachment, it is used to stabilize the space maintainers and less to stabilize the orthodontic appliances provided with active elements. It delimits the tooth or sections of teeth on mesial or distal, developing orthodontic forces.

Ball end clasp

This type of clasp is also called drop clasp or interdental-occlusal clasp. It is made of 0.7 mm wire and has the following components: retentive arm, loop and plate retention (Fig. 9.52).

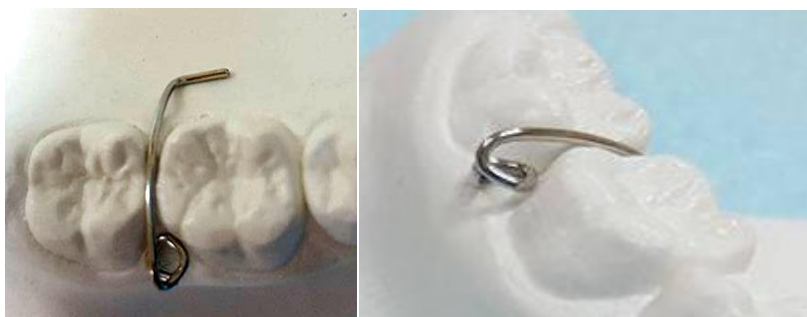

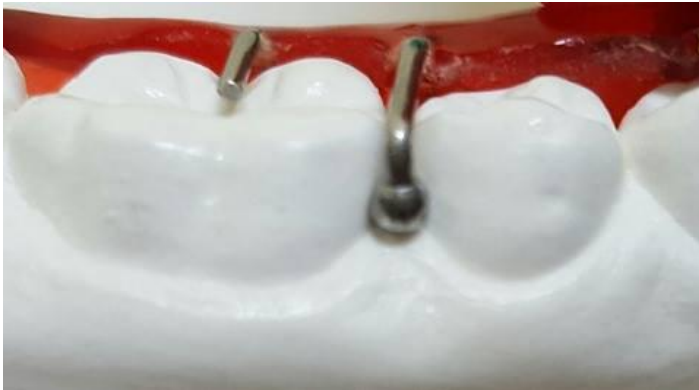Fig. 9.52 Ball end clasp - retentive arm, loop, plate retention-vestibular and occlusal sight (Collection of the Department of Pediatric Dentistry)

Characteristics:

- It assumes the existence of an interdental space where to be applied, so the existence of two primary or permanent adjacent teeth;
- Provides good stability for orthodontic appliances and space maintainers;
- Prevents the egression of the tooth on which it is applied;

- It may have premature contact with the antagonist arch, causing temporary rise of the occlusion or mandibular lateral deviation;
- It is a resistant clasp because it has only a few folds and does not fracture.

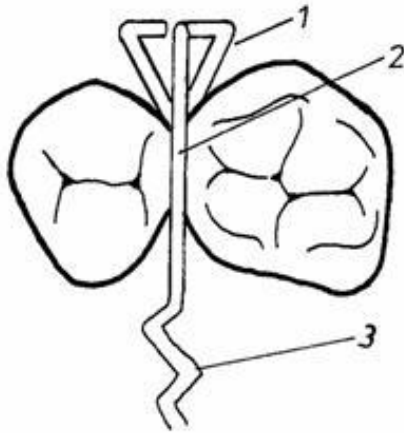
This type of clasp can be made by the dental technician, but there is also a prefabricated version that is characterized by a full sphere metal resting arm (Fig. 9.53).



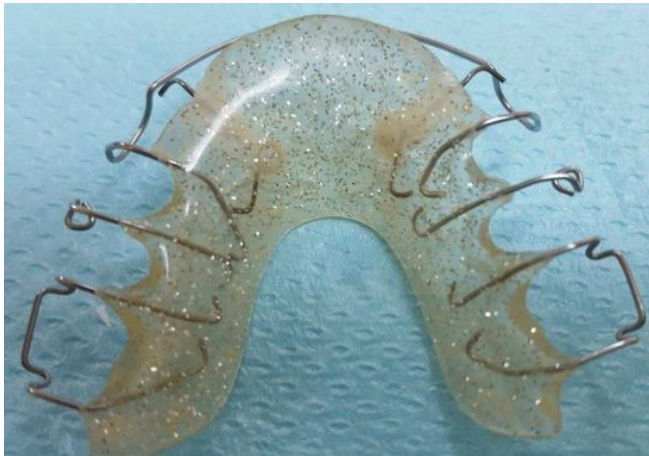*Fig. 9.53 Ball end clasp - pre-fabricated version with ball rod type
(Collection of the Department of Pediatric Dentistry)*

Delta clasp

It is an interdental-occlusal clasp like the ball end clasp, using the same retention area, the difference being given by the triangular shape resting arm, similar to the Greek delta letter. The triangular shape of the resting arm allows for a deeper engagement in the interdental space without damaging the buccal mucosa. It is also made of wire with a diameter of 0.7 mm (Fig. 9.54-9.55).



*Fig. 9.54 Delta clasp; 1 - triangular resting arm; 2 - loop; 3 - retention area
(Stanciu D, Boboc L, 2001)*



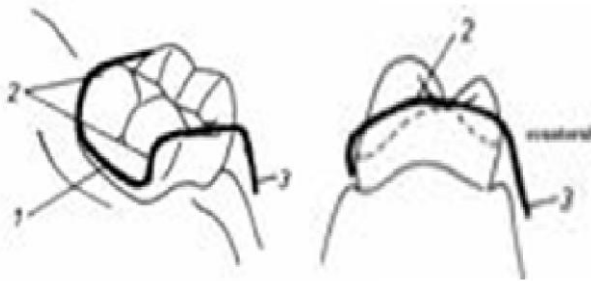*Fig. 9.55 SM with two delta clasps
(Collection of the Department of Pediatric Dentistry)*

Jackson clasp or U clasp

The wire used in the making of this clasp is elastic and has a diameter of 0.6-0.7mm (Fig. 9.56).

Characteristics:

- It interferes with the eruption of the teeth on which it is applied;
- Can be applied to isolated teeth;
- It is usually used on permanent teeth;
- The disadvantage of this type of clasp is the possibility of oral tilting of the teeth on which it is applied, reducing the retention and efficiency.



*Fig. 9.56 Jackson clasp; 1 - resting arm; 2 - loop; 3 - retention area
(Stanciu D, Boboc L, 2001)*

Adams clasp

It is also known as universal clasp and is made of 0.7 mm elastic wire. It has two oval resting arms in contact with the proximal surface, joined with a straight wire on the buccal surface (Fig. 9.57-9.58).

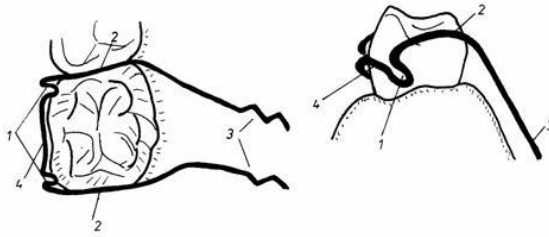
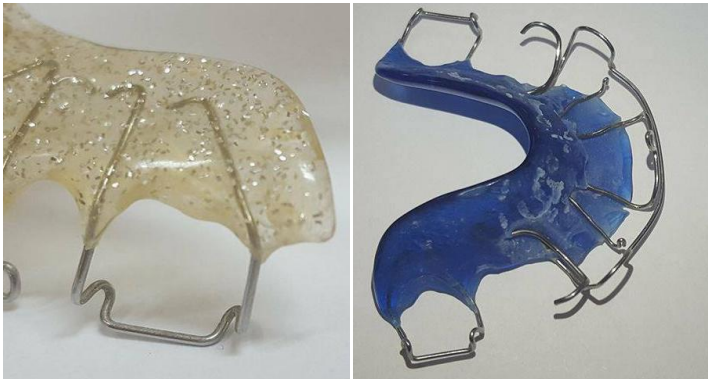

Fig. 9.57 The Adams clasp: 1-rewting arm; 2 - loop; 3 - retention are, 4 - straight area (after Adams) (Stanciu D, Boboc L, 2001).

Characteristics:

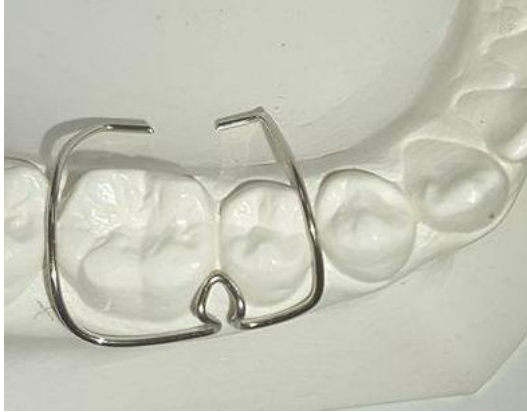- It is frequently used for SM stability;
- Used for teeth in the lateral area;
- Repair is done on the cast in the dental laboratory;
- Can be applied to isolated teeth, in both full arches or on single tooth;
- It interferes with the egression of the teeth on which it is applied;
- If it is used on the front teeth it produces clogging.



*Fig. 9.58 SM with Adams clasps
(Collection of the Department of Pediatric Dentistry)*

Schwartz clasp

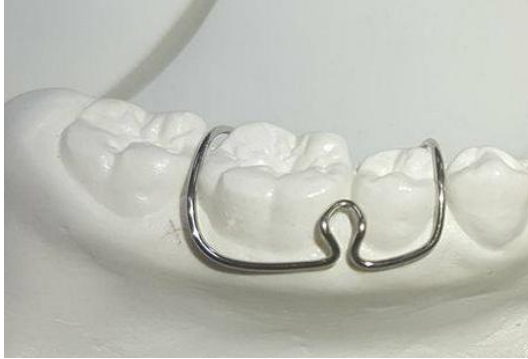The resting arm has a shape similar to an arrow. It is a multi-dental clasp, applied on 2, 3 or 4 adjacent lateral teeth (Fig. 9.59-9.60).



*Fig. 9.59 The Schwartz clasp with the arrow, loop, and retention area
(Collection of the Department of Pediatric Dentistry)*

The components of the Schwartz clasp:

- Rhombus resting arm, located in the interdental space;
- Two loops: the anterior one crossing the masticatory space between the canine and the premolar and the posterior loop at 1-2 mm from the last molar;
- Two retention areas on the base plate.



*Fig. 9.60 Schwartz clasp - buccal sight
(Collection of the Department of Pediatric Dentistry)*

The Schwartz clasp has the following features:

- Provides stability to the appliance;
- Applied only to permanent teeth in the lateral area;
- High degree of elasticity due to length;
- Allows the egression of the support area, since the occlusal surface is left free;
- The tip of the arrow penetrates into the interdental space without causing lesions to the dental papillae;
- Creates food retention areas due to numerous folds, requiring rigorous hygiene;
- The clasp can be adjusted by hand, but if there are any imperfections in the clasp, it must be restored in the dental laboratory.

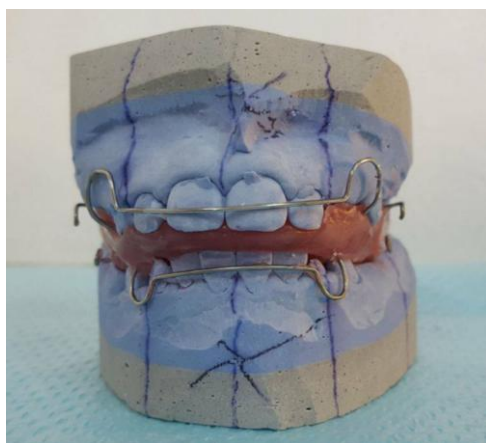
Mobile space maintainers

Functional, mobile mono-block/activator appliances may be provided with acrylic areas to act as space maintainers. These appliances oppose horizontal and vertical migrations of

the abutment teeth, transmitting vertical forces on the dental crest, and accelerating the eruption of the successors.

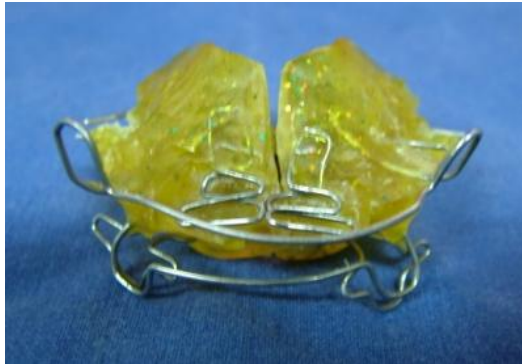
Manufacturing of a mobile SM activator involves the following steps:

- Impression: The lower arch impression should reproduce the depth of the lingual socket, the dental arch, and the vestibular alveolar ridge. The upper arch impression has to reproduce the palatal vault, the dento-alveolar arches to the buccal socket bottom.
- The working casts are poured from hard gypsum, especially for orthodontics, and will be positioned in a correlated occlusion relationship based on corrected occlusion, made by wax, realized by the physician in the dental office and tested intraorally.
- Making the action elements, which will be fixed using wax, and afterwards the wax-up of the future activator will be also be made by wax (Fig. 9.61);



*Fig. 9.61 Wax-up of the future activator
(Collection of the Department of Pediatric Dentistry)*

- The wax-up is tested intraorally, a step in which any minor imperfections can be corrected regarding the activator's adaptation on the dental arches, forced to "stay" in corrected occlusion.
- The model is then sent back to the laboratory where it will be packed in gypsum, in the sink, the wax is removed after the gypsum hardening, and after the isolation of the patterns, the thermo polymerized material is subsequently applied, which is then polymerized in the expansion vessel.
- Separation of the median portion, finishing and polishing the mono-block (Fig. 9.62).
-



*Fig. 9.62 The final aspect of the mobile SM activator type
(Collection of the Department of Pediatric Dentistry)*

The retainers used as aggregation elements can include the edentulous gap, preventing vertical and horizontal migrations; the retainer is polished at the level of the space maintainer, giving freedom of eruption to the successor and directing its axis.

Maintenance of the removable and mobile space maintainers

1. The space maintainer must be worn constantly during the day and night;
2. When it is not worn, it must be kept in its box;
3. Children are easily adapting to this type of maintainer, but there is a period of adaptation and effort carried out by the patient;
4. Before application, a good dental hygiene is required. Dental brushing is performed both before and after applying the maintainer, and after removing it from the oral cavity. SM should be also cleaned.
5. Periodic check-ups are required to detect permanent teeth eruption, growth and development of upper and lower jaws.
6. The maintainer can be changed depending on the age of the child, so as not to interfere with normal growth and development.

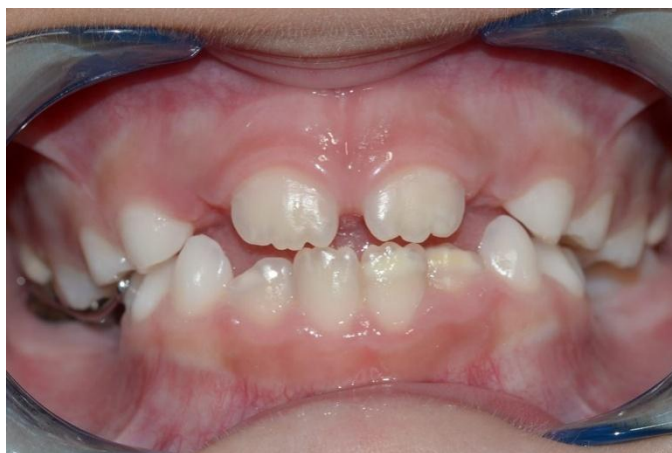10. SPACE MAINTAINERS IN THE DIGITAL ERA

Digital technology, with all its advantages, finds its usefulness in pediatric dentistry in the making of space maintainers. Schematically the steps to be taken are the following:

1. The digital impression is made using an intraoral scanner that converts the images obtained from the oral cavity into data to be processed by the computer. This digital impression technique allows a direct visual inspection of the procedure, repeating it as often as necessary, but also involves direct access to the area to be scanned;
2. Data previously taken from the oral cavity is processed using a specialized software program to help design the future SM;
3. Printing with a 3D printer the working casts and SM mock-up for intraoral verification of the mock-up thus obtained;
4. Pouring the SM in metal is made either classically, by wrapping the SM in plastic or by current laser-melting technology;
5. SM preparation and intraoral cementation.

As an example, we will present the case of a 7-year-old patient referred to the Pediatric Dentistry Discipline from Timisoara for the treatment of carious lesions and the monitorization of the dental eruption. Considering that the

clinical examination revealed the early loss of two primary lower molars, a loss that turned out from the anamnesis to have resulted from the extraction of the radicular rests about 4 months ago, the application of a SM is decided. With the incomplete eruption of the lower front group, it is decided to apply 2 passive band and loop SM, the one on the right hemiarch achieved through the classical technique and the one on the left hemiarch achieved through CAD/CAM technology (Fig. 10.1).



*Fig. 10.1 A 7-year old patient with early loss of two primary lower molars
(Collection of the Department of Pediatric Dentistry)*

By the goodwill of the associate professor Dr. Anca Jivanescu, digital impressions are taken in the Department of Prosthodontics, from the left mandibular hemiarch and the left maxillary hemiarch with the aid of PlanScan intraoral scanner from Planmeca, obtaining a virtual model represented by a .stl file to be transmitted to the CAD component (Fig. 10.2-10.6).

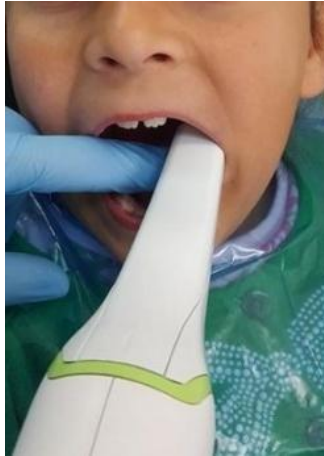

Fig. 10.2 Digital impression with the intraoral scanner of the left mandibular hemiarch in the patient from Fig. 10.1 performed in the Department of Prosthetic Dentistry

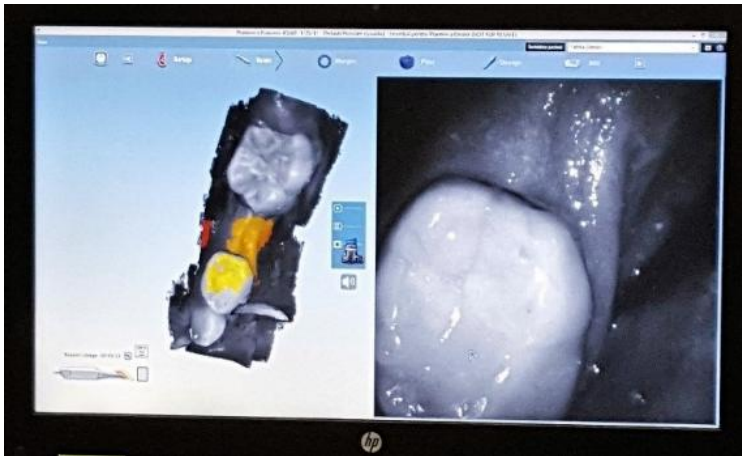


Fig. 10.3 An image during the optical impression allowing a direct real-time assessment of the impression result as well as a repeating the procedure in areas that are not adequately highlighted




Fig. 10.4 The virtual model of the area of interest (left mandibular hemiarch) where the SM is going to be applied



Fig. 10.5 The virtual model of the antagonist hemiarch



Fig. 10.6 The virtual model of the two hemiarches in occlusion

Using a design system, the design of the virtual space maintainer is realized with the 3Shape Dental Design System D500 software from Wieland in the case of a simple maintainer and Exocad Design with the Dentures Partial Frameworks module for the occlusal spur holder and the two retention arms (Fig. 10.7-10.9).

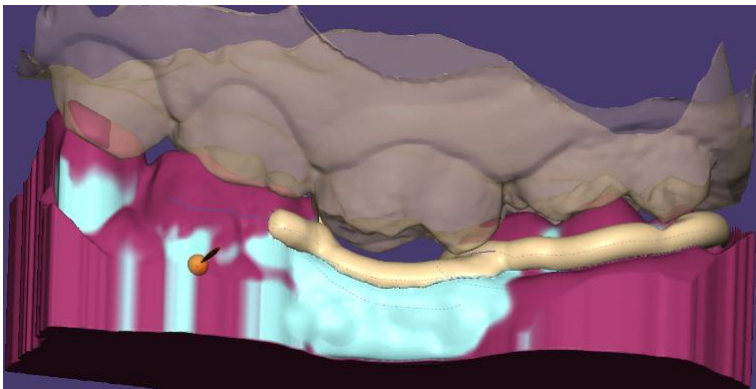


Fig. 10.7 BUCCAL aspect of the SM digital mock-up

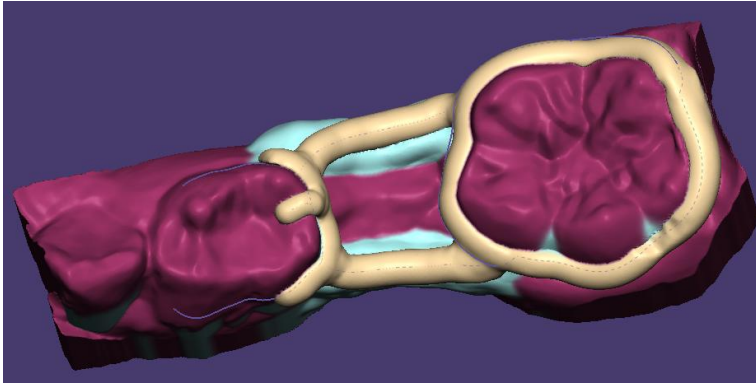


Fig. 10.8 The OCLUZAL aspect of the SM digital mock-up

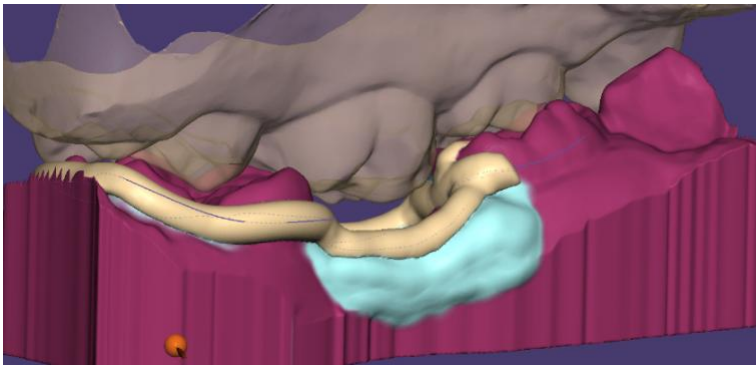


Fig. 10.9 LINGUAL aspect of the SM digital mock-up

The virtual space maintainer and impression are sent to the 3D printer (Formlabs 2), from where a transparent physical resin model is obtained through an additive technique (Fig. 10.10). The advantages of the additive technique, unlike the subtractive technique, are the material economy and the much wider complexity of the finished product, which is the technology of the future.



Fig. 10.10 The two study casts and space maintainer obtained through 3D printing

The space retainer made of plastic was used as an intermediate sample after its primary processing and removal of the supporting stem (Fig. 10.11).

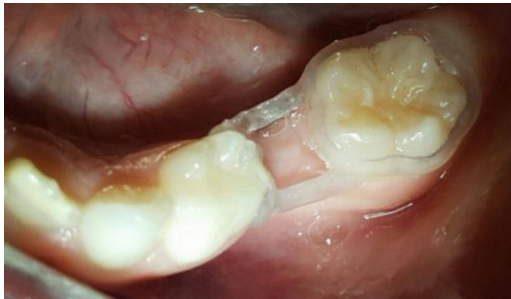

Fig. 10.11 Intraoral test of the plastic mock-up of the SM

Both the SM mock-up and the 3D print casts are used later as teaching material.

With the SM mock-up made of plastic, either the classic casting method or the modern laser-melting technology can be used to obtain a metal SM. The final treatment was done in an electrolytic bath followed by sandblasting the internal part of the SM. (Fig. 10.12).



Fig. 10.12 Final aspect of SM, mock-up and plastic casts

Eventually, verification of SM in the patient's oral cavity and occlusion check revealed excellent adaptation. After isolating the two teeth, the SM cementation was made with self-adhesive resin cement, with double bond, from GC: G-CEM Linkace (Fig. 10.13).

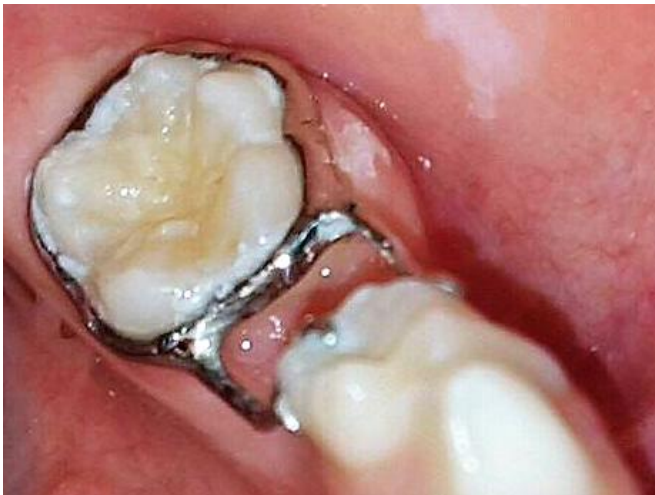

Fig. 10.13 Clinical aspect after fixation of the prefabricated SM

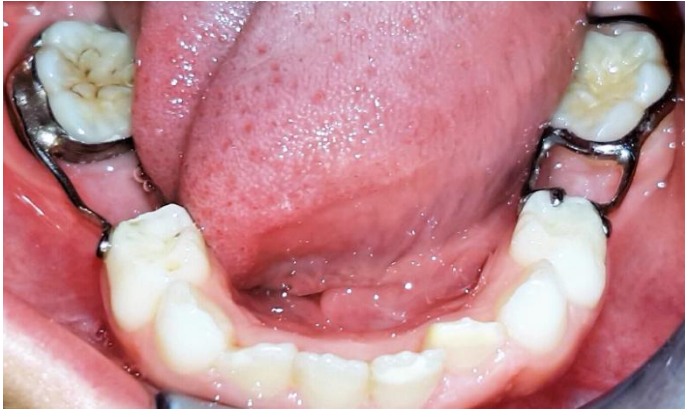

Fig. 10.14 Final clinical aspect after application of the 2 types of space maintainers

In comparison, the two space maintainers applied for the same clinical situation - the early loss of the two primary lower molars - the one on the right is obtained by classical technique and the one on left was obtained by digital technology (Fig. 10.14).

11. CLINICAL EXAMPLES AND EXERCISES REGARDING SELECTION OF THE APPROPRIATE SPACE MAINTAINERS FOR DIFFERENT CLINICAL SITUATIONS

Clinical exemplification no. 1

8-year-old patient with 6.5 coronary destruction, furcation pathology and loss of necessary space for 2.5 to erupt, due to the distal eruption of 2.4. Applied treatment: Fixed maxillary SM, unilateral, active, band and loop type. After 1 year and 3 months, the eruption of 2.5 is observed within the "protection zone" performed by SM (Fig. 11.1-11.4).

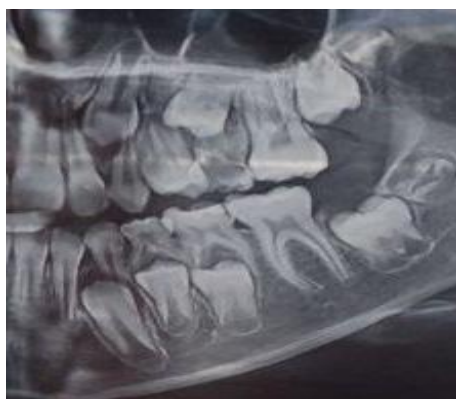
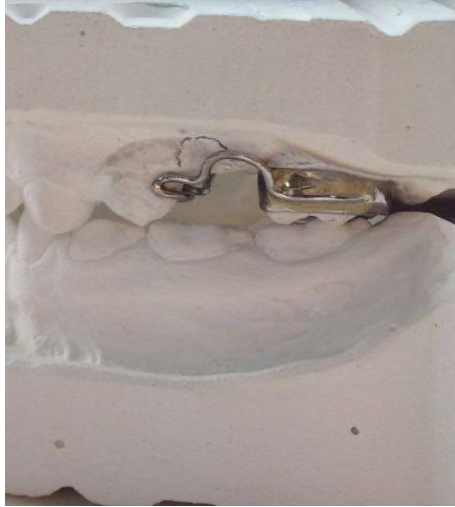
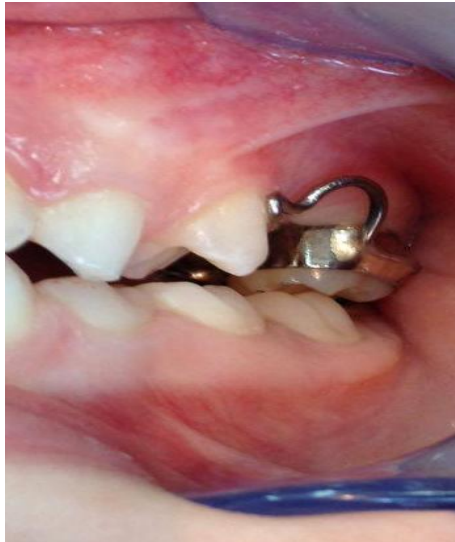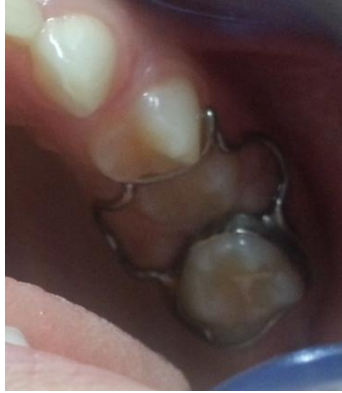Fig. 11.1 Significant coronary destruction of 6.5, distal eruption of 2.4 - Orthopantomography (Collection of the Department of Pediatric Dentistry)



***Fig. 11.2 Active band and loop space maintainer applied to regain the space required for the eruption of 2.5
(Collection of the Department of Pediatric Dentistry)***



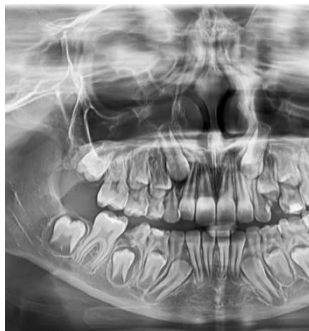***Fig. 11.3 Intraoral aspect of the fixed space maintainer
(Collection of the Department of Pediatric Dentistry)***



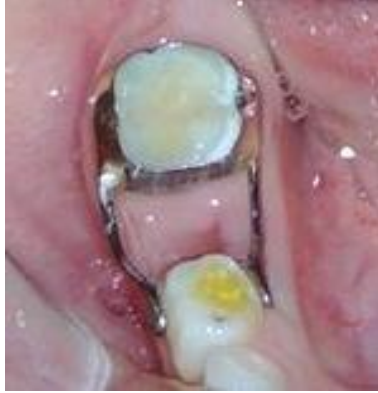*Fig. 11.4 After 1 year and 3 months, the eruption of 2.5 is observed - intraoral aspect of the patient from Fig 11.1
(Collection of the Department of Pediatric Dentistry)*

Clinical exemplification no. 2

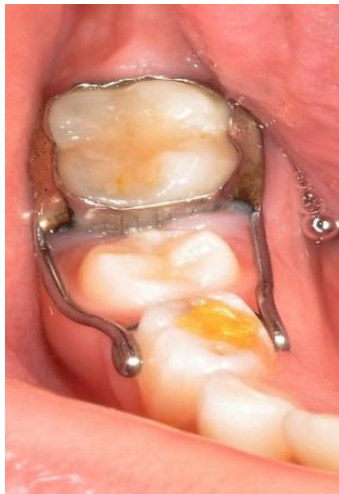A 9-year-old patient presents a massive coronary destruction of the primary right lower molar, with root resorption, and as a result extraction is indicated. Since measurements and calculations do not indicate that there is a significant space loss at this level, we decided to apply a fixed, unilateral, mandibular, passive band and loop SM (Fig. 11.5-11.7).



*Fig. 11.5 The destruction of 8.5, with presence of pathological root resorption and furcation pathology indicated the need of extraction for 8.5
(Collection of the Department of Pediatric Dentistry)*



*Fig. 11.6 Application of a passive band and loop SM on 4.6
(Collection of the Department of Pediatric Dentistry)*



*Fig. 11.7 Clinical evolution of the case from Fig. 11.5 and 11.6 with the correct eruption of 4.5 within the SM, at which time SM removal is required
(Collection of the Department of Pediatric Dentistry)*

Clinical exemplification no. 3

A 10-year patient with bilateral loss of primary second mandibular molars, with reduced space required for the eruption of permanent successors. Applied treatment: 2 fixed

mandibular active band and loop SM with activation loops. The patient initially presented for regular check-ups and then came only after 1 year and 7 months after the application of SM, at the time of the eruption of 3.5 and 4.5, which required the removal of space maintainers (Fig. 11.8- 11.10).

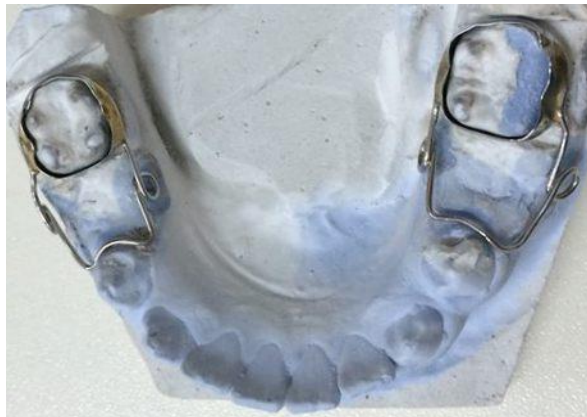

Fig. 11.8 The two fixed SM, with bilateral activation loops, on the working cast (Collection of the Department of Pediatric Dentistry)

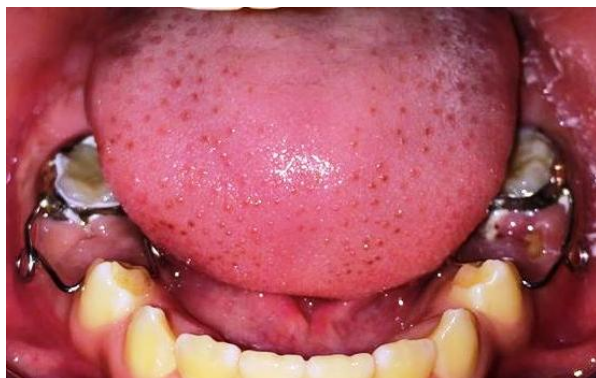

Fig. 11.9 Cemented space maintainers - intraoral aspect (Collection of the Department of Pediatric Dentistry)

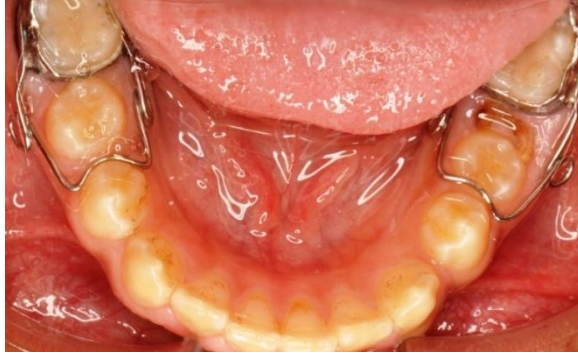

Fig. 11.10 After 1 year and 7 months, the almost complete eruption of the two premolars is observed in the "inside" of the space maintainers' loops - urgent removal of SM (Collection of the Department of Pediatric Dentistry)

Clinical exercise no. 1

A child presents coronary destructions of primary second mandibular left and right molars (7.5, 8.5) and radiologically, furcation pathology of both molars can be observed, therefore extraction is needed(Fig. 11.11).

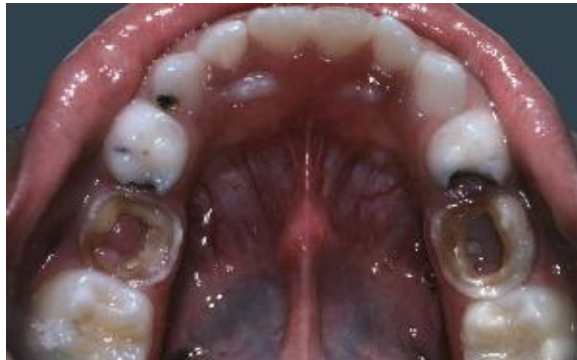

Fig. 11.11 Patient with coronary destruction and furcation pathology of 7.5 and 8.5

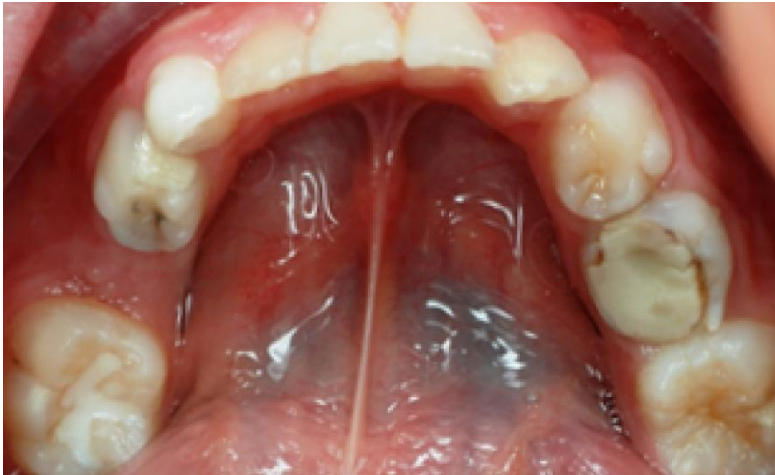What kind of space keepers are indicated in this case?

Clinical exercise no. 2

The lower incisive sum is 28 mm, the upper incisive sum is 34 mm, the maxillary available space is 75 mm and the mandibular is 73 mm. What is the space balance at the mandibular and maxillary level?

Clinical exercise no. 3

An 8 year old child (dental age) has an early loss of the second primary mandibular molar (7.5) (Fig. 11.12). What kind of space maintainer is indicated?



*Fig. 11.12 Unilateral early loss of 7.5
(Collection of the Department of Pediatric Dentistry)*

Clinical Exercise No.4

What kind of space maintainer will be applied to the upper jaw in the late mixed dentition (first molars and permanent incisors have erupted) after the bilateral loss of the two primary molars?

Clinical exercise no. 5

What kind of space maintainer will be applied to the mandible, having the first permanent molars erupted and permanent incisors in eruption, after the early loss of 3 mandibular primary molars (7.4, 7.5, 8.4)?

Correct answers:

Clinical Exercise no.1: Although there is a bilateral loss of two primary mandibular molars, a lingual arch can not be indicated as a space maintainer, given that it is a premature mixed dentition with inferior lateral incisors still in eruption. It is possible to apply either two band and loop SM on 3.6 and 4.6, or if the treatment of the proximal carious lesions of the first primary molars (7.4, 8.4) involves performing pulp therapy, two pediatric crowns with loops can be applied on 7.4 and 8.4.

Clinical Exercise no.2: There is moderate crowding in the mandible, with a space gap of 4 mm and in the maxilla there is a severe crowding with a space gap of 9 mm.

Clinical Exercise no.3: Due to the loss of space required for the second left mandibular premolar to erupt, the mesial migration of 3.6 requires an ACTIVE space maintainer to regain lost space. You can apply either a band and loop on 3.6 with activation loops, or a pediatric crown and loop with activation loops on 7.4, or a lingual arch provided with an activation loop in the third quadrant, or an asymmetric lip-bumper.

Clinical Exercise no.4: Nance palatal holding arch (Fig. 11.13).

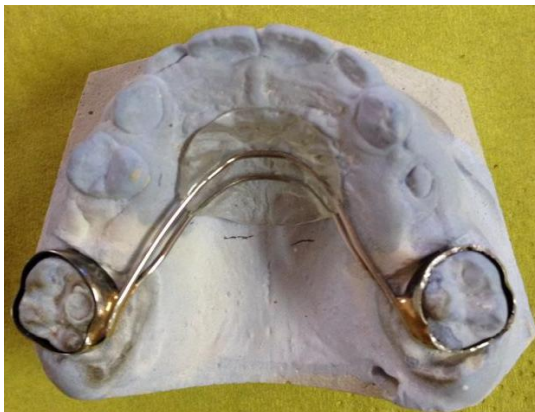

Fig. 11.13 Nance palatal holding arch in late mixed dentition, working cast
(Collection of the Department of Pediatric Dentistry)

Clinical Exercise no.5: Removable lingual plate-type space maintainer with acrylic elements that act as space maintainers (Fig. 11.14).

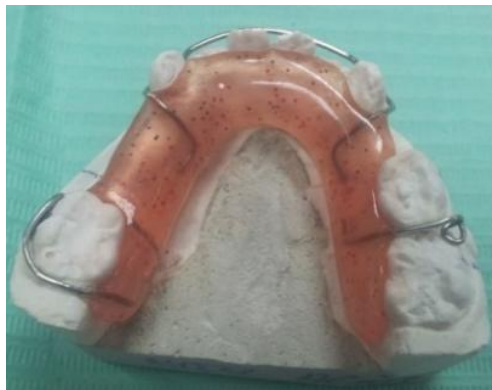
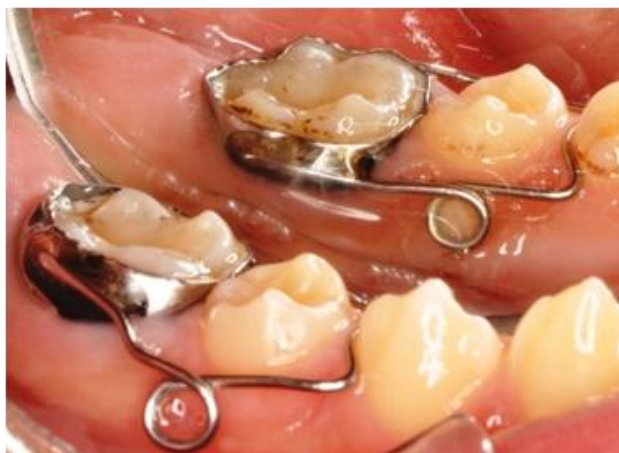
Fig. 11.14 Lingual plate on the working cast
(Collection of the Department of Pediatric Dentistry)

Instead of concluding, I will use an image that I hope it will remain alive in the memory of those who have gone through these pages (Fig. 11.15) ...it is the essence of our approach...we hope that all who have read this book will be able to "protect" a miracle of growth and development of the stomatonathic system: dental eruption.



*Fig. 11.15 A success of space maintenance and a failure of monitoring it because SM had to be removed long ago
(Collection of the Department of Pediatric Dentistry)*

REFERENCES:

1. Albandar JM, Rams TE: Risk factors for periodontitis in children and young persons. *Periodontol* 2000, 29:207–222, 2002.
2. Amano A, Kishima T, Akiyama S, et al: Relationship of periodontopathic bacteria with early-onset periodontitis in Down's syndrome. *J Periodontol* 72:368–373, 2001.
3. Amano A, Kishima T, Kimura S, et al: Periodontopathic bacteria in children with Down syndrome. *J Periodontol* 71:249–255, 2000.
4. Andlaw RJ, Rock WP: *A Manual of Paedodontics*, Longman Singapore Publishers Ltd., 1987
5. Baer PN et al.: *Pediatric and Adolescent Periodontology*, 1974, Lippincott Company, U.S.A.
6. Benjamin SD, Baer PN: Familial patterns of advanced alveolar bone loss in adolescence (periodontitis). *Periodontics*. 1967 Mar-Apr;5(2):82-8
7. Bimstein E, Delaney JE, Sweeney EA: Radiographic assessment of the alveolar bone in children and adolescents. *Pediatric Dent*. 1988 Sep;10(3):199-204.
8. Bishara SE: *Textbook of Orthodontics*, W. B. Saunders Company, 2001; 31-80, 134-142
9. Bishara SE, Jacobsen JR, Treder JE, Nowak A: „Arch width changes from 6 weeks to 45 years of age”, *American Journal of Orthodontics and Dentofacial Orthopedics*, 1997; 111:401-409.
10. Bratu E, Glăvan F. et al: *Pedodontics Practice*, 3rd Edition, University Horizons Ed., Timișoara, 2005
11. Bratu E. et al. *Pedodontics Practice*, Helicon Ed., Timișoara, 1998
12. Califano JV; Research, Science and Therapy Committee. American Academy of Periodontology. Position paper: periodontal diseases of children and adolescents. *J Periodontol* 2003;74:1696-704.

13. Casamassimo S. Paul et al., Pediatric dentistry: infancy through adolescence – 5th ed., 2013, Elsevier Saunders, Missouri
14. Cichon P, Crawford L, Grimm WD. Early-onset periodontitis associated with Down's syndrome-clinical interventional study. *Ann Periodontol*. 1998 July;3(1):370-80.
15. Comparelli U, Atlante O, Futura Publishing Society, Italia, 1999
16. Delaney JE. Periodontal and soft-tissue abnormalities. *Dent Clin North Am*. 1995 Oct;39(4):837-50.
17. Dénes József, Hidasi Gyula Pediatric dentistry, Orthodontics, Ed. Semmelweis, Budapest, 1998
18. Dincer M., Haydar S., Unsal B., Turk T: Space maintainer effects on intercanine arch width and length, *J Clin Pediatr Dent*, 21(1), 1996, 47-50
19. English JD., Peltomaeki T, Pham-Litschel K. *Mosby's Orthodontic Review*, 2009;
20. Enlow DH., Hans MG., *Essentials of Facial Growth*, W.B. Saunders Company, 1996
21. Fábíán G., Dénes Zs., Gábris K. Consequences of the early loss of milk molars and possibilities of using Space Maintainers, *Fogorvosi Szemle*, 8:241-272, 1996
22. Fields HW: Treatment of moderate nonskeletal problems in preadolescent children. in Proffit W.R.– *Comprehensive Orthodontics*, 3rd ed. St. Louis, C.V.Mosby, 1999
23. Gegenheimer R., Donly K.J: Distal shoe: a cost effective maintainer for primary second molars, *J Pediatr Dent*, 14: 268-269, July-August, 1992
24. Ghafari, J.: Early treatment of dental arch problems. I. Space maintenance, space gaining. *Quintessence Int*, 17: 423-432, July, 1986
25. Graber T, Vanarsdall: *Orthodontics-Current Principles and Techniques*, 1994

26. Karaman AI, Kir N, Belli S: Four applications of reinforced polyethylene fiber material in orthodontic practice, *Am. Journal of Orthodontics and Dentofacial Orthopedics*, June, 2002, 109-114
27. Kinder Dent Shop – Katalog 2002
28. Kirzioglu Z. et al. Clinical Success of Fiber-reinforced Composite Resin as a Space Maintainer. *The Journal of Conprimary Dental Practice*, 2017; 18(3):188-193
29. Krogman WM, *Child growth*, Ann Arbor, Mich, 1972, The University of Michigan Press
30. Law CS, Silva DR, Duperon DF, Carranza FA. Gingival Disease in Childhood. In Newman MG, Takei HH, Klokkevold PR, Carranza FA. *Carranza's Clinical Periodontology*, Twelfth Edition, Elsevier, 2015, p.252-260.
31. Lindemeyer R.G., Glavich GG: Space maintainer for the loss of a permanent molar in the adolescent patient: report of case, *ASDC J Dent Child*, June, 63(3), 1996, 213-5
32. Loe H, Brown LJ. Early onset periodontitis in the United States of America. *J Periodontol* 1991;62:608-16.
33. Mathewson R., Primosch R. *Fundamentals of Pediatric Dentistry*, Quintessenz Publishing Co, Chicago, 1995
34. McNamara JA. „Growth and Treatment: a Meeting of the Minds”, *Craniofacial Growth Series*, 2004, The University of Michigan, Ann Arbor Michigan;
35. Merchant N. Sherin et al., Localized Aggressive Periodontitis Treatment Response in Primary and Permanent Dentitions, *J. Periodontol* 2014; 85: 1722-1729
36. Ngan P., Alkire RG., Fields H. jr. Management of space problems in the primary and mixed dentitions, *JADA*, vol 130, September 1999, 1330-9
37. Novak MJ, Stamatelakys C, Adair SM. Resolution of early lesions of juvenile periodontitis with tetracycline therapy alone: Long-

- term observations of 4 cases. *J Periodontol* 1991;62:628-33.
Erratum 1992;63:148.
38. Ogorescu Ana Emilia: Current Standards of Growth and Development of the Stomatognathic System, PhD thesis, 2011
 39. Proffit WR et al., *Comprehensive Orthodontics*, ed.5, St Louis, 2012, Mosby
 40. Reyner D. Terlaje, Kevin J. Donly: Treatment planning for space maintenance in the primary and mixed dentition, *J. of Dentistry for Children*, March-April 2001
 41. Roshna T, Nandakumar K. Generalized aggressive periodontitis and its treatment options: case reports and review of the literature. *Case Rep Med*. 2012;2012:535321.
 42. Santos V.L., Almeida M.A., Mello H.S., Keith O: Direct bonded space maintainers, *J Clin Pediatr Dent*, Vara 1993, 17(4), 221-5
 43. Stanciu D, Boboc L - *Practical Orthodontics*. Ed. Medical, Bucharest, 2001
 44. Stillman JH: „Dimensional changes of dental arches: longitudinal study from birth to 25 years”, *Am J Orthod*, 1964; 50: 824-42.
 45. Subramaniam P, Babu GKL, Sunny R. Glass fiber–reinforced composite resin as a space maintainer: A clinical study. *Journal of Indian Society of Pedodontics and Preventive Dentistry*, 2008; 26(7): 98-103
 46. van Waes H, Stöckli P: *Kinderzahnmedizin*, Georg Thieme Verlag Stuttgart-New York, 2001
 47. Varga Imola: Control of Space in Mixed Dentition with Space Holders, Bachelor's Thesis, Timisoara, 2003
 48. Zarnea Livia: *Pedodontics, Didactic and Pedagogical Ed.*, Bucharest, 1993
 49. Zetu Irina, Păcurar Mariana: Introduction to the Straight Arc Technique-Volume I, Necessary Analyzes, Lyra Ed., Târgu Mureș, 2003