

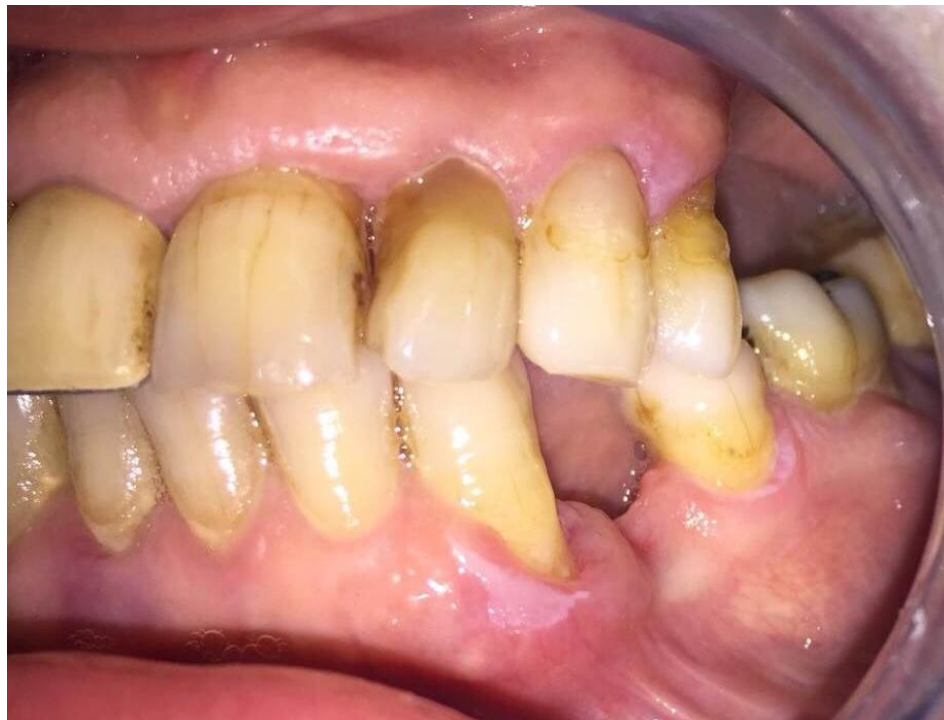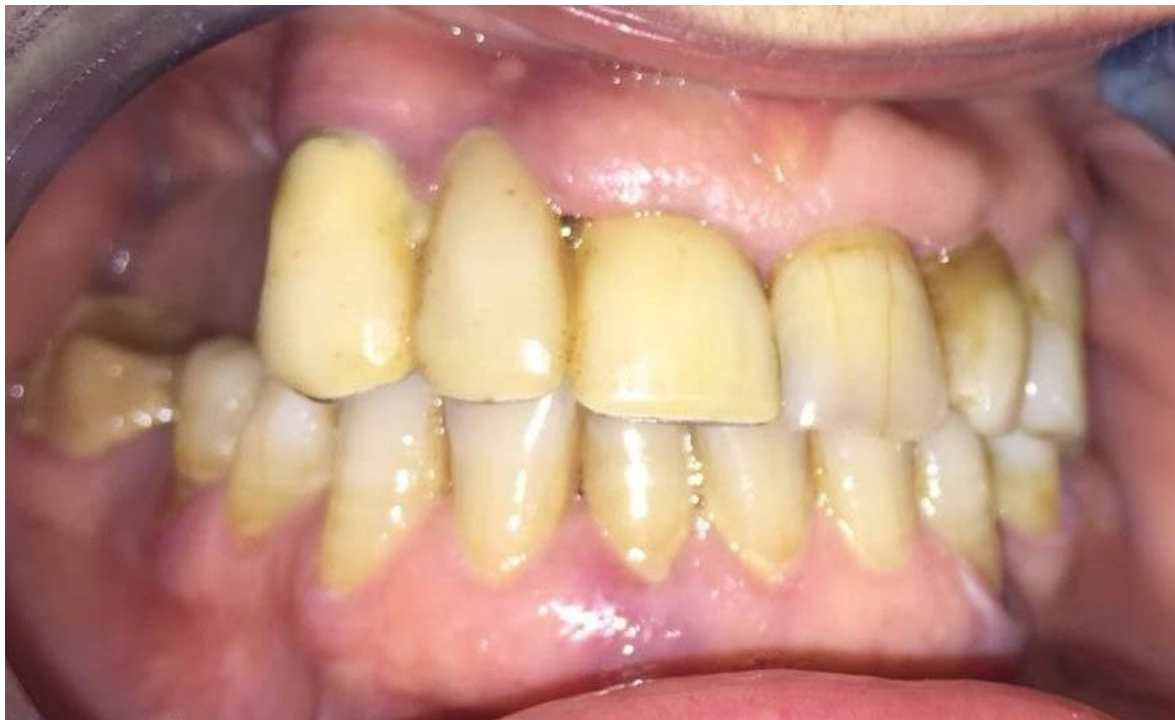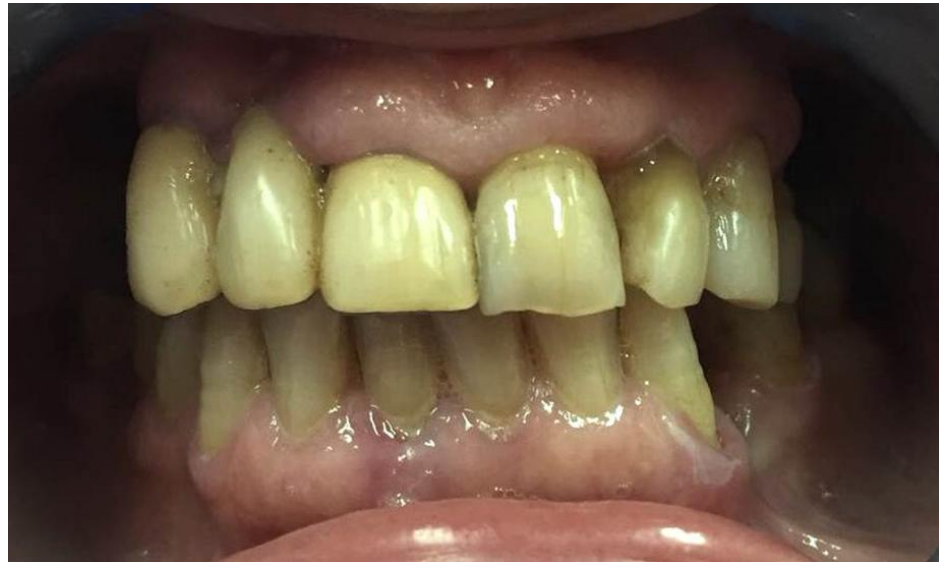# Prezentare de caz

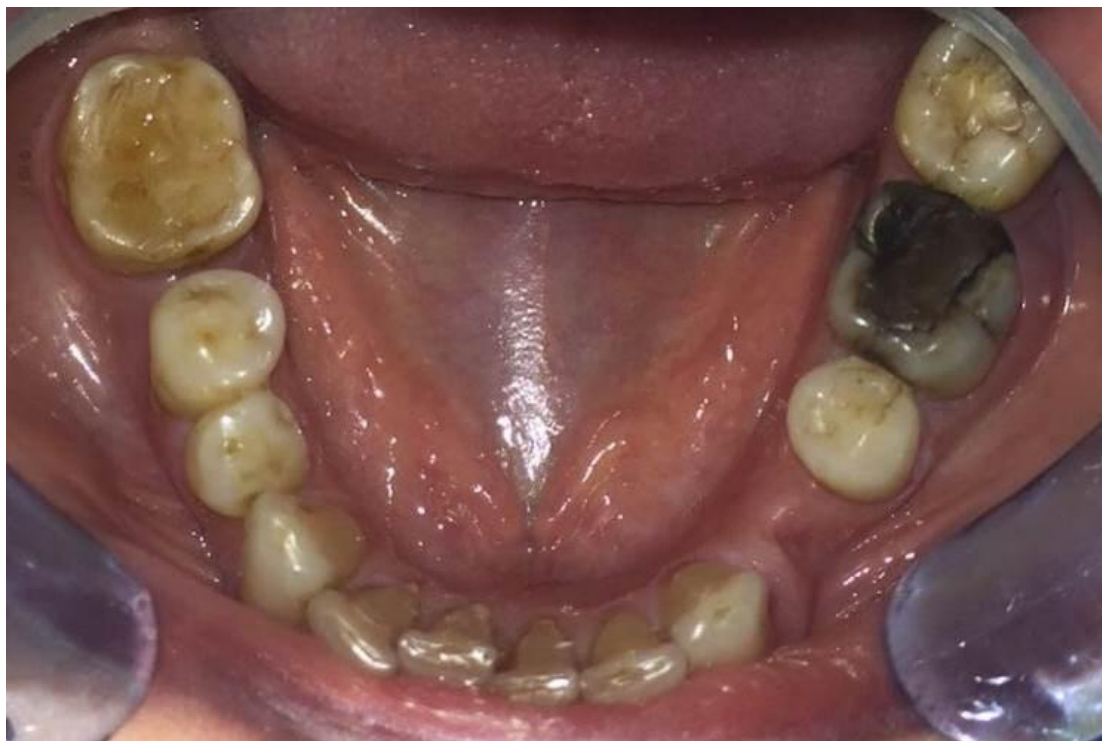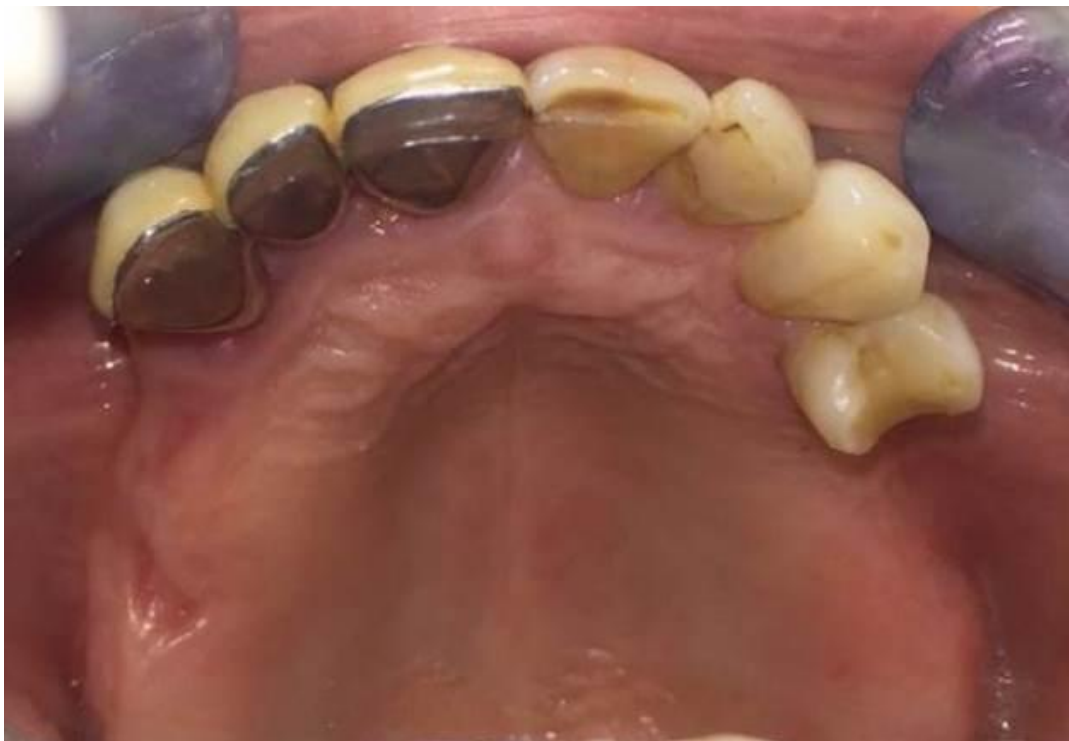- T.D., 55 ani
- Motivul prezentarii: sangerare gingivala la periaj

## ISTORICUL MEDICAL

- Antecedente personale: tulburare anxioasa
- Factorii de risc asociati: fumat (tigara electronica)

## ISTORICUL DENTAR





Nume pacient


Data nașterii 25.08.1963

☒ Prima examinare ☐ Reevaluare

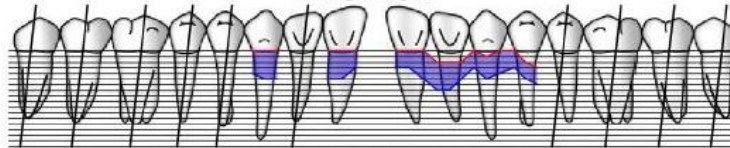
Clinician Skumpija Denis

	18	17	16	15	14	13	12	11		21	22	23	24	25	26	27	28
Mobilitate						0		0		0	0	0	0				
Implant																	
Furcație																	
Sângerare la sondare																	
Placă																	
Marginea gingivală						0	0	0		0	0	0	0	0	0	0	4
Aslandmea la sondare						5	3	5		6	2	3					

### Vestibular




### Palatinal

[illegible]

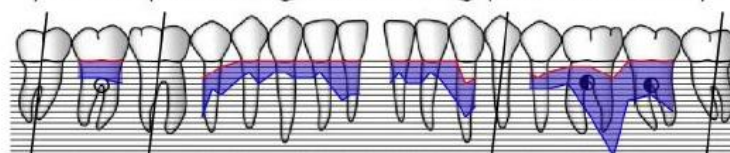
Val. med. a adâncimii la sondare = 3.9 mm Val. med. a nivel. de atasament = -4.4 mm 44 % Placă 39 % Sângerare la sondare

[illegible]

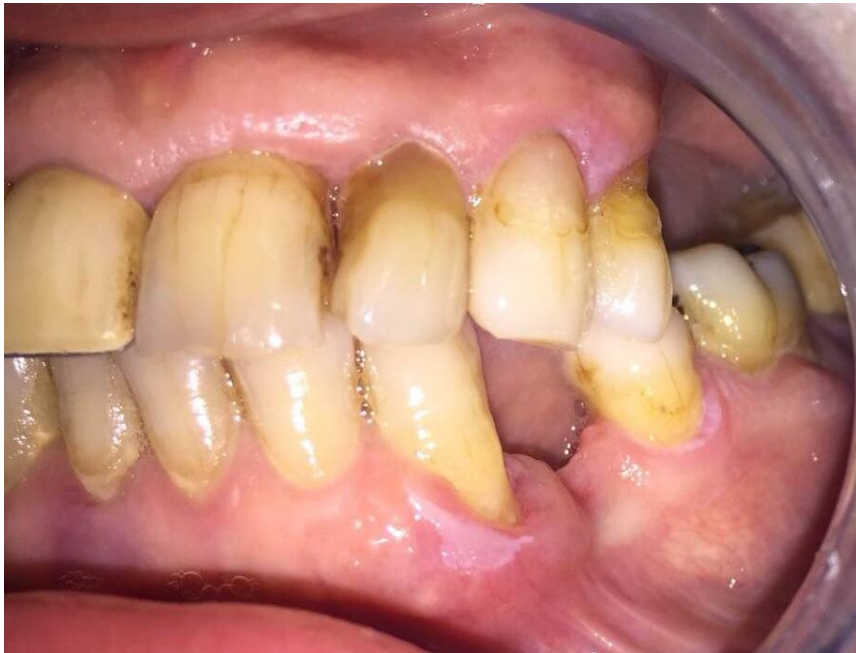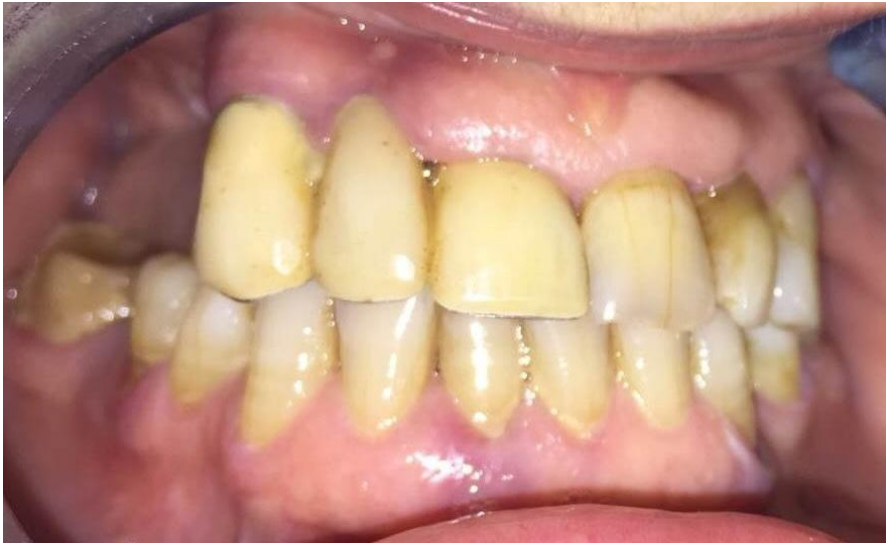**Lingual**



### Vestibular

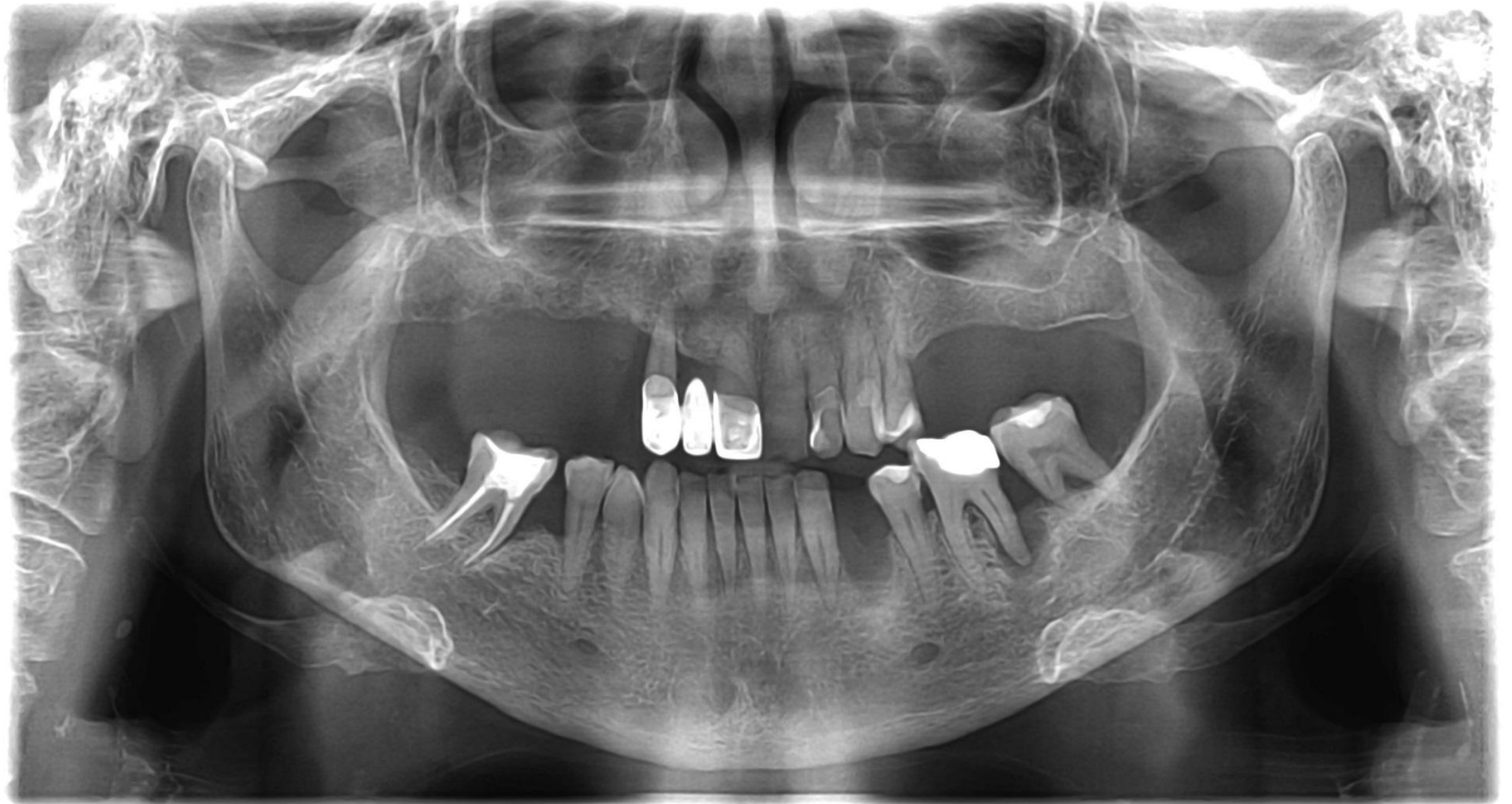[illegible]





Dinte	Clasif. Cairo	Clasif. Miller	REC depth (mm)	KTW (mm)	CEJ (A/B)	Step (+/-)
21 V	RT3	cl. a III-a	2	4	A	-
22 V	RT3	cl. a III-a	2	3	B	-
O	RT3	cl. a III-a	2		A	-
23 O	RT1	cl. I	1		A	-
24 V	RT2	cl. a III-a	4	2	B	+
O	RT3	cl. a III-a			A	-
36 V	RT3	cl. a III-a	2	3	A	-
35 V	RT2	cl. a III-a	1	2	A	-
33 V	RT3	cl. a III-a	4	2	A	-
32 O	RT1	cl. I	4	3	A	-
31 O	RT1	cl. I	1	3	A	-
41 O	RT1	cl. I	2	3	A	-
42 O	RT1	cl. I	1	3	A	-
43 O	RT1	cl. I	1	2	A	-
44 O	RT1	cl. I	1	2	A	-
45 V	RT3	cl. a III-a	2	1	A	-
O	RT3	cl. a III-a	1		A	-

# EXAMENE PARACLINICE: Examenul radiografic



PaX-i3D

R

# DIAGNOSTICUL PARODONTAL

Parodontita cronica generalizata severa

Stadiu 4: PD  $\geq$  6 mm

rezorbtie osoasa verticala  $\geq$  3 mm

afectarea furcatiei grad 3 – 3.7.

necesitatea reabilitarii complexe: disfunctie masticatorie, < 10 perechi dinti antagonisti

Grad B – dovezi indirecte: % bone loss/ age = 0.9

distructie proportionala cu cantitatea de PB

Factor de risc: fumatul

3.6. – leziune endoparodontala fara afectarea integritatii radiculare

la un pacient parodontopat

grad 3: pungi parodontale profunde pe > 1 suprafata dentara (V si D)

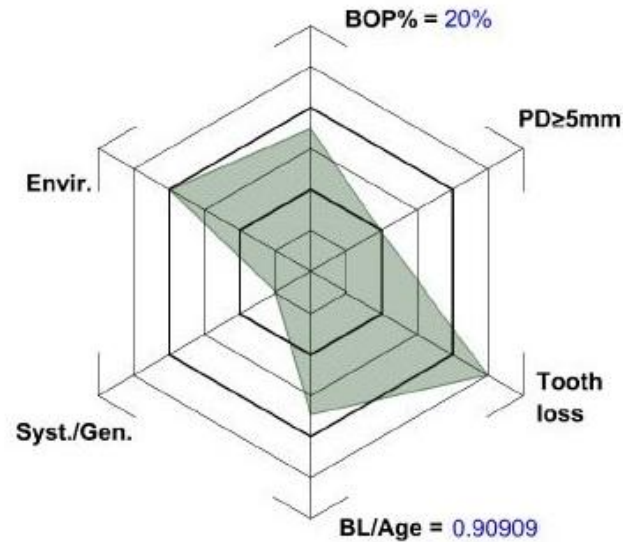


# PROGNOSTICUL

## Department of Periodontology Periodontal Risk Assessment

Patient Last Name

Date **05.06.2018**



Polygon surface: 66.6839

Periodontal Risk: **medium**

Suggested Recall interval: **6** Months

Age	<input type="text" value="55"/>
Number of teeth and implants	<input type="text" value="16"/> (1 - 32)
Number of sites per tooth / implant	<input type="radio"/> 2 <input type="radio"/> 4 <input checked="" type="radio"/> 6
Number of BOP-pos. sites	<input type="text" value="19"/> of <b>96</b>
Number of sites with PPD ≥ 5mm	<input type="text" value="4"/>
Number of missing teeth	<input type="text" value="16"/>
% Alveolar bone loss (estimated in % or 10% per 1mm)	<input type="text" value="50"/> %
Syst./Gen.	<input type="radio"/> Yes <input checked="" type="radio"/> No
Envir.	<input type="radio"/> Non smoker (NS) <input type="radio"/> Former smoker (FS) <input type="radio"/> Occasional smoker (OS) <input checked="" type="radio"/> Smoker (S) <input type="radio"/> Heavy smoker (HS)

# INDICATII DE TRATAMENT

- **Terapia initiala**

ablatie RPF 13-11

tratament endodontic 36 si amputatia radacinii D

FMD

- **Terapia corectoare**

☐ Open flap debridement + ENAP + C.O.R.

37 tunelizare pt. expunerea furcatiei.

- Cadran I si II

- Cadran III

- Cadran IV

☐ LRA 13-24 + ENAP

LRA 33-45, open flap debridement pe lingual si pt. 35, 36, 37 si 47 + C.O.R.

Open flap debridement si regenerare parodontala pt. defecte osoase verticale:

21 D, 22 M, 33 M, 41 M si D, 45 D, 47 M

Lambou cu prezervare papilara si regenerare parodontala

Recesii – nu se indica tratament chirurgical

Terapie corectoare protetice:

Maxilar: protezare hibrida PPF 13-24 MC + PPS

Mandibula: PPF 33, 35, 36, 37

- **Terapia de mentinere**

Recall la 6 luni

Recare: igienizare profesionala + OHI, chiuretajul pungilor parodontale reziduale